

## New Approach for Portal Vein Thrombosis Management with Endovascular Procedure during Orthotopic Liver Transplantation

**Renato Ferreira da Silva<sup>1,2</sup>, Luciano Beltrão Pereira<sup>1,2\*</sup>, Paulo Cesar Arroyo Junior<sup>1,2</sup>, William José Duca<sup>1,2</sup>, Francisco Ricardo Marques Lobo<sup>1,3</sup>, Livia Pereira Miranda Prado<sup>1,3</sup>, André Rodrigo Miquelin<sup>1,4</sup>, Daniel Gustavo Miquelin<sup>1,4</sup>, Luis Fernando Reis<sup>1,4</sup> and Rita de Cássia Martins Alves da Silva<sup>1,2</sup>**

<sup>1</sup>Faculty of Medicine of São José do Rio Preto (FAMERP), São José do Rio Preto, São Paulo, Brazil

<sup>2</sup>Department of Liver, Pancreas and Intestine Transplant, Hospital de Base, São José do Rio Preto, São Paulo, Brazil

<sup>3</sup>Department of Anesthesiology, Hospital de Base, São José do Rio Preto, São Paulo, Brazil

<sup>4</sup>Department of Endovascular and Vascular Surgery, Hospital de Base, São José do Rio Preto, São Paulo, Brazil

\*Corresponding author: Luciano Beltrão Pereira, GI and General Surgeon, Faculty of Medicine of São José do Rio Preto (FAMERP), São José do Rio Preto, São Paulo, Brazil, E-mail: [lpereiras@hotmail.com](mailto:lpereiras@hotmail.com)

Received date: 22 Sep 2017; Accepted date: 01 Dec 2017; Published date: 06 Dec 2017.

Citation: da Silva RF, Pereira LB, Arroyo PC Jr, Duca WJ, Miquelin DG, et al. (2017) New Approach for Portal Vein Thrombosis Management with Endovascular Procedure during Orthotopic Liver Transplantation. *J Transplant Res* 2(1): doi <http://dx.doi.org/10.16966/2473-1730.114>

Copyright: © 2017 da Silva RF, et al. This is an open-access article distributed under the terms of the Creative Commons Attribution License, which permits unrestricted use, distribution, and reproduction in any medium, provided the original author and source are credited.

### Abstract

Portal vein thrombosis (PVT) is present in around 10% of transplant candidates, but its conduct still remains a challenge in liver transplantation (LT). Therefore we present an innovative and less invasive option for PVT management, exemplified through an endovascular procedure realized in a patient with Yerdel type III PVT and splenorenal shunt during an orthotopic liver transplantation (OLT).

**Keywords:** Portal Vein Thrombosis; Endovascular Procedure; Orthotopic Liver Transplantation

**Abbreviations:** LT-Liver Transplantation; MELD-Model for End-stage Liver Disease score; OLT-Orthotopic Liver Transplantation; PVT-Portal Vein Thrombosis.

### Introduction

Portal vein thrombosis (PVT) management still remains a challenge in liver transplantation (LT), and until recently it was a formal impairment for LT. When associated with splenorenal shunt it turns the transplant into a more complicated procedure considering the technical complexity [1,2]. Many surgical techniques have been proposed, such as thrombectomy, splenectomy, renal vein ligation, left gastric vein anastomosis, shunt ligation and more complex procedures like hemitransposition and even multi-visceral transplantation depending on the grade of thrombosis [1,2,3].

We present a case report of a liver transplant patient with both PVT and splenorenal shunt that was managed successfully with an intra-operative endovascular procedure.

### Case report

A 57 year old male patient presented with alcoholic cirrhosis, overt frequent encephalopathy, and splenorenal shunt. The Child-Turcotte-Pugh score was 8 (grade B) and the model for end-stage liver disease score (MELD) score was 13. The patient underwent orthotopic liver transplantation (OLT) with MELD exception condition due to encephalopathy. During surgery, a type III (Yerdel-table 1) PVT was identified and a partial thrombectomy was performed [4]. After the portal vein construction, we observed a weak flow. Ligation of the splenorenal shunt was realized and a deficient reperfusion persisted. The superior mesenteric vein was dissected and a stent was inserted into the portal vein by the endovascular team. The figure below shows portal vein hypoplasia (Figure 1a), the balloonization procedure (Figure 1b) and the metallic stent insertion, which led to an adequate liver reperfusion (Figure 1c).

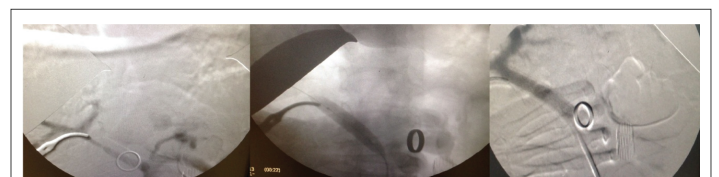
Patient recovery progressed well and after 8 days the patient was discharged with medication and antiplatelet aggregation therapy with follow-up in the outpatient clinic. A computed tomography control 3 months after transplant, confirmed a good flow and patency of the stent and portal vein.

### Discussion and Conclusion

After extent search through Pubmed, the conclusion was that this exact procedure at the moment of the orthotopic liver transplantation (OLT) was not found to have been realized. Therefore, this strategy is a

**Table 1:** Portal vein thrombosis classification (Yerdel) [4]

	Extension	Obstruction of the superior mesenteric vein
Grade I	<50%	± minimal obstruction
Grade II	50-100%	± minimal obstruction
Grade III	100%	Proximal
Grade IV	100%	Distal



**Figure 1:** (a). Portal vein hypoplasia, (b). Balonization procedure, (c). Portal vein metallic stent.

breakthrough in the area and can become a new path to treat low portal vein flow due to hypoplasia combined with portal vein thrombosis and a splenorenal shunt during orthotopic liver transplantation (OLT).

## References

1. Golse N, Bucur PO, Faitot F, Bekheit M, Pittau G, et al. (2015) Spontaneous Splenorenal Shunt in Liver Transplantation: Results of Left Renal Vein Ligation Versus Renoportals Anastomosis. *Transplantation* 99: 2576-2585.
2. Teixeira UF, Machry MC, Goldoni MB, Kruse C, Diedrich JA, et al. (2016) Use of Left Gastric Vein as an Alternative for Portal Flow Reconstruction in Liver Transplantation. *Case Rep Surg* 2016: 8289045.
3. Tzakis AG, Kato T, Levi DM, Defaria W, Selvaggi G, et al. (2005) 100 Multivisceral transplants at a single center. *Ann Surg* 242: 480-493.
4. Yerdel MA, Gunson B, Mirza D, Karayalçin K, Olliff S, et al. (2000) Portal vein thrombosis in adults undergoing liver transplantation: risk factors, screening, management, and outcome. *Transplantation* 69: 1873-1881.