

An Ultrasound-Assisted Approach to an Early Detection of Complications of an Implant-Based Augmentation Mammoplasty using the BellaGel® SmoothFine: Preliminary 3-year Clinical Experience

Keun Yeong Song¹, Jung Youp Sung², Woo Sik Choi³, Hyung Guhn Lim⁴ and Jae Hong Kim^{5,*}

¹Department of Breast Surgery, Gwangju Suwan Hospital, Gwangju, Korea

²BBC Plastic Surgery Clinic, Changwon, Korea

³Lamar Clinic, Ulsan, Korea

⁴Department of Radiology, Gwangju Suwan Hospital, Gwangju, Korea

⁵Korean Society of Breast Implant Research, The W Clinic, Seoul, Korea

*Corresponding author: Jae Hong Kim, Korean Society of Breast Implant Research, The W Clinic, 9F Kukdong B/D, 596 Gangnam-daero, Gangnam-gu, Seoul 06626, Korea, Tel: +82-2-517-7617; E-mail: stenka@hanmail.net

Received: 05 Jan, 2021 | Accepted: 22 Feb, 2021 | Published: 26 Feb, 2021

Citation: Song KY, Sung JY, Choi WS, Lim HG, Kim JH (2021) An Ultrasound-Assisted Approach to an Early Detection of Complications of an Implant-Based Augmentation Mammoplasty using the BellaGel® SmoothFine: Preliminary 3-year Clinical Experience. *J Surg Open Access* 7(2): [dx.doi.org/10.16966/2470-0991.232](https://doi.org/10.16966/2470-0991.232)

Copyright: © 2021 Song KY, et al. This is an open-access article distributed under the terms of the Creative Commons Attribution License, which permits unrestricted use, distribution, and reproduction in any medium, provided the original author and source are credited.

Abstract

Background: Selection of optimal types of breast implants is an essential factor that determines the degree of patients' satisfaction with outcomes of augmentation mammoplasty, for which an evidence-based approach to it is mandatory. Several studies have supported the safety of the BellaGel® SmoothFine (HansBiomed Co. Ltd., Seoul, Korea), a silicone gel-filled breast implant from a Korean manufacturer. But such studies have been conducted in a manufacturer-sponsored setting. We therefore conducted this non-manufacturer-sponsored, retrospective study to assess its 3-year safety outcomes in Korean women.

Methods: We performed a retrospective review of medical records in a total of 251 women with a mean age of 31.88 ± 6.83 years old; they received an implant-based augmentation mammoplasty using the BellaGel® SmoothFine. They had been evaluated for incidences of postoperative complications and estimated time-to-events (TTEs).

Results: A total of 48 cases (19.1%) of postoperative complications occurred; these include 22 cases (8.8%) of CC, 8 cases (3.2%) of dissatisfaction with shape, 7 cases (2.8%) of sliding/foreign body sensation, 4 cases (1.6%) of early seroma, 3 cases (1.2%) of early hematoma, 3 cases (1.2%) of infection and 1 case (0.4%) of wound dehiscence. TTEs were estimated at 331.35 ± 12.83 days (95% CI 306.09-356.62).

Conclusions: Here, we describe 3-year treatment outcomes and safety of an implant-based augmentation mammoplasty using the BellaGel® SmoothFine in Korean women. It would be mandatory, however, to perform a meticulous long-term follow-up of patients receiving the BellaGel® SmoothFine and then to consider the possibility that they might be vulnerable to its possible detrimental effects.

Keywords: Safety; Postoperative complications; Implant capsular contracture; Edema; Seroma

Introduction

It is of no doubt that assessment of outcomes of an implant-based augmentation mammoplasty from surgeons' perspectives would be inevitable. On the other hand, however, its aesthetic outcomes and safety profile should also be evaluated from patients' perspectives. This is not only because they are closely associated with patients' health-related quality of life, psychosocial and sexual well-being and satisfaction with aesthetic appearance of the breast but also because a patient-oriented evaluation of them has become a critical metric for the quality of treatment in a consumer-driven healthcare environment [1-6].

Selection of optimal types of breast implants is an essential factor that determines the degree of patients' satisfaction with outcomes of augmentation mammoplasty, for which an evidence-based approach to it is mandatory [7-9].

To date, attempts have been made to preoperatively select breast implants based on anthropometric measurements, such as the width, height and projection of the breast, for the purposes of achieving symmetry of the shape and volume [10-12]. From this context, the BellaGel® (HansBiomed Co. Ltd., Seoul, Korea) is known as a silicone gel-filled breast implant that best fits to Korean women [13]. Its

short-term safety has been well described in the literature, which is in agreement with 4- and 6-year interim results of a 10-year prospective cohort study [13-16]. The BellaGel® SmoothFine is the BellaGel® implant with a microtextured surface; it is equipped with softness as well as a refined, smooth surface with a roughness of 5.96 µm, which is a different feature from traditional smooth surface, according to the International Organization for Standardization (ISO) 14607 Annex H Test for surface characteristics (Figure 1). According to the manufacturer, it is advantageous in lowering the rate of capsular contracture (CC) and providing more softness. This might be closely associated with the surface interaction that can decrease macrophage activities and enhance the elasticity of the gel [17].

Of note, the safety profile of the BellaGel® SmoothFine has been shown to be non-inferior to that of its competitors [18-20]. But these reports are from manufacturer-sponsored studies.

A recent article revealed that a Korean manufacturer of a silicone gel-filled breast implant, the BellaGel® SmoothFine (HansBiomed Co. Ltd., Seoul, Korea), committed a medical device fraud in violation of the regulatory requirement enforced by the Korean Ministry of Food and Drug Safety (KMFDS) [21]. Interestingly, the BellaGel® SmoothFine has been described as a competitor of the Motiva Ergonomix™ (Establishment Labs Holdings Inc., Alajuela, Costa Rica); its superiority or non-inferiority to other brands of a silicone gel-filled breast implant have been reported in manufacturer-sponsored studies [18-20,22].

The manufacturer's violation of the regulatory requirement should be considered serious not only because the BellaGel® SmoothFine is one of the most popular brands of a microtextured device in Korea but also because it has been exported to over 30 countries worldwide as a CE-certified device [21].

Given the above background, we conducted this non-manufacturer-sponsored, retrospective study to assess 3-year safety outcomes of an implant-based augmentation mammoplasty using the BellaGel® SmoothFine in Korean women.

Methods

Study patients and setting

We evaluated the patients receiving an implant-based augmentation mammoplasty at our hospitals between September 26, 2017 and August 31, 2020. We included women aged 22 years or older, those with an adequate amount of tissue for coverage of the breast implant and those with availability of follow-up data. But we excluded women with unilateral or bilateral presence of pre-malignant breast lesions, those with mutations in breast cancer genes 1 or 2 (BRCA1 or BRCA2), those with a past history of taking bilateral mastectomy, those with untreated

malignancies, those with a past history of sustaining a radiation-induced damage, those with vascular compromise or impaired wound healing, those with abscess or infection, those with a past history of taking any drugs that may interfere with blood clotting or raise risks of developing postoperative complications, those with underlying medical conditions that may raise risks of developing postoperative complications (e.g., obesity, diabetes mellitus, autoimmune disease, chronic lung, severe cardiovascular disease connective tissue or rheumatoid disease), those who are pregnant or breastfeeding, those with medical conditions that may interfere with wound healing (e.g., active infectious collagen disease, those with active fever (body temperature >38°C), those with severe lung disease (e.g., chronic obstructive pulmonary disease), those with cystic fibrosis, those with active cutaneous or systemic infections, those receiving radiotherapy or chemotherapy within 6 months preoperatively and those lost to follow-up.

We therefore evaluated a total of 287 women (n=287) in the current study; it was conducted in compliance with the relevant ethics guidelines. But informed consent was waived due to its retrospective nature.

Evidence-based approach to an implant-based augmentation mammoplasty and a multi-disciplinary, algorithm-based one to an early detection of postoperative complications

We perform an implant-based augmentation mammoplasty in a step-by-step manner, followed by a multi-disciplinary, algorithm-based approach to an early detection of postoperative complications.

Preoperative simulation of postoperative outcomes: Preoperatively, we use the Divina™ 3-dimensional Scanner (Establishment Labs Holdings Inc., Alajuela, Costa Rica) to allow the patients to view possible results of an implant-based augmentation mammoplasty. It not only helps a surgeon obtain anthropometric measurements of the breast, such as breast base width, breast base height, distance from the sternal notch to the nipple, distance from the nipple to the midline, distance from the nipple to the inframammary fold, areolar diameter, internipple distance, intermammary distance and breast volume, but also visualizes its preoperative characteristics. Thus, it stimulates possible results through an analysis of data and information about diverse types of a silicone gel-filled breast implant for the purposes of helping patient select optimal types of a breast implant and thereby yielding satisfactory outcomes (Figure 2).

Surgical procedures: Our surgical procedures are performed in compliance with the American Society of Plastic Surgery (ASPS) recommendations.

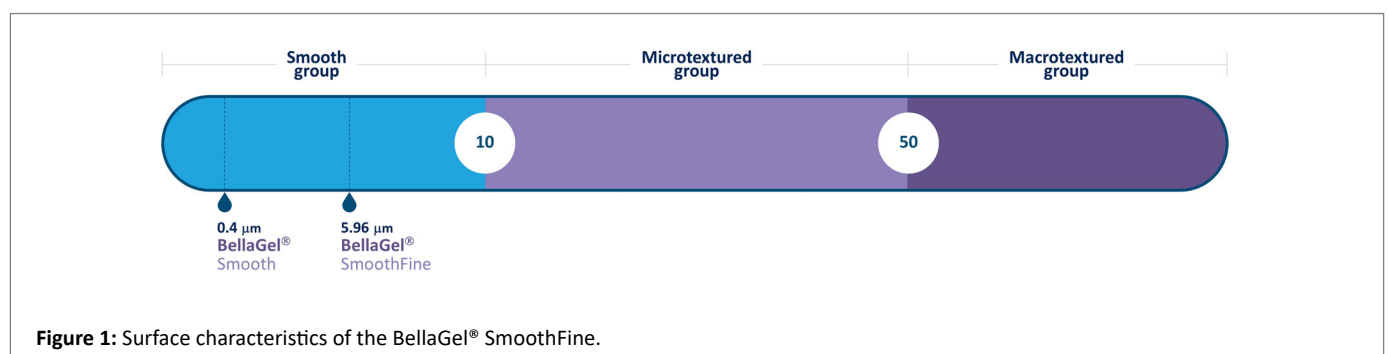


Figure 1: Surface characteristics of the BellaGel® SmoothFine.

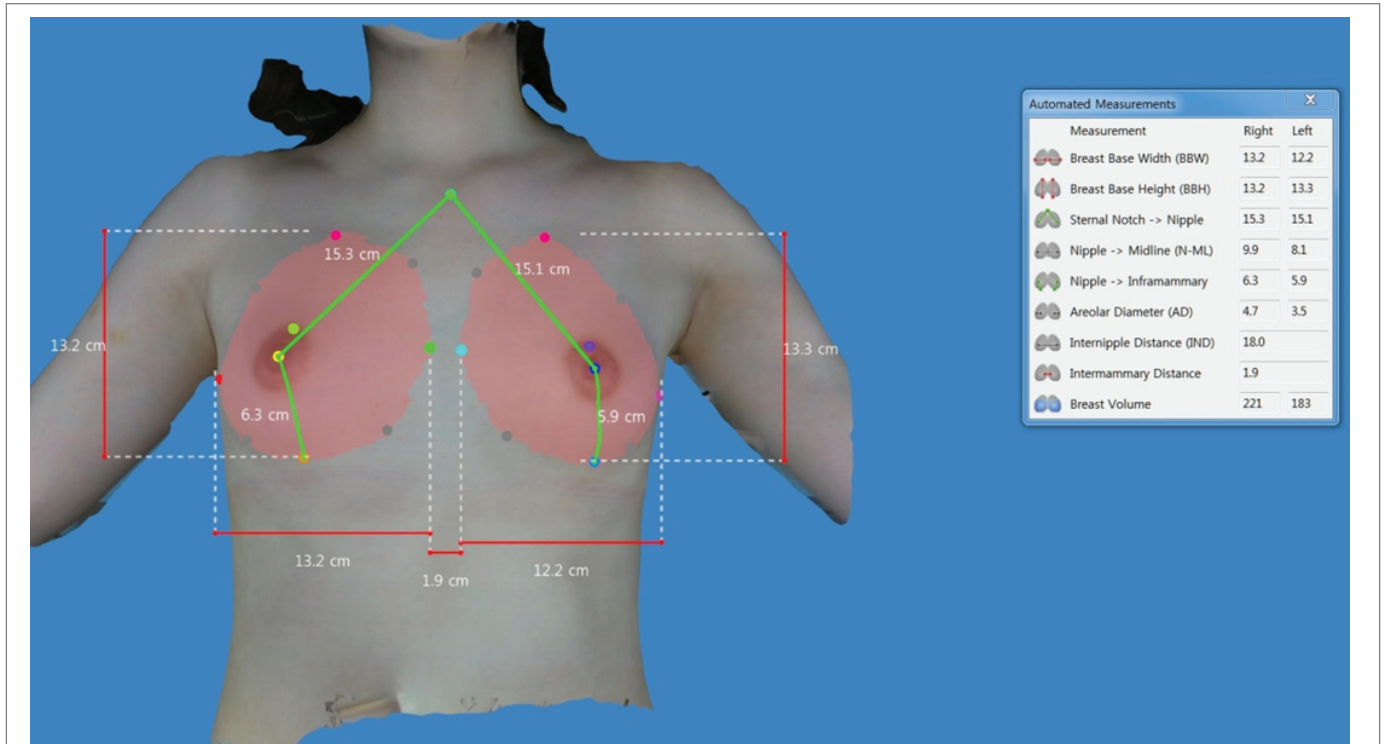


Figure 2: Preoperative simulation of postoperative outcomes using the Divina™ 3-D Scanner.

Anthropometric measurements are preoperatively obtained; these include breast base width, breast base height, distance from the sternal notch to the nipple, distance from the nipple to the midline, distance from the nipple to the inframammary fold and breast volume.

Peri-areolar, inframammary fold (IMF) and trans-axillary incisions were made under general anesthesia and intravenous sedation for the purposes of preventing visible scarring. Selection of surgical incision is based on our desired outcomes, types of breast implants, the degree of augmentation, the anatomical characteristics of patients and patient-surgeon preference. Based on the Ranquist formula, we determined the distance extending from the nipple to the IMF, the size of breast implant and the scope of dissection. After the dissection, each breast was irrigated using a 100 cc of normal saline mixed with H₂O₂ solution at a ratio of 1:1, followed by the use of betadine 100 cc. Then, a breast implant was immersed in a normal saline mixed with ceftazole 1 vial and gentamycin 1 ample and then inserted in a pocket either under the pectoralis muscle (a submuscular placement) or in the retromammary space above the pectoralis major muscle (a subglandular/submammary placement). Methods for inserting and positioning a breast implant in the pocket were dependent on its types, the degree of augmentation, characteristics of a patient's body and our recommendations. Thus, we performed a dual-plane I/II augmentation on a case-by-case basis. Intraoperatively, the patients were intravenously given ceftazole 1.0 gr. Incisions were closed using layered sutures in the breast tissue. In addition, skin adhesive or surgical tape was used to close the skin [13,23].

Sonographic measurement of capsule thickness: To make an accurate diagnosis of CC, we measure the capsule thickness at 3 months postoperatively in the patients who are suspected of having CC (Figure 3). Moreover, we consider an empirical correlation between the Baker grading system and the capsule thickness on breast ultrasound (Table 1). If necessary, we perform capsulectomy and thereby collect tissue samples to make an accurate diagnosis of complications (Figure 4).

Planning of revision surgery based on sonographic findings:

We immediately plan for revision surgery considering the capsule thickness and whether the patients present with any notable signs and symptoms when they had an increase in it on breast ultrasound at 3 months postoperatively. If necessary, we frequently perform a follow-up of the corresponding patients to examine whether they present with changes in the capsule thickness and symptoms. Thus, we determine whether they required revision surgery.

Sonographic measurement of the thickness of dermis, subcutaneous tissue and pectoralis major muscle: To examine whether the patients present with swelling after an implant-based augmentation mammoplasty, we measure the thickness of dermis, subcutaneous tissue and pectoralis major on breast ultrasound preoperatively and at 1 and 3 months postoperatively (Figure 5).

Patient evaluation and criteria

We evaluated our clinical series of the patients, as previously described. We also analyzed survival of the BellaGel® SmoothFine according to our previous published studies [13,23].

Statistical analysis

Values were expressed as the number of patients or cases with percentage, Mean ± SD (SD: standard deviation) or Mean ± SE (SE: standard error), where appropriate. The cumulative complication-free survival was estimated, for which 95% confidence intervals (CIs) were provided, followed by the log-rank test. Moreover, the corresponding cumulative complication-free Kaplan-Meier survival and hazards were plotted as a curve. A P-value of <0.05 was considered statistically significant.

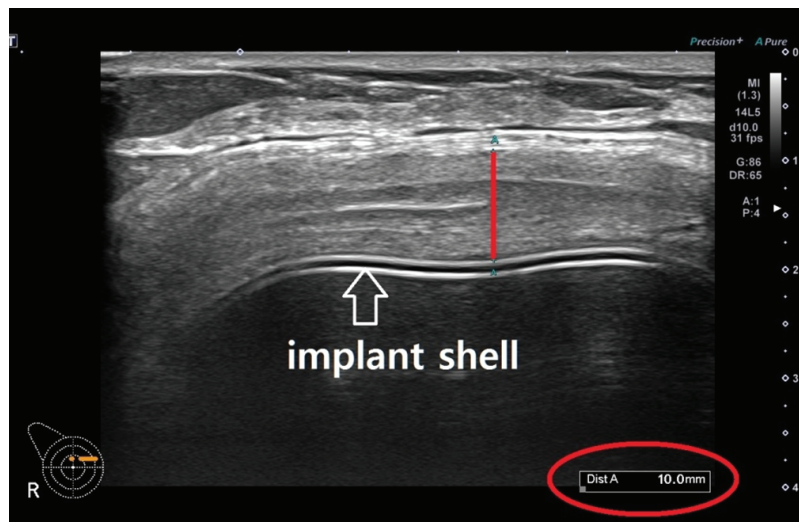


Figure 3: Sonographic measurement of capsule thickness.

Normal breast is characterized by the attachment of the inferior margin of pectoralis major muscle to the implant shell. A capsule thickness of <0.4 mm cannot be measured. A capsule thickness of >0.4 mm is observed as a hypoechoic line between the pectoralis major and implant shell on breast ultrasound. Its thickness can therefore be measured as that of the hypoechoic line.

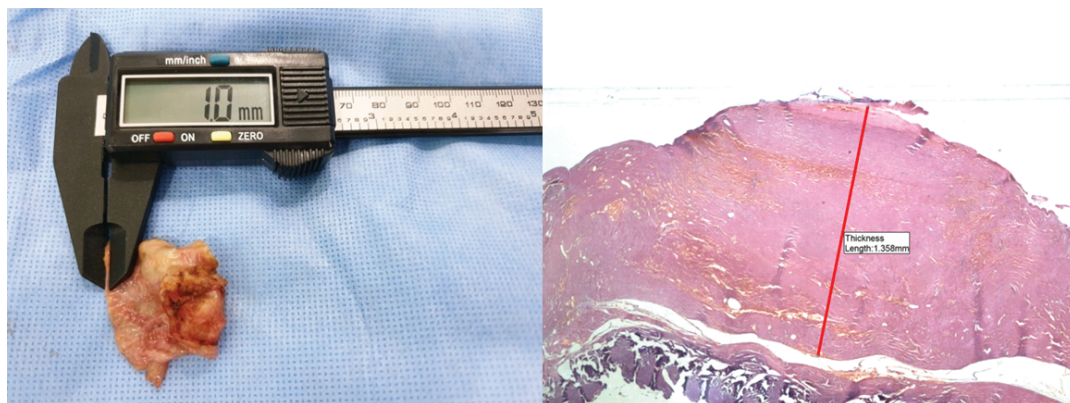


Figure 4: Microscopic measurement of capsule thickness on tissue samples.

(A) The thickness of the entire capsule is measured using an electronic ruler, which is followed by comparison of it with that visualized on breast ultrasound. Thus, almost lack of a difference in the capsule thickness between the two methods is confirmed. (B) A histopathologic examination is performed a stereomicroscope (Olympus SZ61; Olympus Optical Co., Tokyo, Japan), and its findings are photographed using the TUCSEN H series digital camera (Fuzhou Tucsen Photonics Co., Fuzhou, Fujian, China) (hematoxylin & eosin, 40x).

Table 1: Correlation between the Baker grading system and the capsule thickness on breast ultrasound.

Baker grade	The capsule thickness on breast ultrasound
I	<0.4 mm
II	0.4-0.8 mm
III	0.8-1.4 mm
IV	>1.4 mm

Results

Baseline characteristics of the patients

Excluding 37 patients, we included a total of 251 women (n=251) in the current study. Their mean age was 31.88 ± 6.83 (20-58) years old. They were followed up during a mean period of $336.51 \pm$

202.54 (63-911) days. Their baseline characteristics are represented in table 2.

Safety outcomes

A total of 48 cases (19.1%) of postoperative complications occurred; these include 22 cases (8.8%) of CC, 8 cases (3.2%) of dissatisfaction with shape, 7 cases (2.8%) of sliding/foreign body sensation, 4 cases (1.6%) of early seroma, 3 cases (1.2%) of early hematoma, 3 cases (1.2%) of infection and 1 case (0.4%) of wound dehiscence (Table 3).

In our series, Time-to-Events (TTEs) were estimated at 331.35 ± 12.83 days (95% CI 306.09-356.62) (Table 4). Moreover, cumulative complication-free survival is represented in Table 5. The corresponding Kaplan-Meier cumulative survival and hazards were plotted as a curve (Figures 6 and 7).

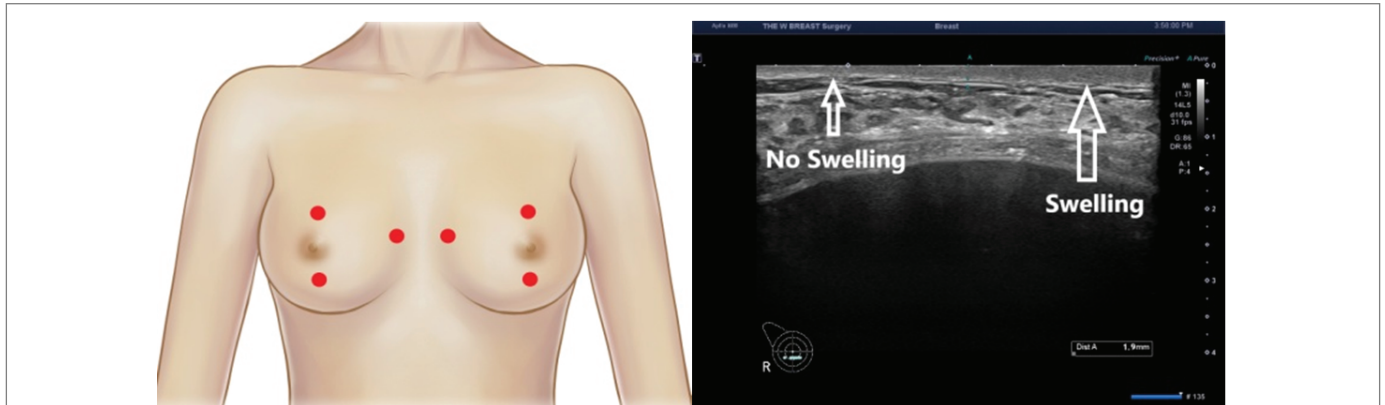


Figure 5: Sonographic measurement of the thickness of dermis, subcutaneous tissue and pectoralis major muscle.

(A) Red dots indicate landmarks for the measurement of the thickness of dermis, subcutaneous tissue and pectoralis major muscle; these include locations 2 cm superior to the upper margin of the areola, 2 cm inferior to the lower margin of the areola and 1 cm medial to the sternal border. (B) On breast ultrasound, there is an increase in the thickness of dermis in a patient presenting with postoperative swelling.

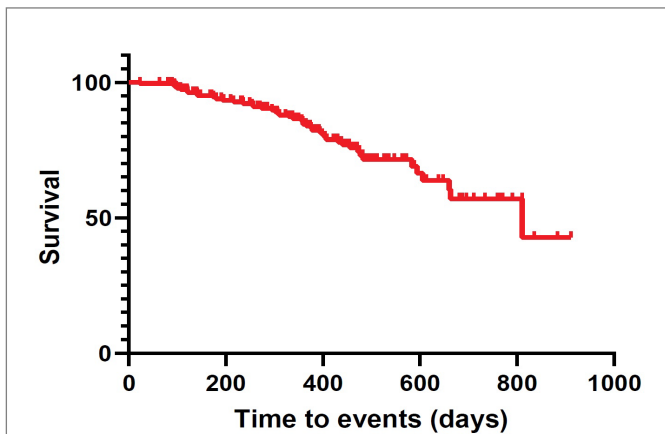


Figure 6: Kaplan-Meier cumulative survival.

In our series, time-to-events were estimated at 331.35 ± 12.83 days (95% CI 306.09-356.62).

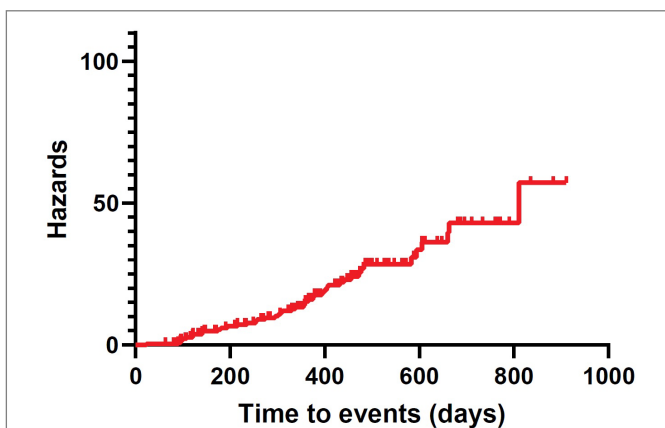


Figure 7: Kaplan-Meier cumulative hazards.

Case presentations

Representative cases are presented in Figures 8 and 9.

Discussion

In an effort to obtain predictable and stable outcomes of an implant-based augmentation mammoplasty, a detailed preoperative assessment is a mandatory procedure. This requires selection of appropriate patients and devices [24]. In more detail, optimal breast implants should be selected considering both their shape and volume and variations in the morphological characteristics of the breast, which is within the scope of well-established, evidence-based protocols [12,25,26]. From this context, preoperative planning for an implant-based augmentation mammoplasty provides useful information about volume and shape of a device through an individualized application of a 3-D imaging modality [27]. Thus, a 3-D imaging modality is more advantageous in quantifying differences in anthropometric variables, such as the shape, dimension and volume of the breast, between preoperatively and postoperatively as compared with a 2-D photography or physical examination [12,28]. This enables a surgeon to simulate possible postoperative appearance of the implant placed in a patient's body. The resulting improved communication between the two parties would raise the degree of patient satisfaction with outcomes of an implant-based augmentation mammoplasty [27].

Capsules around the breast implant are characterized by the presence of specialized fibroblasts which are capable of contracting themselves, thus termed as contractile fibroblasts, and then presumed to be responsible for CC [29,30]. These contractile fibroblasts, or myofibroblasts, were first described in wound granulation tissue and their involvement in wound contraction has also been described [31,32]. It is also known that they disappear with wound healing, but their persistent presence in abnormal scars, such as hypertrophic scar and keloid. They are also found in such conditions as fibrosis, such as Dupuytren's contracture and desmoid tumor [33,34]. Moreover, they play a role in forming the fibrous stroma in response to epithelial and lymphatic malignancy [35-37].

The myofibroblasts in an implant capsule are histopathologically characterized by parallel arrangement of fibrillar bundles of 4-8 nm in diameter to their axis, nuclear deformations composed of folding

Table 2: Baseline characteristics of the patients (n=251).

Variables	Values
Age (years old)	31.88 ± 6.83 (20-58)
Sex (male-to-female ratio)	0:251
Height (cm)	162.38 ± 5.00 (148-176)
Weight (kg)	50.92 ± 5.39 (40-70)
BMI (kg/m ²)	19.29 ± 1.71 (15.62-24.80)
FU period (days)	336.51 ± 202.54 (63-911)
Purpose of surgery	
Aesthetic	
Left breast	248 (98.8%)
Right breast	249 (99.2%)
Reconstructive	
Left breast	2 (0.8%)
Right breast	2 (0.8%)
Round of surgery	
Primary	
Left breast	250 (99.6%)
Right breast	251 (100.0%)
Secondary	0 (0.0%)
Type of incision	
Trans-axillary incision	
Left breast	243 (96.8%)
Right breast	243 (96.8%)
IMF incision	
Left breast	4 (1.6%)
Right breast	4 (1.6%)
Peri-areolar incision	
Left breast	0 (0.0%)
Right breast	0 (0.0%)
Others	
Left breast	3 (1.2%)
Right breast	4 (1.6%)
Volume of breast implant	
<245 cc	
Left breast	4 (1.6%)
Right breast	2 (0.8%)
250-295 cc	
Left breast	62 (24.7%)
Right breast	34 (13.5%)
300-345 cc	
Left breast	143 (57.0%)
Right breast	146 (58.2%)
350-395 cc	
Left breast	35 (13.9%)
Right breast	58 (23.1%)
>400 cc	
Left breast	6 (2.4%)
Right breast	10 (4.0%)
Profile of breast implant	
Ultra-high	
Left breast	0 (0.0%)
Right breast	0 (0.0%)
High	
Left breast	234 (93.2%)
Right breast	244 (97.2%)
Medium	
Left breast	16 (6.4%)
Right breast	6 (2.4%)

Low	
Left breast	0 (0.0%)
Right breast	0 (0.0%)
Non-applicable	
Left breast	1 (0.4%)
Right breast	1 (0.4%)
Pocket	
Subpectoral pocket	251 (100.0%)
Subglandular pocket	0 (0.0%)
Operation time (min)	55.12 ± 13.27

Abbreviations: BMI: body mass index; FU: follow-up; IMF: inframammary fold
Values are mean ± standard deviation or the number of cases with percentage, where appropriate.

Table 3: Postoperative complications.

Variable	Value
Early hematoma	3 (1.2%)
Early seroma	4 (1.6%)
CC	22 (8.8%)
Dissatisfaction with shape	8 (3.2%)
Infection	3 (1.2%)
Sliding/foreign body sensation	7 (2.8%)
Wound dehiscence	1 (0.4%)

Abbreviations: CC, capsular contracture.
Values are the number of the patients with percentage.

Table 4: Overall complication-free survival.

N	n	Censored value	Time-to-events (months)
251	46	206	331.35 ± 12.83 (306.09-356.62)

Note: N: total number of cases; n: incidences of postoperative complications.
Values are mean ± standard error with 95% confidence interval.

of the nuclear membrane, surface differentiation featuring the parallel arrangement of an extracellular layer of fibrils to them and cellular interconnections. This is different from normal fibroblasts and shares some characteristics with smooth muscle cells. Thus, such myofibroblasts are therefore coined based on their structural and functional features; they are equipped with a capability of contracting themselves and applying the force to wound contraction [38,39].

In a large number of literatures, effects on fibroblast differentiation are commonly measured at 3 months [40-44]. This can be seen in the context of effects of leukotriene antagonists on CC. Zafirlukast (Accolate®; AstraZeneca Pharmaceuticals, Wilmington, DE) and montelukast (Singulair®; Merck Sharp & Dohme, Whitehouse Station, NJ) are leukotriene antagonists that are effective in reversing CC following augmentation mammoplasty because of their inhibitory actions on cysteinyl leukotrienes and myofibroblasts, both of which cause CC [45,46].

Application of breast ultrasound to an early detection of its complications is a useful modality. Moreover, a follow-up time point of 3 months postoperatively is minimally necessary to detect the CC. This is plausible from evidence-based perspectives; Reid RR, et al. [47] reported that there were favorable responses to the treatment of early CC with zafirlukast in patients who received an implant-based primary submuscular augmentation mammoplasty. According to these authors, 75.7% of the patients receiving treatment had a complete or

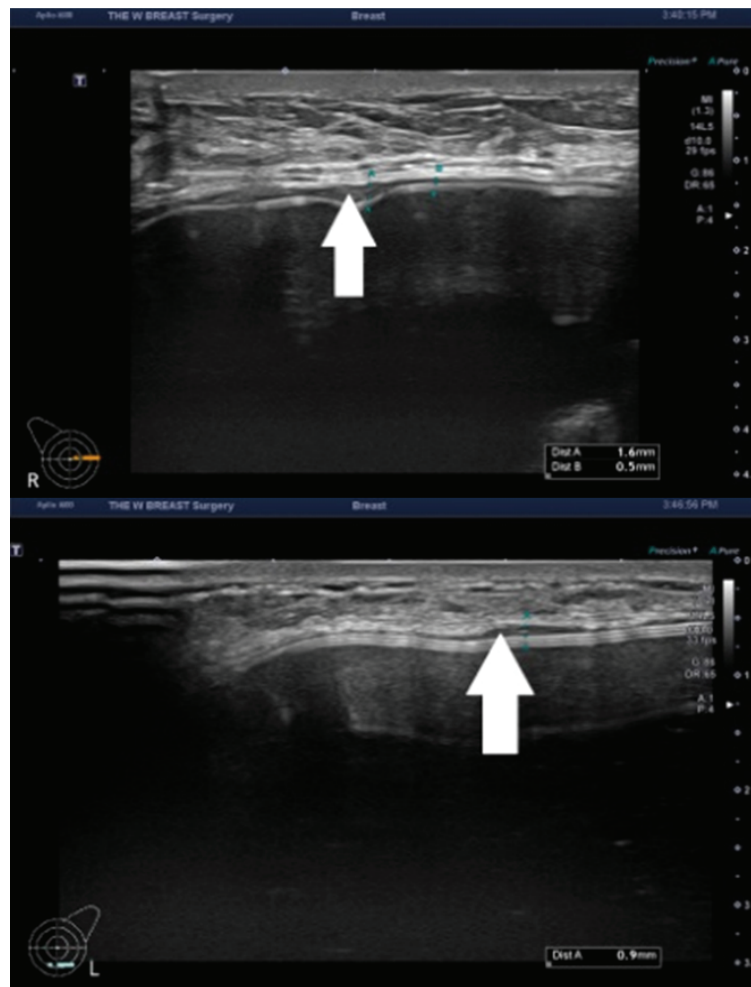


Figure 8: The capsule thickness measured at 3 months postoperatively.

A 48-year-old woman received augmentation mammoplasty using the BellaGel® SmoothFine via a trans-axillary incision in the subpectoral pocket. At 3 months postoperatively, the patient presented with thickened capsule (white arrow) in both breasts; the capsule thickness was measured as 0.3-1.6 mm in the right breast (A) and 0.3-0.9 mm in the left breast (B).

partial response to zafirlukast at 3 months. Therefore, we routinely perform breast ultrasound to examine whether patients receiving a breast implant present with any notable signs and symptoms of complications at 3 months postoperatively.

Women receiving an implant-based augmentation mammoplasty may be at a risk of developing diverse types of early (e.g., formation of seroma and hematoma) and late complications (e.g., CC, gel bleed and rupture). Early complications may eventually lead to extrusion of a device. Late complications are considered an implant failure [48,49]. Of these, seroma formation is definitely recognized as a complication in women whose capsule is left intact. In addition, late seroma is defined as a notable accumulation of serous fluid, such as exudate or effusion, in the capsule seen at least 12 months of an implant-based augmentation mammoplasty [50,51]. It is such a rare entity that its incidence is estimated at approximately 0.88-1.84% [52,53]. Moreover, its relationship with textured implants has been well described in the literature [54]. Its main clinical presentations include a sudden progressive swelling of the breast and discomfort [49].

In the current study, there were a total of 48 cases (19.1%) of postoperative complications. Of these, CC occurred at an incidence of 8.8%. This is noteworthy because manufacturer-sponsored retrospective studies have shown incidences of 0.0% (0/239), 0.6% (1/78) and 1.6% (10/621) in patients receiving the BellaGel® implants including the BellaGel® SmoothFine [14,19,20]. Interestingly, another manufacturer-sponsored experimental study compared the vulnerability to CC based on surface properties between the BellaGel® implants, including the BellaGel® SmoothFine, and the Motiva Ergonomix™ SilkSurface (Establishment Labs Holdings Inc., Alajuela, Costa Rica), thus drawing conclusions that the BellaGel® SmoothFine was the least vulnerable to CC of the sample devices [18]. According to a recent non-manufacturer-sponsored study comparing the 1-year safety between the BellaGel® SmoothFine and the Motiva Ergonomix™, however, CC occurred at incidences of 2.27% (6/264) and 0.00% (0/76), respectively [23]. This strongly indicates not only that result of manufacturer-sponsored studies should be interpreted with caution but also that use of high-resolution ultrasound

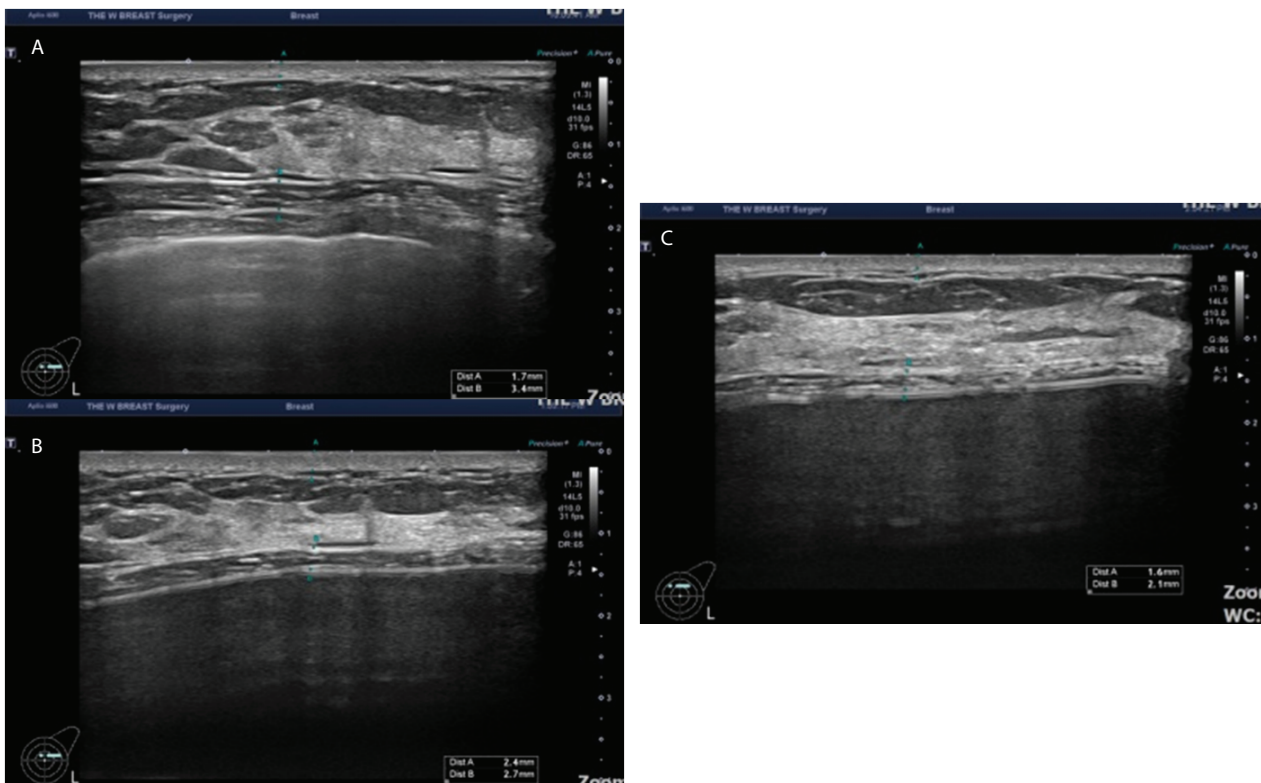


Figure 9: The thickness of the dermis measured preoperatively and at 1 and 3 months postoperatively.

A 28-year-old woman received augmentation mammoplasty using the BellaGel® SmoothFine via a trans-axillary incision in the subpectoral pocket. In this patient, the thickness of the dermis was measured preoperatively and at 1 and 3 months postoperatively. It was measured as 1.7 mm preoperatively (A), 2.4 mm at 1 month (B) and 1.6 mm at 3 months (C).

is an essential tool for accurately detecting complications of an implant-based augmentation mammoplasty at the earliest opportunities possible.

Postoperative swelling after aesthetic and reconstructive implant-based augmentation mammoplasty is not an uncommon entity. Its common causes include hematoma, seroma and infection [52,54-58]. Accumulation of fluid around the breast implant may serve as a cause of complications such as infection, implant extrusion, tissue necrosis, poor wound healing, inhibition of tissue growth into scaffolds and distortion of the size and shape of the implant. It would therefore be mandatory to make a prompt, accurate diagnosis of postoperative swelling; fluid should be collected from the adjacent areas to the breast implant and then cultured, which should be followed by treatment with antibiotics. Moreover, use of specialized diagnostic as well as surgical modalities with needle-guided imaging is currently recommended for the treatment of relevant cases [59]. But there were no cases of postoperative swelling in our series.

A recent manufacturer-sponsored study compared the safety between the breast implants from 6 different manufacturers in Korea; Yoon S and Chang JH compared 1-year safety outcomes between the BellaGel®/BellaGel® SmoothFine (n=182), the Mentor CPG™ (Mentor Worldwide LLC, Santa Barbara, CA) (n=159), the Motiva Ergonomix™ (n=152), the Matrix™ (GC Aesthetics PLC, Apt Cedex, France) (n=135), the Naturgel® (Groupe Sebbin SAS, Boissy-l'Aillierie, France) (n=61) and the Natrelle® 410/510 (Allergan Inc., Irvine, CA) (n=20). These authors reported that the safety of the BellaGel® SmoothFine is

not inferior to its competitors [19]. But this warrants more objective, evidence-based studies. Kim JH previously reported not only that the HansBiomed Co. Ltd., the manufacturer of the BellaGel® SmoothFine, illegally used unapproved substances, such as 7-9700 and Q7-4850, for manufacturing of it but also that the manufacturer deliberately modified its shell structure in violation of the regulatory requirement enforced by the KMFDS [21,22]. It is therefore impossible to completely rule out the possibility that patients receiving the BellaGel® SmoothFine containing hazardous substances or the modified shell structure.

We, at the Korean Society of Breast Implant Research, propose the following recommendations: First, a patient registry should be considered as an infrastructure for the standardized recording of data from patients receiving the BellaGel® implants. In 2019, when we noticed the first report of the Korean case of breast implant-associated anaplastic large cell lymphoma (BIA-ALCL), we proposed that possible impacts of BIA-ALCL be rigorously analyzed and appropriate measures be taken as promptly as possible [60]. From similar contexts, we'll prospectively collect from patients receiving the BellaGel® implants and then track their outcomes and complications, thus endeavoring to ensure both high-quality care and patient safety. This should be accompanied by collaborations between patients receiving the BellaGel® implants and the KMFDS. Second, patients receiving the BellaGel® implants should be meticulously monitored for rupture of the device. Lack of early detection of rupture of a breast implant may cause patients to be vulnerable to silicone-induced axillary lymphadenopathy as well as extracapsular rupture [61,62]. This is

Table 5: Cumulative complication-free survival.

FU	N	n	Survival rate
23	251	1	0.996 ± 0.004 (0.9721-0.9994)
63	250	0	0.996 ± 0.004 (0.9721-0.9994)
80	249	0	0.996 ± 0.004 (0.9721-0.9994)
84	248	0	0.996 ± 0.004 (0.9721-0.9994)
86	247	0	0.996 ± 0.004 (0.9721-0.9994)
87	246	0	0.996 ± 0.004 (0.9721-0.9994)
88	244	0	0.996 ± 0.004 (0.9721-0.9994)
89	242	0	0.996 ± 0.004 (0.9721-0.9994)
90	236	1	0.9918 ± 0.0058 (0.9676-0.9979)
91	231	0	0.9918 ± 0.0058 (0.9676-0.9979)
92	223	0	0.9918 ± 0.0058 (0.9676-0.9979)
93	220	0	0.9918 ± 0.0058 (0.9676-0.9979)
94	219	0	0.9918 ± 0.0058 (0.9676-0.9979)
95	218	1	0.9873 ± 0.0073 (0.961-0.9959)
96	216	1	0.9827 ± 0.0086 (0.9545-0.9935)
97	211	0	0.9827 ± 0.0086 (0.9545-0.9935)
98	204	0	0.9827 ± 0.0086 (0.9545-0.9935)
100	202	1	0.9778 ± 0.0098 (0.9474-0.9907)
101	201	0	0.9778 ± 0.0098 (0.9474-0.9907)
102	200	0	0.9778 ± 0.0098 (0.9474-0.9907)
103	199	0	0.9778 ± 0.0098 (0.9474-0.9907)
105	196	0	0.9778 ± 0.0098 (0.9474-0.9907)
106	193	0	0.9778 ± 0.0098 (0.9474-0.9907)
107	191	0	0.9778 ± 0.0098 (0.9474-0.9907)
108	189	1	0.9778 ± 0.0098 (0.9474-0.9907)
116	187	0	0.9727 ± 0.0111 (0.9399-0.9877)
118	186	0	0.9727 ± 0.0111 (0.9399-0.9877)
119	185	0	0.9727 ± 0.0111 (0.9399-0.9877)
120	183	0	0.9727 ± 0.0111 (0.9399-0.9877)
121	182	1	0.9673 ± 0.0122 (0.9324-0.9843)
122	180	1	0.9619 ± 0.0133 (0.925-0.9809)
132	178	0	0.9619 ± 0.0133 (0.925-0.9809)
133	177	0	0.9619 ± 0.0133 (0.925-0.9809)
140	176	0	0.9619 ± 0.0133 (0.925-0.9809)
141	175	1	0.9564 ± 0.0143 (0.9176-0.9772)
142	173	1	0.9509 ± 0.0152 (0.9103-0.9734)
146	172	0	0.9509 ± 0.0152 (0.9103-0.9734)
148	171	0	0.9509 ± 0.0152 (0.9103-0.9734)
168	170	0	0.9509 ± 0.0152 (0.9103-0.9734)
171	169	0	0.9509 ± 0.0152 (0.9103-0.9734)
174	168	1	0.9452 ± 0.0162 (0.9029-0.9694)
180	167	1	0.9396 ± 0.017 (0.8956-0.9654)
191	166	0	0.9396 ± 0.017 (0.8956-0.9654)
194	165	1	0.9339 ± 0.0179 (0.8884-0.9612)
196	164	0	0.9339 ± 0.0179 (0.8884-0.9612)
210	163	0	0.9339 ± 0.0179 (0.8884-0.9612)
216	161	1	0.9281 ± 0.0187 (0.8811-0.957)
231	159	0	0.9281 ± 0.0187 (0.8811-0.957)
233	158	0	0.9281 ± 0.0187 (0.8811-0.957)
234	157	0	0.9281 ± 0.0187 (0.8811-0.957)
236	156	1	0.9221 ± 0.0195 (0.8737-0.9525)
249	155	0	0.9221 ± 0.0195 (0.8737-0.9525)
254	154	1	0.9162 ± 0.0202 (0.8662-0.948)
257	153	1	0.9102 ± 0.021 (0.8589-0.9434)
266	152	0	0.9102 ± 0.021 (0.8589-0.9434)
270	151	0	0.9102 ± 0.021 (0.8589-0.9434)
274	150	1	0.9041 ± 0.0217 (0.8515-0.9387)
280	149	0	0.9041 ± 0.0217 (0.8515-0.9387)
282	148	0	0.9041 ± 0.0217 (0.8515-0.9387)
284	147	0	0.9041 ± 0.0217 (0.8515-0.9387)
286	146	0	0.9041 ± 0.0217 (0.8515-0.9387)
295	145	1	0.8979 ± 0.0224 (0.8439-0.9339)
302	144	1	0.8916 ± 0.0231 (0.8364-0.929)
306	143	0	0.8916 ± 0.0231 (0.8364-0.929)
307	142	1	0.8854 ± 0.0238 (0.8289-0.924)
311	141	1	0.8791 ± 0.0244 (0.8214-0.919)
323	140	0	0.8791 ± 0.0244 (0.8214-0.919)
330	138	1	0.8727 ± 0.0251 (0.8139-0.9139)
337	135	0	0.8727 ± 0.0251 (0.8139-0.9139)
338	134	1	0.8662 ± 0.0257 (0.8062-0.9087)
343	133	0	0.8662 ± 0.0257 (0.8062-0.9087)
350	132	0	0.8662 ± 0.0257 (0.8062-0.9087)
355	130	1	0.8595 ± 0.0264 (0.7983-0.9033)
357	129	0	0.8595 ± 0.0264 (0.7983-0.9033)
358	128	1	0.8528 ± 0.027 (0.7905-0.8978)
359	127	1	0.8461 ± 0.0276 (0.7826-0.8923)
363	125	0	0.8461 ± 0.0276 (0.7826-0.8923)
364	124	0	0.8461 ± 0.0276 (0.7826-0.8923)
365	122	0	0.8461 ± 0.0276 (0.7826-0.8923)
366	118	1	0.8389 ± 0.0283 (0.7742-0.8865)
367	114	0	0.8389 ± 0.0283 (0.7742-0.8865)
369	112	0	0.8389 ± 0.0283 (0.7742-0.8865)
371	111	0	0.8389 ± 0.0283 (0.7742-0.8865)
372	108	0	0.8389 ± 0.0283 (0.7742-0.8865)
374	107	0	0.8389 ± 0.0283 (0.7742-0.8865)
375	106	1	0.831 ± 0.0291 (0.7647-0.8801)
378	105	1	0.8231 ± 0.0299 (0.7553-0.8737)
379	103	0	0.8231 ± 0.0299 (0.7553-0.8737)
385	102	0	0.8231 ± 0.0299 (0.7553-0.8737)
386	101	0	0.8231 ± 0.0299 (0.7553-0.8737)
388	100	0	0.8231 ± 0.0299 (0.7553-0.8737)
389	99	0	0.8231 ± 0.0299 (0.7553-0.8737)
391	97	0	0.8231 ± 0.0299 (0.7553-0.8737)
392	96	0	0.8231 ± 0.0299 (0.7553-0.8737)
394	95	1	0.8144 ± 0.0308 (0.7448-0.8667)
399	94	1	0.8058 ± 0.0317 (0.7345-0.8597)
404	93	1	0.7971 ± 0.0325 (0.7243-0.8526)
407	92	1	0.7884 ± 0.0333 (0.7141-0.8455)
408	91	0	0.7884 ± 0.0333 (0.7141-0.8455)
422	89	0	0.7884 ± 0.0333 (0.7141-0.8455)
424	88	0	0.7884 ± 0.0333 (0.7141-0.8455)
426	87	0	0.7884 ± 0.0333 (0.7141-0.8455)
430	85	0	0.7884 ± 0.0333 (0.7141-0.8455)
432	84	1	0.7791 ± 0.0342 (0.703-0.8379)
433	83	0	0.7791 ± 0.0342 (0.703-0.8379)
435	81	0	0.7791 ± 0.0342 (0.703-0.8379)
438	80	0	0.7791 ± 0.0342 (0.703-0.8379)
441	79	1	0.7692 ± 0.0351 (0.6913-0.8298)
442	78	0	0.7692 ± 0.0351 (0.6913-0.8298)
447	77	0	0.7692 ± 0.0351 (0.6913-0.8298)
448	76	0	0.7692 ± 0.0351 (0.6913-0.8298)
449	75	0	0.7692 ± 0.0351 (0.6913-0.8298)
450	74	0	0.7692 ± 0.0351 (0.6913-0.8298)
454	73	0	0.7692 ± 0.0351 (0.6913-0.8298)
456	72	1	0.7585 ± 0.0362 (0.6785-0.8212)
457	69	0	0.7585 ± 0.0362 (0.6785-0.8212)
458	68	0	0.7585 ± 0.0362 (0.6785-0.8212)
459	67	0	0.7585 ± 0.0362 (0.6785-0.8212)
461	66	0	0.7585 ± 0.0362 (0.6785-0.8212)
464	65	0	0.7585 ± 0.0362 (0.6785-0.8212)
466	62	0	0.7585 ± 0.0362 (0.6785-0.8212)
467	61	0	0.7585 ± 0.0362 (0.6785-0.8212)
468	59	0	0.7585 ± 0.0362 (0.6785-0.8212)
469	58	0	0.7585 ± 0.0362 (0.6785-0.8212)
470	57	0	0.7585 ± 0.0362 (0.6785-0.8212)
471	56	0	0.7585 ± 0.0362 (0.6785-0.8212)
472	55	1	0.7447 ± 0.0381 (0.6608-0.8108)
474	54	0	0.7447 ± 0.0381 (0.6608-0.8108)
475	53	0	0.7447 ± 0.0381 (0.6608-0.8108)
477	52	1	0.7304 ± 0.04 (0.6427-0.7999)
482	51	0	0.7304 ± 0.04 (0.6427-0.7999)

483	50	1	0.7304 ± 0.04 (0.6427-0.7999)
486	49	0	0.7158 ± 0.0418 (0.6245-0.7886)
487	48	0	0.7158 ± 0.0418 (0.6245-0.7886)
492	47	0	0.7158 ± 0.0418 (0.6245-0.7886)
494	46	0	0.7158 ± 0.0418 (0.6245-0.7886)
497	45	0	0.7158 ± 0.0418 (0.6245-0.7886)
500	43	0	0.7158 ± 0.0418 (0.6245-0.7886)
502	42	0	0.7158 ± 0.0418 (0.6245-0.7886)
503	41	0	0.7158 ± 0.0418 (0.6245-0.7886)
510	39	0	0.7158 ± 0.0418 (0.6245-0.7886)
512	37	0	0.7158 ± 0.0418 (0.6245-0.7886)
526	36	0	0.7158 ± 0.0418 (0.6245-0.7886)
536	34	0	0.7158 ± 0.0418 (0.6245-0.7886)
547	33	0	0.7158 ± 0.0418 (0.6245-0.7886)
563	32	0	0.7158 ± 0.0418 (0.6245-0.7886)
566	31	0	0.7158 ± 0.0418 (0.6245-0.7886)
568	30	0	0.7158 ± 0.0418 (0.6245-0.7886)
572	29	0	0.7158 ± 0.0418 (0.6245-0.7886)
583	28	1	0.6902 ± 0.0475 (0.5867-0.7728)
588	27	0	0.6902 ± 0.0475 (0.5867-0.7728)
594	26	1	0.6637 ± 0.0525 (0.5496-0.7552)
606	25	1	0.6371 ± 0.0567 (0.5148-0.7364)
612	23	0	0.6371 ± 0.0567 (0.5148-0.7364)
613	22	0	0.6371 ± 0.0567 (0.5148-0.7364)
638	21	0	0.6371 ± 0.0567 (0.5148-0.7364)
648	20	0	0.6371 ± 0.0567 (0.5148-0.7364)
660	19	1	0.6036 ± 0.0629 (0.4693-0.714)
663	18	1	0.5701 ± 0.0678 (0.4271-0.6898)
681	17	0	0.5701 ± 0.0678 (0.4271-0.6898)
682	16	0	0.5701 ± 0.0678 (0.4271-0.6898)
687	15	0	0.5701 ± 0.0678 (0.4271-0.6898)
695	14	0	0.5701 ± 0.0678 (0.4271-0.6898)
711	13	0	0.5701 ± 0.0678 (0.4271-0.6898)
734	12	0	0.5701 ± 0.0678 (0.4271-0.6898)
760	11	0	0.5701 ± 0.0678 (0.4271-0.6898)
765	10	0	0.5701 ± 0.0678 (0.4271-0.6898)
771	8	0	0.5701 ± 0.0678 (0.4271-0.6898)
791	6	0	0.5701 ± 0.0678 (0.4271-0.6898)
810	5	0	0.5701 ± 0.0678 (0.4271-0.6898)
811	4	1	0.4275 ± 0.1335 (0.1745-0.6613)
835	3	0	0.4275 ± 0.1335 (0.1745-0.6613)
883	2	0	0.4275 ± 0.1335 (0.1745-0.6613)
911	1	0	0.4275 ± 0.1335 (0.1745-0.6613)

Note: FU: follow-up; N: total number of cases; n: incidences of postoperative complications
Values are mean ± standard error with 95% confidence interval.

serious because a complete resection of the mammary tissue involving silicone would not be achieved, a diagnosis of rupture of the device may be missed due to the residual presence of silicone even after explantation and silicone compounds may be present in breast milk [63,64]. Third, patients receiving the BellaGel® SmoothFine should be meticulously evaluated for possible detrimental effects due to an unknown number of those with the 4-layered device.

To summarize, our results are as follows:

1) A total of 48 cases (19.1%) of postoperative complications occurred; these include 22 cases (8.8%) of CC, 8 cases (3.2%) of dissatisfaction with shape, 7 cases (2.8%) of sliding/foreign body sensation, 4 cases (1.6%) of early seroma, 3 cases (1.2%) of early hematoma, 3 cases (1.2%) of infection and 1 case (0.4%) of wound dehiscence.

2) TTEs were estimated at 331.35 ± 12.83 days (95% CI 306.09-356.62).

But limitations of the current study are as follows: First, we failed to perform a sufficiently long-term follow-up of our cohorts to verify whether a time point of 3 months postoperatively would be minimally necessary to detect the CC. Further large-scale, long-term follow-up studies and more evidence-based efforts are warranted to validate our approaches. Second, we failed to evaluate our clinical series of the patients under the prospective design. Prospective studies, including randomized controlled trials in particular, are more reliable in showing more scientifically sound approaches and valuable outcomes as compared with retrospective ones. It is difficult, however, to conduct prospective studies [65]. Third, there were 22 cases (8.8%) of CC in our series, which cannot be generalized because of a short length of follow-up. According to a 10-year prospective study conducted by Maxwell GP, et al. [66,67] there was an approximately 1% increase in the incidence of CC of Baker grade III/IV from that described in their previous 6-year “Core” study. It can therefore be inferred that the incidence of CC might further rise over time. Fourth, we failed to quantify aesthetic outcomes using preoperative anthropometric measurements obtained on the Divina™ 3-D Scanner. Fifth, we failed to assess the value of the thickness of dermis, subcutaneous tissue and pectoralis major as indicators of postoperative swelling.

Conclusions

Here, we describe 3-year safety outcomes of an implant-based augmentation mammoplasty using the BellaGel® SmoothFine in Korean women. But the KFDS and surgeons should perform a meticulous long-term follow-up of patients receiving the BellaGel® SmoothFine and then consider the possibility that they might be vulnerable to its possible detrimental effects. According to a recent study, the BellaGel® SmoothFine and the Motiva Ergonomix™ are popular brands of a microtextured breast implant in Korea. From our empirical experience, however, the BellaGel® SmoothFine is not preferable to the Motiva Ergonomix™; the former shows a higher rate of CC, as shown in the current study, and its profile is lower as compared with the latter [23]. In this regard, the Motiva Ergonomix™ is a device of choice for Korean women receiving the BellaGel® SmoothFine.

Funding

This is a non-manufacturer-sponsored study.

Acknowledgments

This study was supported by the Korean Society of Breast Implant Research.

Conflict of Interest

The authors have nothing to declare in relation to the current work.

Compliance with Ethical Standards

Ethical approval

All procedures performed in this study were in accordance with the 1964 Declaration of Helsinki and its later amendments or comparable ethical standards.

Informed consent

Written informed consent was waived due to the retrospective nature of the current study.

References

1. Murphy DK, Beckstrand M, Sarwer DB (2009) A prospective, multi-center study of psychosocial outcomes after augmentation with natrelle silicone-filled breast implants. *Ann Plast Surg* 62: 118-121.
2. McCarthy CM, Cano SJ, Klassen AF, Scott A, Van Laeken N, et al. (2012) The magnitude of effect of cosmetic breast augmentation on patient satisfaction and health-related quality of life. *Plast Reconstr Surg* 130: 218-223.
3. Coriddi M, Angelos T, Nadeau M, Bennett M, Taylor A (2013) Analysis of satisfaction and well-being in the short follow-up from breast augmentation using the BREAST-Q, a validated survey instrument. *Aesthet Surg J* 33: 245-251.
4. Alderman AK, Bauer J, Fardo D, Abrahamse P, Pusic A (2014) Understanding the effect of breast augmentation on quality of life: prospective analysis using the BREAST-Q. *Plast Reconstr Surg* 133: 787-795.
5. Gladfelter J, Murphy D (2008) Breast augmentation motivations and satisfaction: a prospective study of more than 3,000 silicone implantations. *Plast Surg Nurs* 28: 170-174.
6. Correia-Sá I, Cordeiro MN, Amarante J, Marques M (2017) Predictors of satisfaction in patient with silicone breast implants and its association with drug intake habits. *Acta Chir Belg* 117: 89-98.
7. Thorne CH (2010) An evidence-based approach to augmentation mammoplasty. *Plast Reconstr Surg* 126: 2184-2188.
8. Lista F, Ahmad J (2013) Evidence-based medicine: augmentation mammoplasty. *Plast Reconstr Surg* 132: 1684-1696.
9. Schwartz MR (2017) Evidence-Based Medicine: Breast Augmentation. *Plast Reconstr Surg* 140: 109e-119e.
10. Hedén P, Jernbeck J, Hober M (2001) Breast augmentation with anatomical cohesive gel implants: the world's largest current experience. *Clin Plast Surg* 28: 531-552.
11. Tebbetts JB (2002) A system for breast implant selection based on patient tissue characteristics and implant-soft tissue dynamics. *Plast Reconstr Surg* 109: 1396-1409.
12. Tebbetts JB, Adams WP (2005) Five critical decisions in breast augmentation using five measurements in 5 minutes: the high five decision support process. *Plast Reconstr Surg* 116: 2005-2016.
13. Sung JY, Jeong JP, Moon DS, Kim MS, Kim HC, et al. (2019) Short-term Safety of Augmentation Mammoplasty Using the BellaGel Implants in Korean Women. *Plast Reconstr Surg Glob Open* 7: e2566.
14. Choi MS, Chang JH, Seul CH (2020) A multi-center, retrospective, preliminary observational study to assess the safety of BellaGel® after augmentation mammoplasty. *Eur J Plast Surg* 43: 577-582.
15. Han J, Jeong JH, Bang SI, Heo CY (2019) BellaGel breast implant: 4-year results of a prospective cohort study. *J Plast Surg Hand Surg* 53: 232-239.
16. Oh JS, Jeong JH, Myung Y, Oh J, Kang SH, et al. (2020) BellaGel breast implant: 6-Year results of a prospective cohort study. *Arch Plast Surg* 47: 235-241.
17. Headon H, Kasem A, Mokbel K (2015) Capsular Contracture after Breast Augmentation: An Update for Clinical Practice. *Arch Plast Surg* 42: 532-543.
18. Nam SY, Lee M, Shin BH, Elfeky Bassem, Lee YU, et al. (2019) Characterization of BellaGel SmoothFine implant surfaces and correlation with capsular contracture. *J Biomater Nanobiotechnol* 10: 196-211.
19. Yoon S, Chang JH (2020) Short-term Safety of a Silicone Gel-filled Breast Implant: A Manufacturer-sponsored, Retrospective Study. *Plast Reconstr Surg Glob Open* 8: e2807.
20. Kang SH, Oh JS, Jin US, Bang SI, Kim A, et al. (2020) Retrospective Multicenter Cohort Analysis of 621 Cases of BellaGel Silicone Breast Implants with Study of Physicochemical Properties and Surface Topography. *J Plast Reconstr Aesthet Surg*.
21. Kim JH (2020) Association of the BellaGel® Breast Implant Scandal with the Poly Implant Prothèse Fraud: A Review of Literatures. *J Surg Open Access* 7: 1-10.
22. Kim JH (2021) The Manufacturer's Deliberate Modification of the Shell Structure of the BellaGel® SmoothFine in Violation of the Regulatory Requirement. *J Surg Open Access* 7: 1-5.
23. Moon DS, Choi WS, Kim HC, Jeong JP, Sung JY, Kim JH (2021) Short-term treatment outcomes and safety of two representative brands of the fifth-generation silicone gel-filled breast implants in Korea. *J Plast Surg Hand Surg*.
24. Montemurro P, Cheema M, Hedén P, Ferri M, Li AQ, et al. (2017) Role of Macrot textured Shaped Extra Full Projection Cohesive Gel Implants in Primary Aesthetic Breast Augmentation. *Aesthet Surg J* 37: 408-418.
25. Tebbetts JB (2002) A system for breast implant selection based on patient tissue characteristics and implant-soft tissue dynamics. *Plast Reconstr Surg* 109: 1396-1409.
26. Hedén P, Montemurro P, Adams WP Jr, Germann G, Schefflan M, et al. (2015) Anatomical and Round Breast Implants: How to Select and Indications for Use. *Plast Reconstr Surg* 136: 263-272.
27. Adams WP Jr (2008) The process of breast augmentation: four sequential steps for optimizing outcomes for patients. *Plast Reconstr Surg* 122: 1892-1900.
28. Mailey B, Freel A, Wong R, Pointer DT, Khoobehi K (2013) Clinical accuracy and reproducibility of Portrait 3D Surgical Simulation Platform in breast augmentation. *Aesthet Surg J* 33: 84-92.
29. Bui JM, Perry T, Ren CD, Nofrey B, Teitelbaum S, et al. (2015) Histological characterization of human breast implant capsules. *Aesthetic Plast Surg* 39: 306-315.
30. Meza Britez ME, Caballero Llano C, Chaux A (2012) Periprosthetic breast capsules and immunophenotypes of inflammatory cells. *Eur J Plast Surg* 35: 647-651.
31. Darby IA, Laverdet B, Bonté F, Desmoulière A (2014) Fibroblasts and myofibroblasts in wound healing. *Clin Cosmet Investig Dermatol* 7: 301-311.
32. Ibrahim MM, Chen L, Bond JE, Medina MA, Ren L, et al. (2015) Myofibroblasts contribute to but are not necessary for wound contraction. *Lab Invest* 95: 1429-1438.
33. Shin D, Minn KW (2004) The effect of myofibroblast on contracture of hypertrophic scar. *Plast Reconstr Surg* 113: 633-640.
34. Al-Qattan MM, Abd-Elwahed MM, Hawary K, Arafah MM, Shier MK (2015) Myofibroblast expression in skin wounds is enhanced by collagen III suppression. *Biomed Res Int* 2015: 958695.
35. Otranto M, Sarrazy V, Bonté F, Hinz B, Gabbiani G, et al. (2012) The role of the myofibroblast in tumor stroma remodeling. *Cell Adh Migr* 6: 203-219.
36. Swartz MA, Lund AW (2012) Lymphatic and interstitial flow in the tumour microenvironment: linking mechanobiology with immunity. *Nat Rev Cancer* 12: 210-219.

37. Zeltz C, Primac I, Erusappan P, Alam J, Noel A, et al. (2020) Cancer-associated fibroblasts in desmoplastic tumors: emerging role of integrins. *Semin Cancer Biol* 62: 166-181.
38. Coleman DJ, Sharpe DT, Naylor IL, Chander CL, Cross SE (1993) The role of the contractile fibroblast in the capsules around tissue expanders and implants. *Br J Plast Surg* 46: 547-556.
39. Gabbiani G, Ryan GB, Majne G (1971) Presence of modified fibroblasts in granulation tissue and their possible role in wound contraction. *Experientia* 27: 549-550.
40. Shu DY, Lovicu FJ (2017) Myofibroblast transdifferentiation: The dark force in ocular wound healing and fibrosis. *Prog Retin Eye Res* 60: 44-65.
41. Bhandary B, Meng Q, James J, Osinska H, Gulick J, et al. (2018) Cardiac Fibrosis in Proteotoxic Cardiac Disease is Dependent Upon Myofibroblast TGF- β Signaling. *J Am Heart Assoc* 7: e010013.
42. Jester JV, Brown D, Pappa A, Vasiliou V (2012) Myofibroblast differentiation modulates keratocyte crystallin protein expression, concentration, and cellular light scattering. *Invest Ophthalmol Vis Sci* 53: 770-778.
43. Kramann R, Schneider RK (2018) The identification of fibrosis-driving myofibroblast precursors reveals new therapeutic avenues in myelofibrosis. *Blood* 131: 2111-2119.
44. Zhang Z, Suo L, Chen Y, Zhu L, Wan G, et al. (2019) Endometriotic Peritoneal Fluid Promotes Myofibroblast Differentiation of Endometrial Mesenchymal Stem Cells. *Stem Cells Int* 2019: 6183796.
45. Huang CK, Handel N (2010) Effects of Singulair (montelukast) treatment for capsular contracture. *Aesthet Surg J* 30: 404-408.
46. Bresnick SD (2017) Prophylactic Leukotriene Inhibitor Therapy for the Reduction of Capsular Contracture in Primary Silicone Breast Augmentation: Experience with over 1100 Cases. *Plast Reconstr Surg* 139: 379-385.
47. Reid RR, Greve SD, Casas LA (2005) The effect of zafirlukast (Accolate) on early capsular contracture in the primary augmentation patient: a pilot study. *Aesthet Surg J* 25: 26-30.
48. Chourmouzi D, Vryzas T, Drevelegas A (2009) New spontaneous breast seroma 5 years after augmentation: a case report. *Cases J* 2: 7126.
49. Kästner S, Paprottka FJ, Gonser P, López MV, Kaye KO (2018) Recurrent 8-Year Ongoing Unilateral Breast Seroma Formation after PIP Implant Removal-A Case Report and Review of the Literature. *Surg J* 4: e46-e51.
50. Bengtson B, Brody GS, Brown MH, Glicksman C, Hammond D, et al. (2011) Managing late periprosthetic fluid collections (seroma) in patients with breast implants: a consensus panel recommendation and review of the literature. *Plast Reconstr Surg* 128: 1-7.
51. Meggiorini ML, Maruccia M, Carella S, Sanese G, De Felice C, et al. (2013) Late massive breast implant seroma in postpartum. *Aesthetic Plast Surg* 37: 931-935.
52. Pinchuk V, Tymofii O (2011) Seroma as a late complication after breast augmentation. *Aesthetic Plast Surg* 35: 303-314.
53. Mazzocchi M, Dessy LA, Carlesimo B, Marchetti F, Scuderi N (2010) Late seroma formation after breast surgery with textured silicone implants: a problem worth bearing in mind. *Plast Reconstr Surg* 125: 176e-177e.
54. Park BY, Lee DH, Lim SY, Pyon JK, Mun GH, et al. (2014) Is late seroma a phenomenon related to textured implants? A report of rare complications and a literature review. *Aesthetic Plast Surg* 38: 139-145.
55. Hall-Findlay EJ (2011) Breast implant complication review: double capsules and late seromas. *Plast Reconstr Surg* 127: 56-66.
56. Tansley PD, Powell BW (2011) Late swelling after bilateral breast augmentation. *J Plast Reconstr Aesthet Surg* 64: 261-263.
57. Mazzocchi M, Dessy LA, Corrias F, Scuderi N (2012) A clinical study of late seroma in breast implantation surgery. *Aesthetic Plast Surg* 36: 97-104.
58. Spear SL, Rottman SJ, Glicksman C, Brown M, Al-Attar A (2012) Late seromas after breast implants: theory and practice. *Plast Reconstr Surg* 130: 423-435.
59. Becker H, Klimczak J (2016) Aspiration of Periprosthetic Seromas Using the Blunt SeromaCath. *Plast Reconstr Surg* 137: 473-475.
60. Kim JH, Paik NS, Nam SY, Cho Y, Park HK (2020) The Emerging Crisis of Stakeholders in Implant-based Augmentation Mammoplasty in Korea. *J Korean Med Sci* 35: e103.
61. Brown SL, Pennello G, Berg WA, Soo MS, Middleton MS (2001) Silicone gel breast implant rupture, extracapsular silicone, and health status in a population of women. *J Rheumatol* 28: 996-1003.
62. Accurso A, Rocco N, Feleppa C, Palumbo A, D'Andrea F (2008) Spread of silicone to axillary lymph nodes after high cohesive gel silicone implant rupture. *Plast Reconstr Surg* 122: 221e-222e.
63. Marotta JS, Goldberg EP, Habal MB, Amery DP, Martin PJ, et al. (2002) Silicone gel breast implant failure: evaluation of properties of shells and gels for explanted prostheses and meta-analysis of literature rupture data. *Ann Plast Surg* 49: 227-242.
64. Berg WA, Nguyen TK, Middleton MS, Soo MS, Pennello G, et al. (2002) MR imaging of extracapsular silicone from breast implants: diagnostic pitfalls. *AJR Am J Roentgenol* 178: 465-472.
65. Niechajev I, Jurell G, Lohjelm L (2007) Prospective study comparing two brands of cohesive gel breast implants with anatomic shape: 5-year follow-up evaluation. *Aesthetic Plast Surg* 31: 697-710.
66. Maxwell GP, Van Natta BW, Bengtson BP, Murphy DK (2015) Ten-year results from the Natrelle 410 anatomical form-stable silicone breast implant core study. *Aesthet Surg J* 35: 145-155.
67. Maxwell GP, Van Natta BW, Murphy DK, Slicton A, Bengtson BP (2012) Natrelle style 410 form-stable silicone breast implants: core study results at 6 years. *Aesthet Surg J* 32: 709-717.