

Peripheral Ossifying Fibroma Mimicking Pyogenic Granuloma: A Case Report and Review of Literature

Raniah Abdullah Al Eid*

Department of Oral and Maxillofacial Surgery, College of Dentistry, King Saud University, Riyadh, KSA

*Corresponding author: Raniah Abdullah Al Eid, Department of Oral and Maxillofacial Surgery, College of Dentistry, King Saud University, Riyadh, KSA, Tel: +966500850350; E-mail: rabdulla@ksu.edu.sa

Received: 23 Dec, 2019 | Accepted: 31 Dec, 2019 | Published: 06 Jan, 2020

Citation: Al Eid RA (2020) Peripheral Ossifying Fibroma Mimicking Pyogenic Granuloma: A Case Report and Review of Literature. *J Surg Open Access* 6(1): dx.doi.org/10.16966/2470-0991.204

Copyright: © 2020 Al Eid RA. This is an open-access article distributed under the terms of the Creative Commons Attribution License, which permits unrestricted use, distribution, and reproduction in any medium, provided the original author and source are credited.

Abstract

A diagnostic challenge is usually present with oral soft tissue swellings due to similarity in the clinical presentation of variable oral lesions. Peripheral Ossifying Fibroma (POF) is a benign tumor of the gingiva, usually classified as a reactive hyperplasia but frequently as a benign neoplasm. Its typical clinical presentation includes gingival swelling that is slowly growing usually from interdental papilla in anterior maxilla and small in size <1.5 cm in diameter. It accounts about 9.6% of all gingival swellings and 3.1% of all oral tumors with female predilection. Pyogenic Granuloma (PG) is the most common type of hyperplasia in the oral cavity and is considered a non-neoplastic tumor. PG accounts about 37% to 42% of all gingival hyperplastic lesions with female predilection. PG and POF share common clinical presentation and etiologic factors which make their clinical differentiation confounding. The purpose of this article is to report a case of POF and review the current literature. A case of 27 years old Saudi male presented with a large gingival swelling affecting his aesthetic with one year duration. The lesion was excised and long term follow up has been planned to prevent recurrence. The histopathologic diagnosis of the lesion was POF that has been clinically identical to PG. The case varies from the usual clinical presentation and the paper discusses the need to find clinical diagnostic criteria to solve the diagnostic challenge.

Keywords: Peripheral ossifying fibroma; Pyogenic granuloma; Gingival swelling

Introduction

A diagnostic challenge is usually present with oral soft tissue swellings due to similarity in the clinical presentation of variable oral lesions.

Peripheral ossifying fibroma (POF) is a benign tumor of the gingiva usually classified as a reactive hyperplasia but frequently as a benign neoplasm. It is derived from cells of the periodontal ligament and it can arise from gingiva, periodontal membrane or periosteum [1]. Synonyms of POF are peripheral cementifying fibroma, peripheral fibroma with calcification and ossifying fibroid epulis [2]. The occurrence may be induced by local irritants such as plaque accumulation, calculus, chronic trauma, dental appliances, large restorations and microorganisms. Its typical clinical presentation is a gingival swelling that is slowly growing, grows from interdental papilla in anterior maxilla, usually small in size <1.5 cm in diameter, could be sessile or pedunculated, its surface is sometimes ulcerated and its color is similar to that of the gingiva or more reddish. Of all gingival growths it accounts about 9.6%, and of all oral tumors it accounts about 3.1% with female predilection in adolescents and young adults [2,3]. Its classification was not clarified whether it is a tumor or a reactive proliferation but its clinical behavior is benign [4]. It has a

possibility of recurrence with an incidences of 16-20% could be due to incomplete surgical removal or continual presence of the local irritant [2,3,5]. In most of the cases adjacent teeth and structures are not affected but in some instances it might leads to displacement, interfere with teeth eruption or significant disfigurement due to enlargement. In general ossifying fibroma mainly occurs in craniofacial area and categorized into central and peripheral depending on the location of its origin from the periodontal ligament in bone or in soft tissue respectively [6].

The diagnosis of POF is based on clinical and histopathologic features that include hyperkeratotic and acanthotic epithelium, collagenous connective tissue and the presence of bone and or other calcification [4,7]. Its management includes surgical excision with deep cut to include all parts and prevent recurrence [2]. Some researchers reported that it is considered a maturation of a pre-existing pyogenic granuloma [8].

Pyogenic granuloma (PG) is the most common type of hyperplasia in the oral cavity and considered a non-neoplastic tumor occurring in mucous membrane or skin [9]. About 75% affect the gingiva but it can be found less frequently in other locations such as lips, tongue and palate [8].

PG can arise spontaneously but its etiology is still not well understood. It could be a reactive to many stimuli such as chronic trauma, hormonal changes and certain medications such as oral contraceptives and retinoids [9]. An example of hormonal factors is the high incidence of the PG in pregnant ladies mostly related to high levels of hormones estrogen and progesterone [10]. PG occurs in all age groups but mainly in the age range of 11 to 40 years. The reported frequency of PG is 37% of all gingival hyperplastic lesions and 42% in another study in Brazil, with female predilection in 1:1.5. It is clinically presented as soft, small or large, rapidly growing, smooth or lobulated, pedunculated, exophytic vascular nodule and red in color that has a tendency to bleed easily.

Its diagnosis is based on clinical and histopathologic features that show proliferation of granulation tissue, capillaries and venules with lobules of endothelial cells or vascular neoformations within fibromyxoid stroma and inflammatory infiltrates. It has been believed to pass through phases: cellular phase, capillary or vascular phase, and involutionary phase. It has been classified into two types from histopathologic point of view: (1) capillary lobular hemangioma if it shows capillary vessels structured into lobes of granulomatous tissue enveloped by a thin layer of collagen; and (2) non lobular capillary hemangioma shows unorganized capillary vessels within connective tissue stroma [9].

PG and POF share common clinical presentation and etiologic factors which make their clinical differentiation challenging. Histopathologically the POF can be identified by its characteristic feature of high cellularity, bone deposition and cementum-like formation.

Although the literature shows multiple case reports of PG and POF but few publications comparing the two lesions to aid in setting a diagnostic criteria of clinical differentiation between them [7,8].

The purpose of the article is to report a case of peripheral ossifying fibroma that clinically mimics pyogenic granuloma and to review the current literature.

Case Report

A 27 years old Saudi male patient presented in the clinic of Oral and Maxillofacial Surgery in College of Dentistry at King Saud University with a chief complain of a large swelling in the gum affecting his aesthetic, speech and occlusion. The history of the chief complain is that it started almost one year ago, asymptomatic, slowly growing until it became interfering with his occlusion and bleeds easily.

The patient is healthy, does not have any history of medical illness and not taking any medications. He is a smoker since 10 years ago.

Clinical examination

On clinical extra-oral examination no abnormality detected other than mandibular prognathism and the patient has thin body build. Intra-oral examination revealed that in general the patient has poor oral hygiene, multiple deep caries. The lesion contains two parts: the labial and lingual parts located in the left side of the mandible originating from the interdental papilla between canine and lateral incisor. The lingual part is the larger part measuring about 3 cm in width and 2.7 cm in height covered with normal mucosa, pink to reddish in color, firm and rubbery in consistency, pedunculated and overlapping the occlusal surface of the canine and premolars. The labial part is smaller in size measuring about 1 cm in width and 1.5 cm in height, pedunculated, soft in consistency, pink to more reddish in color and bleeds easily. Both lesions are connected with a broad neck from the interdental papilla (Figure 1).

Radiographic examination

Panoramic view revealed no significant bony changes in the lesion area except a displacement of the teeth 33 and 32 away from the lesion. In addition the patient has multiple badly decayed teeth and periapical radiolucency apical to tooth 46 (Figure 2).

Surgical procedure

The planned treatment procedure, all possible risks and benefits were explained to the patient and he agreed and signed a consent form. An excisional biopsy was done under local anesthesia infiltration around the lesion using 2% lidocaine with 1:100000 epinephrine and following sterile standard surgical procedure. A deep curettage in the periphery of the lesion was done to remove any possible remnants, and then the defect was closed properly with the labial and lingual mucosa (Figure 3).

The specimen taken in two parts; the large lingual and the small labial, labelled accordingly into two formalin containing bottles and sent to histopathology laboratory.

The histopathologic description

Provided the diagnosis separately; the large lingual part reveals a nodular mass. The mass is lined by keratinized stratified squamous epithelium. The epithelium exhibit hyperkeratosis, acanthosis, hyperplastic rete ridges and pseudoepitheliomatous hyperplasia. The

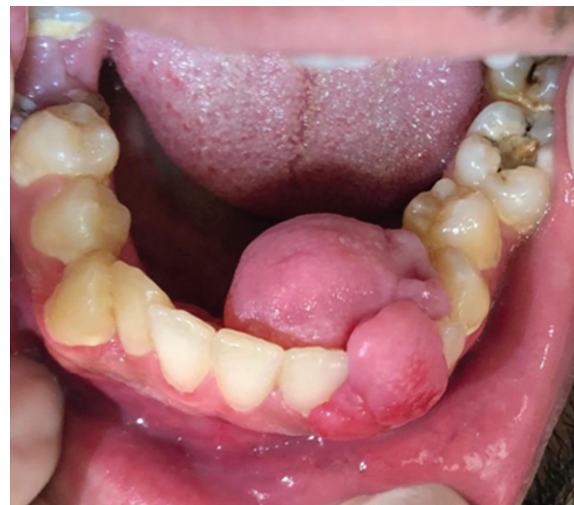

Figure 1: The lesion on clinical presentation.

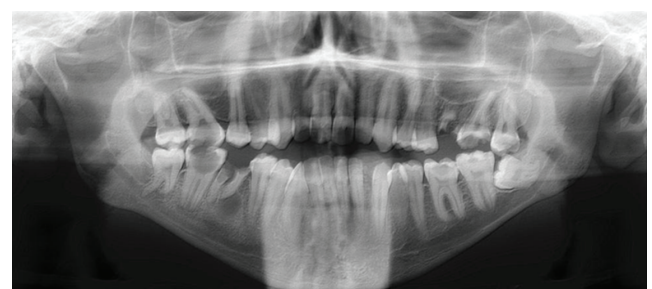


Figure 2: Radiographic examination, panoramic view shows no significant bony changes in the lesion area except a displacement of the teeth 33 and 32 away from the lesion.

tumor is heavily collagenized and composed mainly of proliferation of fibroblast-like spindle cells with deposition of bone (woven and lamellar) and occasional cementum-like droplets. Stromal myxoid changes, dilated blood vessels and few adipose tissues are noticed around the osteoid bone. Patchy chronic inflammation composed mainly of plasma cells are observed mainly around blood vessels. The diagnosis of this part is peripheral ossifying fibroma (Figure 4).

The labial part reveals a nodular mass lined by keratinized stratified squamous epithelium. The epithelium exhibit hyperkeratosis,

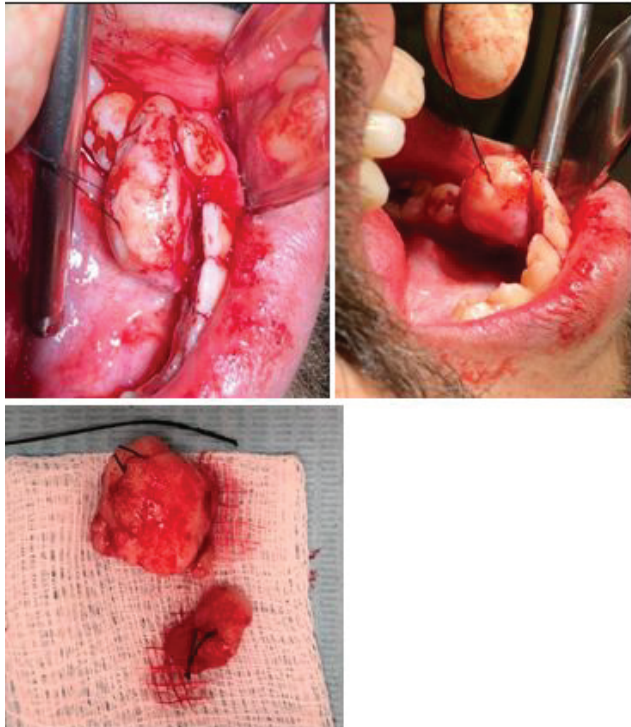


Figure 3: The surgical procedure includes excisional biopsy of the lingual and labial parts separately.

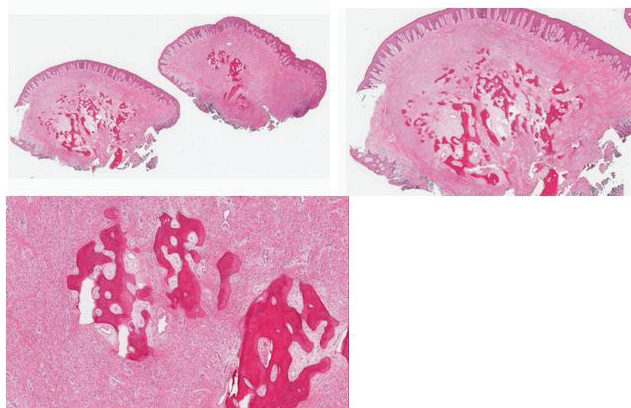


Figure 4: Histopathologic examination of the POF showing pseudoepitheliomatous hyperplasia heavily collagenized myxoid stroma with deposition of bone (woven and lamellar) and cementum-like droplets.

acanthosis, hyperplastic rete ridges and pseudoepitheliomatous hyperplasia. The underlying connective tissue composed of proliferation of collagen fibers with scattered vessels and marked chronic inflammation. The inflammatory cells composed mainly of plasma cells and present mainly around blood vessels. Small ulcer with subjacent granulation tissue is observed at one section. The diagnosis of this part is inflamed fibrous hyperplasia.

Post-operative care

Patient has been seen for follow up after one week (Figure 5), 2 weeks then 3 weeks postoperatively (Figure 6) and healing was in good progress. The patient given schedules to treat other dental problems, referred to hygienist, advised to maintain good oral hygiene and a long term follow up was given to prevent lesion recurrence.

Discussion

POF and PG were categorized as focal reactive overgrowths with different histopathologic features. Their pathogenesis is still unclear. Some researchers believe that POF may progress from a pre-existing PG that had fibrous maturation and ossification. In the other hand a case report of recurrent gingival growth has been reported with the primary diagnosis as POF and the recurrent diagnosis as PG [8].

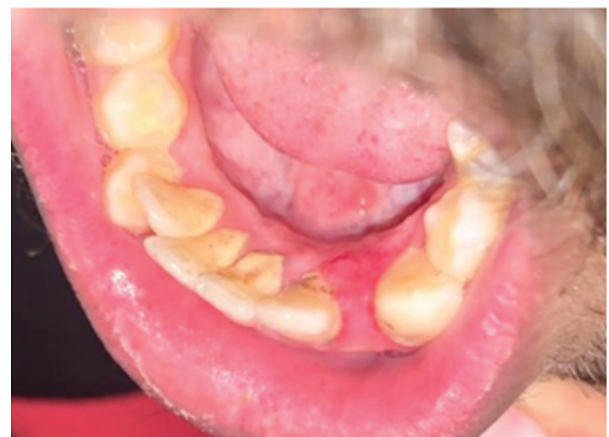

Figure 5: Clinical picture on follow up in one week post-surgical removal.

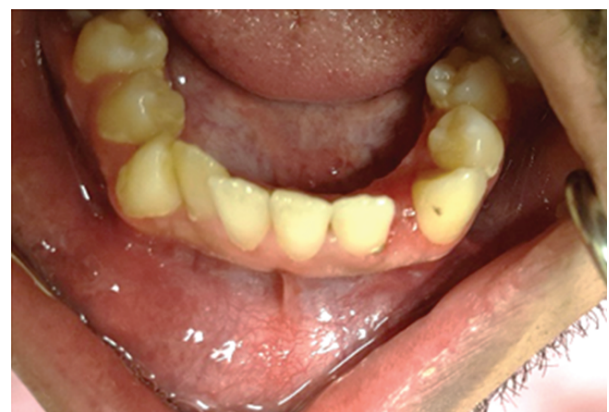

Figure 6: Clinical picture on follow up in three weeks post-surgical removal.

Varying clinical presentation of POF has been shown in literature but they share similar general features. Large size is rarely encountered, its reported dimension fall in the range between 0.4-9.0 cm in diameter with an average size about 1.0-2.5 cm in diameter. A case report showed a significant size in a 62 years old male patient presented with gross facial asymmetry in 5 years duration and the lesion measures about 10 cm × 6 cm located in the maxillary left alveolus and palate [11].

The provisional diagnosis in our case was pyogenic granuloma which presented similar clinical description, age and sex predilection and etiologic factors. Although some specific features in our case can be considered distinctive to POF include a size larger than 2 cm, more pale in color than redness and firm consistency which are not the usual features of PG. This could be explained by the histopathologic feature of POF which has a thick mucosa that is keratinized stratified squamous epithelium with hyperkeratosis, acanthosis, pseudoepitheliomatous hyperplasia and less marked inflammatory infiltrates in which the stoma is mainly collagenized. This is in contrast to PG which consists mainly of proliferation of granulation tissue, capillaries, venules, lobules of vascular neoforations and marked inflammatory infiltrates.

The fibro-osseous lesions that include ossifying fibroma, fibrous dysplasia, cemento-osseous dysplasia presented a diagnosis confusion to the clinician. Fibrous dysplasia is considered a developmental anomaly, while ossifying fibroma and cemento-osseous dysplasia are considered reactive in nature. These lesions usually do not show neoplastic behavior and their clinical features varies from fibrous dysplasia [1,12].

A rare subtype of ossifying fibroma is Juvenile Psammomatoid Ossifying Fibroma (JPOF) that is a benign tumour affects facial bones and mainly the mandible occurs in young patients with aggressive behaviour and require en-block resection [13]. It differs clinically from POF in its aggressive behavior, location and age of occurrence. In addition JPOF has a unique histopathologic finding of psammoma bodies, osteoblastic and osteoclastic activity at the periphery and mitotic figures.

Immunohistochemical analysis of POF showed the proliferating cells are myofibroblastic. The positivity of C68 with histiocytes intermixed with plasma cells and lymphocytes indicates the reactive response to inflammation [7,11]. This indicates a more reactive nature of POF than being neoplastic.

A similar case report of 60 years old female patient reported with a growth on the gingiva in the maxilla on left anterior region with three years duration measuring about 2.5 × 3 cm in dimension. In contrast to our case, this case shows more typical clinical characteristic of POF in relation to its age, sex of occurrence and location [2].

Several case reports from the literature show clinical presentation of POF to be predominated in female in middle age and almost all involved the maxillary region which are the characteristic features of POF [2-6,14,15]. While in our case, the lesion was located in anterior mandible and in a healthy male who is not taking any medications, which are non-diagnostic to POF and make the clinical judgment challenging.

Treatment includes deep surgical excision and depending on its size it might need connective tissue grafts or porcine collagen matrix Mucograft (Geistlich) [16]. In our case the resulting defect located in the free gingival margin. A relieving of the buccal and lingual flaps provided enough coverage to close the defect properly without the need of soft tissue graft.

Conclusion

Peripheral ossifying fibroma presented very close clinical features to pyogenic granuloma and an appropriate diagnosis is significant for patient's management. Histopathological investigation remains mandatory for definite diagnosis. The treatment of choice is complete surgical excision, elimination of the possible causative factor and regular patient follow up.

References

- Liu Y, Wang H, You M, Yang Z, Miao J, et al. (2010) Ossifying fibromas of the jaw bone: 20 cases. *Dentomaxillofac Radiol* 39: 57-63.
- Bhasin M, Bhasin V, Bhasin A (2013) Peripheral Ossifying Fibroma. *Case Rep Dent* 2013: 497234.
- Agarwal P, Chug A, Kumar S, Jain K (2019) Palatal peripheral ossifying fibroma: A rare occurrence. *Int J Health Sci (Qassim)* 13: 63-66.
- Chhina S, Rathore AS, Ahuja P (2011) Peripheral ossifying fibroma of gingiva: A case report. *Int J Case Reports Images* 2: 21-24.
- Poonacha KS, Shigli AL, Shirol D (2010) Peripheral ossifying fibroma: A clinical report. *Contemp Clin Dent* 1: 54-56.
- Arunachalam M, Saravanan T, Shakila KR, Anisa N (2017) Peripheral ossifying fibroma: A case report and brief review. *SRM J Res Dent Sci* 8: 41-45.
- Neville BW, Damm DD, Allen CM, Chi AC (2015) *Oral and maxillofacial pathology*. 4th Edition, Elsevier Health Sciences.
- Prasad S, Reddy SB, Patil SR, Kalburgi NB, Puranik RS (2008) Peripheral ossifying fibroma and pyogenic granuloma. Are they interrelated? *N Y State Dent J* 74: 50-52.
- Wollina U, Langner D, França K, Gianfaldoni S, Lotti T, et al. (2017) Pyogenic Granuloma-A Common Benign Vascular Tumor with Variable Clinical Presentation: New Findings and Treatment Options. *Open Access Maced J Med Sci* 5: 423-426.
- Rosa CG, Lay AC, Torre ACL (2017) Oral pyogenic granuloma diagnosis and treatment: a series of cases. *Rev Odont Mex* 21: e244-e252.
- John RR, Kandasamy S, Achuthan N (2016) Unusually large-sized peripheral ossifying fibroma. *Ann Maxillofac Surg* 6: 300-303.
- Speight PM, Takata T (2018) New tumour entities in the 4th edition of the World Health Organization Classification of Head and Neck tumours: odontogenic and maxillofacial bone tumours. *Virchows Archiv* 472: 331-339.
- Quintero CC, Mazzei AS, Barbero JR, Diaz AP, Urzaiz LL (2016) Juvenile psammomatoid ossifying fibroma of the posterior fossa: a case report and review. *Springerplus* 5: 1089.
- Ganji KK, Chakki ABK, Nagral SC, Verma E (2013) Peripheral Cemento-Ossifying Fibroma: Case Series Literature Review. *Case Rep Dent* 2013: 930870.
- Mishra AK, Bhusari P, Kanteshwari K (2011) Peripheral cemento-ossifying fibroma-a case report. *Int J Dent Hygiene* 9: 234-237.
- González-Serrano J, López-Pintor RM, Sanz-Sánchez I, Paredes VM, Casañas E, et al. (2017) Surgical Treatment of a Peripheral Ossifying Fibroma and Reconstruction with a Porcine Collagen Matrix: A Case Report. *Int J Periodontics Restorative Dent* 37: 443-449.