

Post-Operative Cervical Subcutaneous Emphysema and Cellulitis following Iatrogenic Oropharyngeal Trauma during Intubation and Microlaryngoscopy: A Rare Complication

R Anmolsingh¹, O Mirza¹, V Narayan¹, J Gilchrist¹, J Roche¹, A Ismail² and BN Kumar^{1*}

¹Department of ENT, Wrightington, Wigan and Leigh NHS Foundation Trust, Wigan, UK

²Department of Radiology, Wrightington, Wigan and Leigh NHS Foundation Trust, Wigan, UK

*Corresponding author: BN Kumar, Department of ENT, Wrightington, Wigan and Leigh NHS Foundation Trust, Wigan, UK, E-mail: nirmalkumar@doctors.org.uk

Received date: 26 Dec 2016; Accepted date: 27 Jan 2017; Published date: 02 Feb 2017.

Citation: Anmolsingh R, Mirza O, Narayan V, Gilchrist J, Ismail A, et al. (2017) Post-Operative Cervical Subcutaneous Emphysema and Cellulitis following Iatrogenic Oropharyngeal Trauma during Intubation and Microlaryngoscopy: A Rare Complication. *J Surg Open Access* 3(1): doi <http://dx.doi.org/10.16966/2470-0991.140>

Copyright: © 2017 Anmolsingh R, et al. This is an open-access article distributed under the terms of the Creative Commons Attribution License, which permits unrestricted use, distribution, and reproduction in any medium, provided the original author and source are credited.

Abstract

Oropharyngeal trauma sustained through instrumentation during laryngoscopy is not uncommon. In most cases this is minor and can be managed conservatively without any significant sequelae. A mucosal breach, however, can lead to subcutaneous emphysema and allow an entry point for pathogens which can track along the cervicofacial planes of the neck. We present a case of cervical subcutaneous emphysema with superadded cellulitis secondary to the use of a postoperative continuous positive airway pressure (CPAP) device following trivial oropharyngeal trauma sustained during an elective microlaryngoscopy. Although there are similar documented cases, reports of this complication following microlaryngeal surgery are rare.

Introduction

Orotracheal intubation and pharyngolaryngoscopy are routine procedures performed frequently by anaesthetists and otolaryngologists respectively. Both procedures are relatively low risk, but have the propensity to provide unanticipated technical challenges. Oropharyngeal instrumentation during these procedures may cause inadvertent trauma to adjacent mucosal structures. Although not uncommon, these are typically managed conservatively and rarely progress to cause any significant sequelae. It has, however, been recognised that increased intrapharyngeal pressure, secondary to even trivial coughing, vomiting or straining, or with the use of positive pressure ventilation, in the presence of breached mucosa can lead to subcutaneous emphysema of the head and neck [1,2].

We present a case of cervical subcutaneous emphysema with superadded cellulitis secondary to the use of a postoperative Continuous Positive Airway Pressure (CPAP) device following trivial oropharyngeal trauma sustained during an elective microlaryngoscopy. Although there are similar documented cases, reports of this complication following microlaryngeal surgery are rare and there have been no similar case reports with patients undergoing such procedure followed by CPAP use.

Case Presentation

A 68-year-old man presented acutely to the emergency department with neck swelling, difficulty breathing and odynophagia 24 hours after being discharged following an uneventful microlaryngoscopy and biopsy of a suspicious lesion on his right vocal cord. He was classified as an American Society of Anaesthesiologists (ASA) physical status grade III and a Mallampatti grade 2 intubation. Endotracheal intubation was successfully performed using the GlideScope® video laryngoscope (GVL), followed by his microlaryngeal surgery. He made an unremarkable immediate postoperative recovery and was discharged home later the same day following a period of observation. Interestingly, his symptoms

appeared to have started shortly after commencing the use of his CPAP device and continued to progress rapidly. He had several medical comorbidities including type II diabetes, ischaemic heart disease, chronic obstructive pulmonary disease (COPD) and obstructive sleep apnoea for which he used CPAP during sleep. He was a long-term smoker.

On examination, he was alert, afebrile and apart from mild tachypnoea, his observational parameters were within normal limits. His voice was distorted, but there were no added upper airway sounds or respiratory distress. There was a significant erythematous, tender, diffuse swelling of the neck, predominantly around the right submandibular region but extending throughout the neck and into the upper chest, which did not typically feel like surgical emphysema. Neck movements were restricted and there was a degree of trismus but the oropharynx including the floor of mouth was otherwise normal. Fiberoptic nasopharyngolaryngoscopy showed oedema of the right lateral pharyngeal wall, but with no significant supraglottic oedema and no compromise of the glottis airway.

Investigations

Haematological investigations showed moderately elevated inflammatory markers and blood cultures were sent for Gram stain. A contrast CT scan of the neck showed diffuse oedema with subcutaneous fat stranding extending into the right parapharyngeal space deviating the pharynx/larynx to the left and extending inferiorly into the upper mediastinum with some gas in the submental and submandibular tissues. Radiological features were consistent with subcutaneous emphysema and an infectious/inflammatory process suggesting extensive soft tissue cellulitis and possible early abscess formation, but no drainable collection (Figure 1A and 1B).

Treatment

Initial management included general resuscitative measures and commencing nebulised adrenaline, intravenous steroids and empirical

broad spectrum intravenous antibiotics. The patient was jointly assessed by both the ENT and anaesthetic teams and a combined plan instituted. As he was stable and his airway was safe, it was agreed to initially manage him medically with close observation in a high dependency setting. However, it became subsequently apparent over the course of a few hours that his symptoms were evolving with progressive neck and airway swelling, and now starting to cause airway compromise. A decision was made to secure the airway, however, due to the degree of trismus, orotracheal intubation was considered to be challenging to secure safely, and therefore awake fiberoptic nasal intubation was selected and successfully performed in an operating theatre setting with the option of performing a surgical airway if this failed. He was sedated and ventilated on the intensive care unit, and medical treatment continued.

Outcome and Follow-up

After a period of 48 hours, whilst intubated, a repeat examination of the oral cavity did show a sloughy area lateral to the right anterior tonsillar pillar, which was not previously apparent and possibly suggestive of oropharyngeal trauma at the time of the primary procedure perhaps during either intubation or microlaryngoscopy. This may have served as the entry site for pathogens to extend into the soft tissues of the neck which may have been further proliferated by a CPAP device. A swab from this area cultured Group A *Streptococcus*. Blood cultures were negative and subsequent serial haematological investigations showed a gradual improvement in inflammatory markers in response to a clinical improvement seen in the degree of neck cellulitis and swelling over the course of a few days (Figure 2).

Interval CT imaging of the neck 1 week after initial presentation showed a significant radiological improvement, consistent with the clinical progress, with some residual oedema along the right pharyngeal wall, but no evidence of an abscess collection necessitating operative intervention. Although extubation would have been possible at this stage, a lower respiratory tract infection and a subsequent prolonged respiratory wean required a tracheostomy to facilitate this.

Histological analysis of right vocal cord biopsies taken during microlaryngoscopy confirmed a moderately to well differentiated invasive squamous cell carcinoma. Following discussion at the head and neck oncology multidisciplinary team meeting, a decision was made to treat his laryngeal malignancy (T2 N0 M0) with radiotherapy. The patient was decannulated, and 6 weeks after initial presentation and following a prolonged period of treatment and rehabilitation he was discharged home with a plan to commence his radiotherapy when fully recovered (Figure 3).

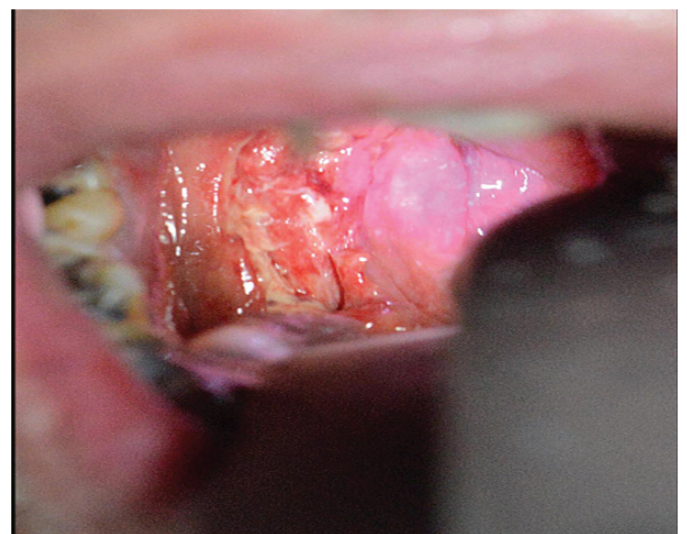

Figure 2: Area of loss of mucosal integrity in the region of the Right faucial pillar suggestive of site of trauma during oropharyngeal instrumentation.

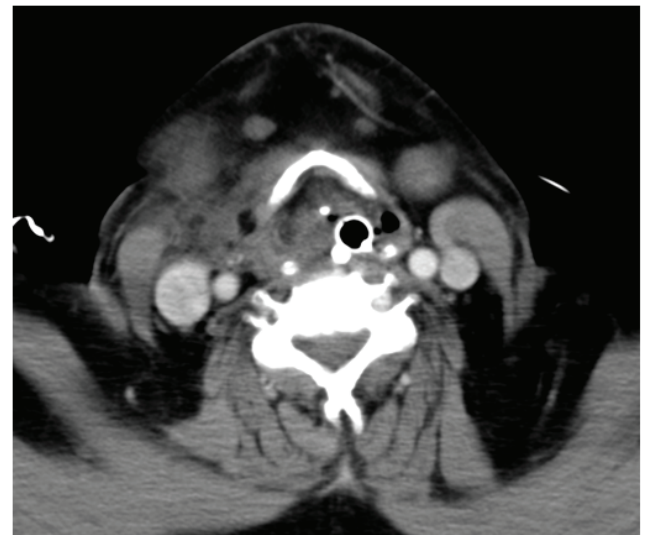

Figure 3: Interval axial CT scan image of the neck one week after initial presentation with an overall significantly improved appearance. Endotracheal and nasogastric tubes are seen *in situ*.

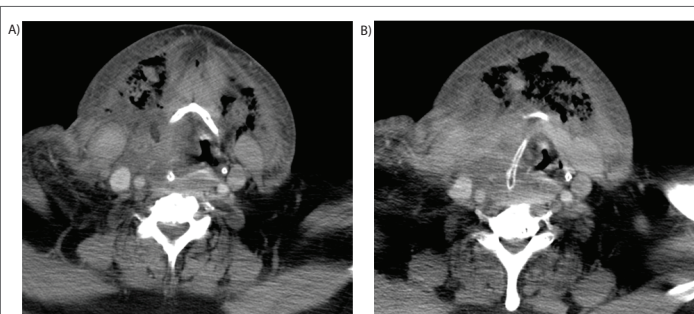


Figure 1: Axial CT scan images of the neck (A and B) showing marked gas in the submental region with diffuse oedema of the subcutaneous tissues, more so on the right, extending into the right parapharyngeal space and deviating the pharynx and larynx to the left with distortion of the glottis and supraglottis. No abscess collection, however, is seen.

Discussion

Vigorous manipulation during laryngoscopy and intubation must be avoided to minimise oropharyngeal trauma. Devices alternate to traditional laryngoscopy, such as the GVL, as used to facilitate intubation in our patient, may slightly increase the risk of inadvertent trauma [3]. Where oropharyngeal trauma has been sustained and recognised, appropriate methods should be employed to achieve haemostasis, by electrocoagulation or if a significant defect, closure by suture.

Surgical emphysema of the head and neck is a recognised, but rare, complication of intubation, direct laryngoscopy and other intra-oral, dental or maxillofacial procedures [4,5]. An instrumental factor appears to be the loss of integrity of the mucosal lining of the upper aerodigestive tract, as the development of surgical emphysema in the absence of mucosal damage is extremely rare [6,7]. In our case, the patient sustained a laceration to the right anterior tonsillar pillar, which we speculate occurred either during intubation or microlaryngoscopy, although no

obvious or significant oropharyngeal trauma at the time was noted. This likely created a porous mucosal surface that subsequently acted as a route for air entry. The use of CPAP device in the postoperative period correlated with the onset of his symptoms, conceivably through creating a sustained increase in his intrapharyngeal pressure, causing air to track rapidly through the subcutaneous tissues along the cervicofacial planes into the submental and parapharyngeal spaces as well as the superior mediastinum. Where oropharyngeal trauma has been sustained, it may be reasonable to suggest withholding the use of a face mask CPAP device in the immediate postoperative period to avoid such outcomes. This conclusion was also drawn by Chebel et al. [8], who had a similar experience following orthognathic surgery. There has been literature which also advises against nasal CPAP in the presence of facial blunt trauma [9]. The similarity lies where patients undergoing procedures which can result in oropharyngeal trauma and require CPAP post operatively resulted in subcutaneous emphysema. Fortunately, there is no mortality reported from such a complication to the authors' knowledge.

A break in the mucosa may also serve as an entry point for pathogens, which owing to the proximity of adjacent neck structures and the communication of cervical fascial planes, could potentially lead to infection within the deep neck spaces [10]. In our patient, there was an inflammatory response manifesting as a progressive cervical cellulitis likely secondary to superadded infection further propagated by an impaired immune response due to the patient's diabetes. A swab from the right anterior faucial pillar cultured Group A *Streptococcus*, representative of organisms found in the oropharynx.

The treatment of postoperative subcutaneous emphysema is based upon the severity of the condition. Most patients can be managed conservatively with close observation and will resolve without any significant sequelae [11]. If concurrent infection is suspected, initial broad-spectrum antibiotics should be administered, with subsequent therapy guided by culture results and input from microbiology colleagues. There is a role for systemic steroids, more so if there are concerns regarding airway oedema. If the patient is stable and it is safe to do so, imaging should be considered to delineate the extent of disease and to rule out any underlying deep neck space collection which may require surgical intervention. CT imaging may be the most accessible, sensitive and cost-effective imaging modality initially available, and should therefore be considered first line.

In severe cases where there is rapid progression and airway compromise, endotracheal intubation or surgical tracheostomy to secure and protect the airway may be required. Effective management of this condition relies on the early recognition of the clinical process, prompt diagnosis, careful airway assessment, timely involvement of the appropriate teams and urgent intervention where necessary to avoid a fatal outcome and minimize morbidity.

Limitations of the case

We acknowledge that the actual cause of the initial mucosal insult cannot be precisely pinpointed to the instrumentation by the anaesthetist or by the ENT surgeon. It is a difficult scenario to analyse since the resultant area of inflammation which followed could have occurred by

either clinician as both do share the same field when using their respective instruments. We also acknowledge that the patient may have benefitted from earlier intubation after presenting with subcutaneous emphysema. However, the choice to observe and monitor on the High Dependency Unit proved useful as we were able to detect the further deterioration in a timely manner whilst in a safe environment.

Conclusion

The inherent risk of subcutaneous emphysema after pharyngolaryngoscopy is a rare occurrence but is a known complication of oropharyngeal mucosal insult followed by CPAP use. Iatrogenic injury to upper digestive mucosa can occur at any time during instrumentation. Therefore, it is the authors' humble opinion that greater care must be undertaken when performing pharyngolaryngoscopy. We would highly recommend that patients either be advised to withhold CPAP use following pharyngolaryngoscopy or should it be needed, the patient can be admitted and observed for this complication while using the machine.

References

1. Chang Y, Lee J, Chen J, Lin Y (2010) A rare complication after microlaryngeal surgery: subcutaneous emphysema and pneumomediastinum. *J Chin Med Assoc* 73: 268-270.
2. Tran D, Littlefield P (2015) Late presentation of subcutaneous emphysema and pneumomediastinum following elective tonsillectomy. *Am J Otolaryngol* 36: 299-302.
3. Thorley DS, Simons AR, Mirza O, Malik V (2015) Palatal and retropharyngeal injury secondary to intubation using the GlideScope® video Laryngoscope. *Ann R Coll Surg Engl* 97: e67-e69.
4. Dolan S, Dolan A, Perry M (2015) Blowing your nose: Something not to be sniffed at. *Int J Surg* 23: 1743-9191.
5. Hampton S, Cinnamon M (1997) Subcutaneous emphysema as a complication of tonsillectomy. *J Laryngol Otol* 111: 1077-1078.
6. Gaitini L, Fradis M, Vaida S, Somri M, Malatskey S, et al. (2000) Pneumomediastinum due to Venturi jet ventilation used during microlaryngeal surgery in a previously neck-radiated patient. *Ann Otol Rhinol Laryngol* 109: 519-521.
7. Gasparini J, Ferreira L, Rangel V (2010) Subcutaneous emphysema induced by supplementary oxygen delivery nasopharyngeal cannula. Case report. *Rev Bras Anestesiologia* 60: 558-562.
8. Chebel NA, Ziade D, Achkouty R (2010) Bilateral pneumothorax and pneumomediastinum after treatment with continuous positive airway pressure after orthognathic surgery. *Brit J Oral Max Surg* 48: e14-e15.
9. Kramer NR, Fine MD, McRae RG, Millman RP (1997) Unusual complication of nasal CPAP: subcutaneous emphysema following facial trauma. *Sleep* 20: 895-897.
10. Pelaz AC, Pendàs JL, Nieto CS (2010) Ludwig's angina as an extremely unusual complication for direct microlaryngoscopy. *Am J Otolaryngol* 31: 117-119.
11. Panerari AC, Soter AC, Silva FL, Oliveira LF, Neves MD, et al. (2005) Onset of subcutaneous emphysema and pneumomediastinum after tonsillectomy: a case report. *Braz J Otorhinolaryngol* 71: 94-96.