

## A Rare Case of Penis Fracture after Nocturnal Unconscious Manipulation in a Child: A Case Report

Marcos Sforza<sup>1\*</sup>, Renato Zaccheddu<sup>1</sup>, Bruno Lopes Cancado<sup>2</sup>, and Deborah Sforza<sup>2</sup>

<sup>1</sup>Dolan Park Hospital, Bromsgrove, UK

<sup>2</sup>Urology Center Pro-Uro in Rio de Janeiro, Brazil

\*Corresponding author: Marcos Sforza, Dolan Park Hospital, Stoney Lane, B601LY, England, UK, E-mail: [marcos@marcossforza.com](mailto:marcos@marcossforza.com)

Received date: 04 Jul 2016; Accepted date: 29 Dec 2016; Published date: 04 Jan 2017.

Citation: Sforza M, Zaccheddu R, Cancado BL, Sforza D (2017) A Rare Case of Penis Fracture after Nocturnal Unconscious Manipulation in a Child: A Case Report. J Surg Open Access 3(1): doi <http://dx.doi.org/10.16966/2470-0991.138>

Copyright: © 2017 Sforza M, et al. This is an open-access article distributed under the terms of the Creative Commons Attribution License, which permits unrestricted use, distribution, and reproduction in any medium, provided the original author and source are credited.

### Abstract

**Introduction:** The penis fracture is a pathological condition that calls for immediate treatment. Nocturnal penile fracture has previously been described; however, the occurrence of such an event in a child is unprecedented in the current medical literature.

**Case presentation:** In this paper, we present a case of a black child with penis fracture caused by nocturnal unconscious manipulation. The current report delineates the most common aspects of this pathology in addition to its associated surgical treatment.

**Conclusion:** Penile fracture is classified as an emergency condition that cannot be excluded from the differential diagnosis, even at a young age.

**Keywords:** Penis fracture; Urogenital trauma; Penis hematoma

### Introduction

Fracture of the penis is often caused by a blunt trauma, which bends the penis during erection [1]. The typical anatomic finding is a tear of the tunica albuginea together with a rupture of the corpus cavernosum, which can be associated with urethral injury in the most severe cases [2]. Controversy persists over the initial treatment of fracture of the penis. The preponderance of research advocates an array of conservative treatments that include splinting of the penis, pressure dressing over a Foley catheter, ice packs, prolonged use of sedatives, enzymes such as streptokinase and trypsin, and estrogen (to prevent erection). However, permanent penile deformity with subsequent difficulty in coitus and suboptimal erection will ensue from the application of such conservative treatments. Accordingly, an increasing consensus is emerging that concedes to the fact that a residual deformity in some cases is an associated post-treatment complication. Common situations leading to this type of trauma are sexual intercourses and masturbation [3,4]. Notwithstanding, this traumatic rupture of the corpus cavernosum is a relatively rare presentation, which is inevitable considered a urologic emergency.

In the present review, we report on a 12-year-old male patient who sustained a fracture of the penis in a sleeping mode, exhibiting no indications that would signify any apparent traumatic event. Nocturnal penile fracture, though previously reported, the occurrence of such an event in a child is unprecedented in the current medical literature.

### Case Presentation

A 12-year-old black male child was admitted to our emergency department at 3.30 am accompanied by both parents, complaining of a sudden penile pain that interrupted his sleep. Shortly thereafter, increasing swelling involving the whole length of the penis followed. He denied potential underlying causes such as trauma, sexual intercourse or masturbation.

Upon examination, the patient presented substantial penile swelling, clearly due to a hematoma (Figure 1). The clinical diagnosis was sovereign and any additional diagnostic imaging tests were dismissed. The local unit did not dispose of an MRI and the team decided that the time was essence for the case. Basic laboratory pre-operative blood tests were conducted, subsequent to which he was taken to the operating room to undergo penis repair under general anesthesia. The procedure commenced with a coronal incision that allowed the penile skin to be "degloved". Following incising the Buck fascia and partially draining the hematoma, a tear of the tunica albuginea and a fracture of the right corpus cavernosum could be clearly noticed (Figure 2).

The entire area was irrigated and the tear was repaired with Vicryl 2.0 (Ehicon, USA) separate sutures (Figure 3). The defect was closed and the degloved skin was repositioned with sutures (Figure 4). There appeared to be no postoperative complications and the patient was discharged on the 3<sup>rd</sup> day. The urethra was accessed intraoperatively and no signs of trauma were found. A urinary catheter was inserted during the surgical act and

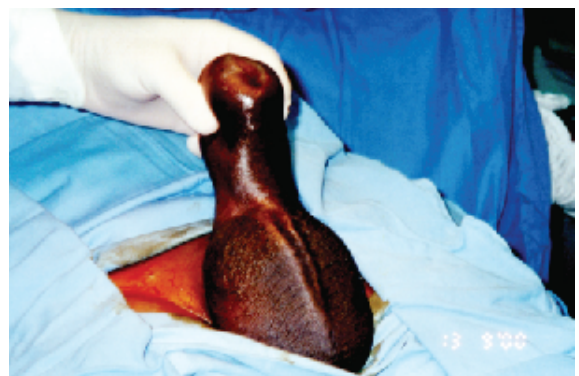


Figure 1: Clinical picture suggested fracture of the penis

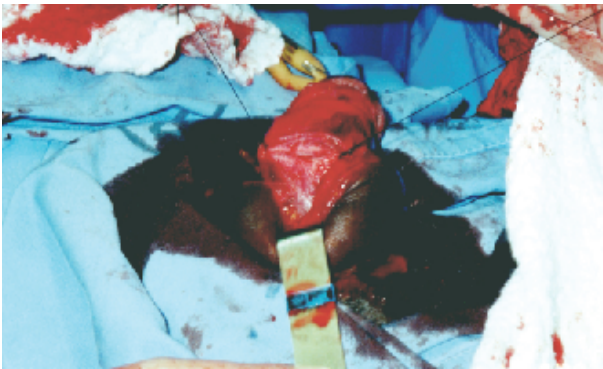

Figure 2: Fracture of the right corpus cavernosum

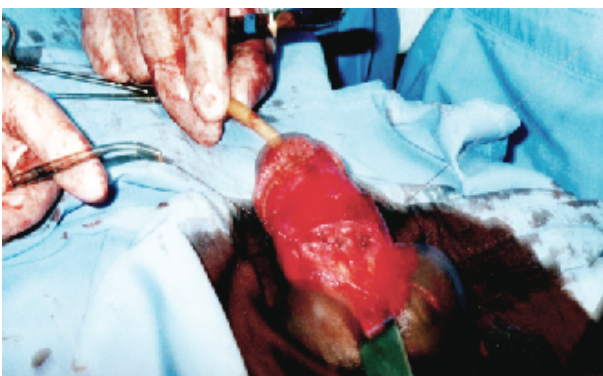

Figure 3: Fracture of the right corpus cavernosum sutured with Vicryl 2.0

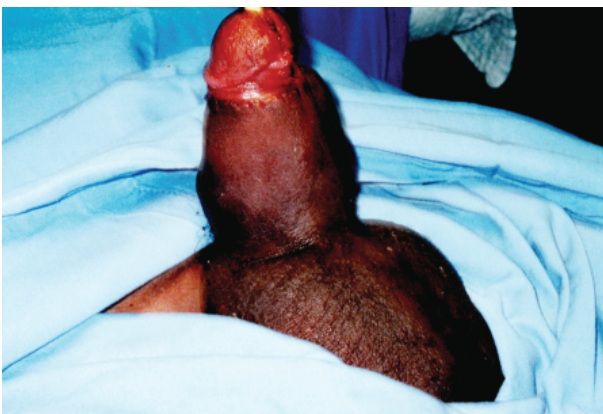

Figure 4: Final aspect of the surgery

was left in until the complete regression of the hematoma upon 7 days when the urinary catheter was finally removed. The authors acknowledge that the ideal catheterization time should have been maximum 48-72 h. However, the delay in the catheter removal was due to the large hematoma that was an exasperating difficulty for the patient to urinate which led the team to arrive at an agreement to the discharge with the catheter to allow for alleviation of the swelling symptoms.

At 6 months follow-up, the patient displayed no evidence of any complications including no micturition problems. The age at which this incidence occurred, compelled the emergency team to contact the relevant children and social protection services. The parents and the child were interviewed on several occasions which confirmed no indications of sexual abuse or any forms of molestation, excluding such principal factors

as pertaining to the clinical case at hand. The patient at the time reported normal penile erectile function with no experience of having had sexual intercourse.

It could potentially be inferred that the occurrence of such incidence is likely to be predicated on nocturnal tumescence transpired as the patient might have “rolled over” on his erect penis in his sleep. Nevertheless, the patient was able to recollect his dream at the night of the incidence and reaffirmed previous occasions in which he had encountered signs of ejaculation during his sleep. Moreover, the assessment team firmly believed that the statement provided by the patient did not encompass manipulation in order to disguise the underlying cause of the given incidence.

## Discussion

Penis fracture is a rare injury that results from trauma to an erect penis. Penile erection leads the tunica albuginea to be stretched and thin as a consequence and therefore liable to be torn in the case of increased intracavernous pressure. The tunica albuginea' thinness is reduced from 2 mm to 0.25 mm, losing its elasticity, which inevitably predisposes the penis to an injury if abnormal forces are applied, for example, an abrupt angulation of the erect penis [5,6]. The most common situation when the above pathogenic mechanism is detected entails sexual intercourse or, less frequently, penis manipulation [1-4]. In addition, stricture might occur in those with a urethral injury. Patients who seek late medical help may recover with or without deformity. The emergency nature of this pathology comes also from the fact that the subsequent deformities from the conservative treatment may necessitate further extensive reconstructive surgery.

A more infrequent scenario of a patient who landed onto an erect penis is described in the study of Dincel and co-workers, who report a case [7]. Hirasawa et al. [8] Outlined the case of a patient who had a penis rupture while rolling over in bed. A rupture occurred in an attempted rape is mentioned by Eke [9]. Furthermore, an additional rare situation that could lead to a fractured penis is a nocturnal unconscious manipulation [10]. We believe that this could also be the mechanism that caused a penile rupture in the case described above.

As previously stated, the patient denied any possible trauma sustained during a conscious mode. In the absence of other factors that could have principally justified the incidence, we postulate that a case of nocturnal unconscious manipulation, as reported by El-Sherif and co-workers [10] was the confirmed diagnostic.

## Conclusion

In summary, fracture of the penis is a rare case as a result of a transverse tear in the tunica albuginea. In these patients, a localized hematoma at the site of the fracture develops. They present with a tender area at the site of the fracture and a possible hematoma with or without difficulty in voiding. The diagnosis is straightforward and confirmed by the history of blunt trauma to the erect penis or abnormal position during coitus. A preponderance of research suggests that such habits change in children under the influence of music videos and video games. Similarly, it is also inferred that children are over-exposed to situations that take the youngsters to a world of fantasy, which renders sexual stimulation an undeniable component [11]. The new behavior and exposition of youngsters facilitate the recurrence of sexual dreams and exacerbated nocturnal manipulation. Therefore, penile fracture as an emergency condition, cannot be excluded from the differential diagnosis, now even at young age.

## Consent

Written informed consent was obtained from the patient for publication of this case report and accompanying images. A copy of the written consent is available for review by the Editor-in-Chief of this journal.

## Competing Interest

The authors declare that they have no competing interests.

## References

1. Godec CJ, Reiser R, Logush AZ (1988) The erect penis-injury prone organ. *J Trauma* 28: 124-126.
2. Fergany AF, Angermeier KW, Montague DK (1999) Review of Cleveland Clinic experience with penile fracture. *Urology* 54: 352-355.
3. Eke N (2002) Fracture of the penis. *Br J Surg* 89: 555-565.
4. Mydlo JH (2001) Surgeon experience with penile fracture. *J Urol* 166: 526-528.
5. Penson DF, Seftel AD, Krane RJ, Frohrib D, Goldstein I (1992) The hemodynamic pathophysiology of impotence following blunt trauma to the erect penis. *J Urol* 148: 1171-1180.
6. Zargooshi J (2000) Penile fracture in Kermanshas, Iran: report of 172 cases. *J Urol* 164: 364-366.
7. Dincel C, Caşkurlu T, Resim S, Bayraktar Z, Taşçi AI, et al. (1998) Fracture of the penis. *Int Urol Nephrol* 30: 761-765.
8. Hirasawa S, Tsuboi N, Abe H, Kawamura N, Kanamori S, et al. (1983) Fracture of the penis: report of 10 cases and review of 231 cases in Japan. *Hinyokika Kiyo* 29: 1047-1052.
9. Eke N (2002) Urological complications of coitus. *BJU Int* 89: 273-277.
10. El-Sherif AE, Dauleh M, Allowneh N, Vijayan P (1991) Management of fracture of the penis in Qatar. *Br J Urol* 68: 622-625.
11. Ferguson CJ, Olson CK (2013) Friends, fun, frustration and fantasy: Child motivations for video game play. *Motivation and Emotion* 37: 154-164.