

# NK-Cell Lymphoma Involving the Parotid Gland: A Rare Case

Merih Onal\*, Gultekin Ovet, Esra Yilmaz and Necat Alatas

Department of Otorhinolaryngology, Konya Education and Training Hospital, Konya, Turkey

\*Corresponding author: Merih Onal, Department of Otorhinolaryngology, Konya Education and Training Hospital, Konya, Turkey, E-mail: [drmerihonal@gmail.com](mailto:drmerihonal@gmail.com)

Received date: 09 Sept 2015; Accepted date: 05 October 2015; Published date: 10 October 2015.

Citation: Onal M, Ovet G, Yilmaz E, Alatas N (2015) NK-Cell Lymphoma Involving the Parotid Gland: A Rare Case. J Surg Open Access 1(2): doi <http://dx.doi.org/10.16966/2470-0991.107>

Copyright: © 2015 Onal M, et al. This is an open-access article distributed under the terms of the Creative Commons Attribution License, which permits unrestricted use, distribution, and reproduction in any medium, provided the original author and source are credited.

## Abstract

Malignancies arising from putative natural killer (NK) cells are recently recognized distinct lymphoma subtype. Clinically, these lymphomas present most commonly as destructive lesions in the nasal cavity and other midline facial structures. Lymphomas of putative NK cells occur primarily in nonnasal areas including skin, gastrointestinal tract, salivary gland, testis and muscle. The molecular mechanisms leading to malignant transformation of NK cells remain undefined but one of the pathogenetic association is EBV infection. Lymphoma infiltration is seen with prominent necrosis and vascular destruction. Although the clinicopathological features of NK cell lymphomas are well defined, the optimal therapy and treatment outcomes are unclear. Unfortunately, the treatment of NK cell lymphoma has been unsatisfactory. Conventional chemotherapy treatment regimens have resulted in very poor complete remission rates and long-term survival. Here we presented an unusual case of NK cell lymphoma involving the parotid gland.

## Introduction

Extranodal NK/T-Cell lymphoma, nasal type (NKTLN) is a disease that mainly affects the nasal cavity and paranasal sinuses [1]. According to the World Health Organization classification, the term 'nasal type' used for diseases that arise in the nasal cavity and extranasal sites [2]. Nasal/nasopharyngeal localization represents 75% of the cases [3]. Extra-nasal affected sites are skin, larynx, testes, gastrointestinal tract and kidneys [1]. Salivary gland lymphomas constitute 2–5% of all salivary gland neoplasms [4]. Most primary salivary gland lymphomas originated from B cell lineage [5]. We report here a rare case, NK/T-Cell lymphoma in parotid gland which was represented with an excellent outcome as a result of chemotherapy.

## Case Report

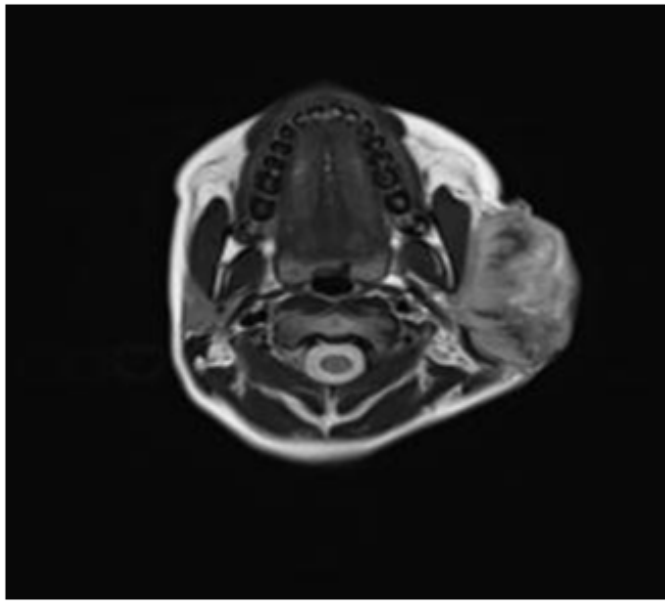
A 14-year-old girl referred to our clinic with a 2 cm mass which was located in the parotid gland region. The swelling had appeared two months ago with discoloration of overlying skin. Oral, nasopharyngeal and laryngeal examination was normal. Total excision of the lesion and biopsy was recommended but her family did not accept the surgery for diagnosis. After six months later, the patient came with a huge lesion extending into posterior cervical region which was gradually increased in size from about 2 × 2 cm to 10 × 10 cm (Figure 1). The lesion was necrotic and crusty. In magnetic resonance imaging, a 9-cm cystic and necrotic mass was observed which was originating from the deep lobe of the parotid gland and infiltrating all of the parotid and the overlying skin (Figures 2 and 3). First biopsy was reported as 'chronic inflammation'. Second biopsy was taken from deeper part. Based on histomorphology, diagnosis of NK/T-Cell lymphoma- nasal type was made. After this diagnosis patient was referred to Oncology Department. She underwent systemic imaging studies for systemic involvement and no any dissemination of the disease was encountered. The patient started on methotrexate, ifosfamide, cyclophosphamide, vincristine, mesna, etoposide and cytarabine chemotherapy by oncologist. The response to the treatment was excellent, at the sixth month of the therapy, the lesion was disappeared almost totally (Figure 4).

## Discussion

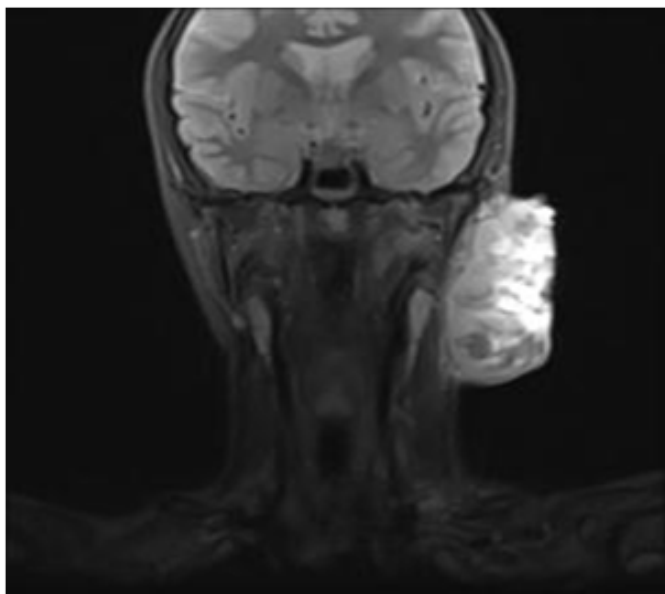
Extranodal non-Hodgkin's lymphomas (NHL) of the head and neck affect Waldeyer's ring, nasopharynx, nasal cavity, paranasal sinuses, thyroid gland, orbit, and salivary glands [6]. Primary parotid lymphomas

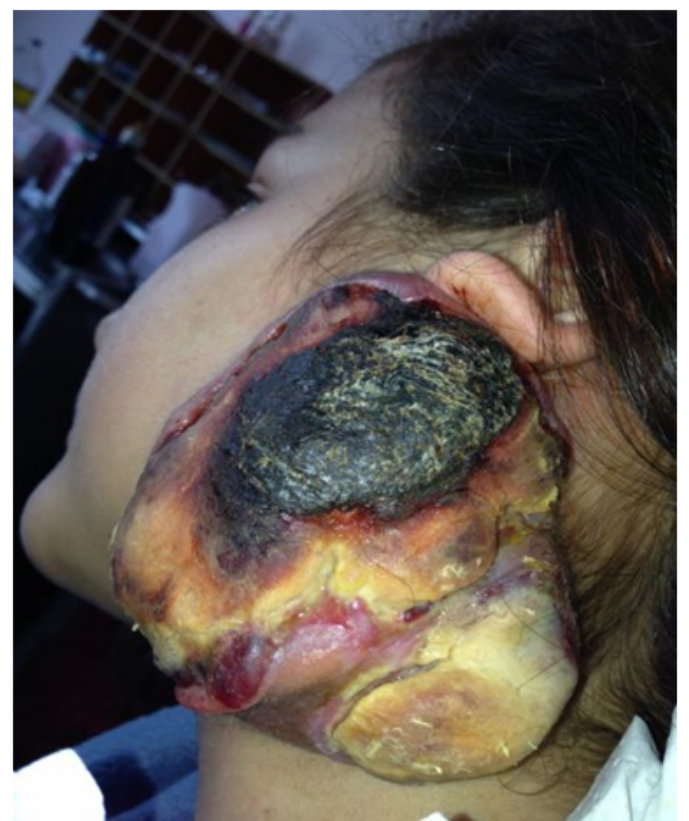

Figure 1: Left parotid gland lesion gradually increased in 6 months

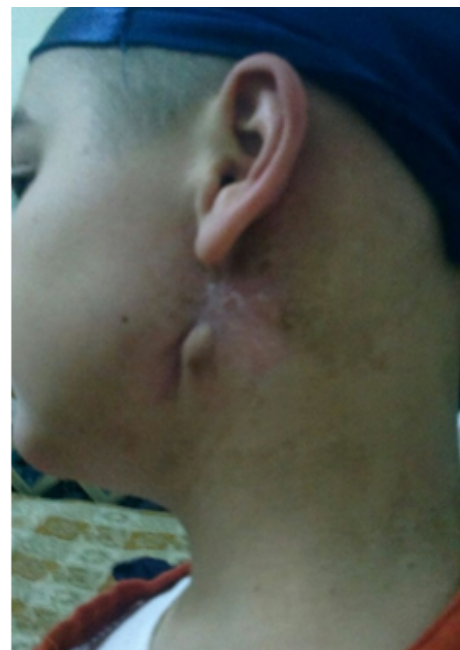

**Figure 2:** Axial section of the parotid lymphoma



**Figure 3:** Coronal section of the parotid lymphoma

account for 0.87% of all NHL cases and 4–5% of all extranodal NHLs [7]. And they may arise from intraparotid lymph nodes or gland itself [8]. Males in the fifth decade are predominantly affected patient group [9]. Our patient is a girl and she is 14 years of age. The majority of all non-Hodgkin parotid lymphomas originated from B-cell lineage including low grade B cell lymphoma of MALT (Mucosa-associated lymphoid tissue), follicular lymphoma and DLBCL (Diffuse Large B Cell Lymphoma) [10]. Lymphomas derived from NK cells are rarely encountered and associated with Epstein-Barr virus (EBV). Nasal NK cell lymphoma is much more common in Asians so a racial predisposition may have a role in the pathogenesis [6]. Most of the salivary gland lymphoma cases present with painless, firm swelling in the gland region [5]. As the biopsy is postponed, significant increase seen in necrosis [1]. In our patient, the disease was diagnosed as NK/T cell lymphoma in the second biopsy. Thus, the earlier biopsy is performed, the greater chance to obtain diagnostic tissue



**Figure 4:** At the sixth month of treatment, the tumor disappeared

sample [11]. Diagnosis of NHL requires evaluation of any other systemic involvement to decide on the therapy. There was no dissemination of the disease in our patient [5]. Currently, there is no standardized treatment protocol for NKTNL [11]. The treatment based on chemotherapy along with locoregional radiotherapy, but the prognosis is poor [12]. Unfortunately, patients with extranodal NK/T-cell lymphoma have a cumulative 5-year survival around 40% [13]. But our patient's prognosis seems to be great for the present.

### Conclusion

Parotid gland lymphomas clinically indistinguishable from other benign or malignant lesions. Definitive diagnosis may be postponed by the patient with being late to seek a medical advice or by the doctor with non-helpful imaging modalities [5]. The extranasal disease has a poor clinical outcome hence new treatment modalities should be considered [3].

### References

1. Chiatton CS (2015) Extranodal nasal type NK/T-cell lymphoma. *Rev Bras de Hematol Hemoter (Impresso)* 2: 26-29.
2. Jaccard A, Petit B, Girault S, Suarez F, Gressin R, et al. (2009) Lasparaginase- based treatment of 15 western patients with extranodal NK/T-cell lymphoma and leukemia and a review of the literature. *Ann Oncol* 20: 110-6.
3. Mahuad CV, Bilbao ER, Garate GM, Repáraz M, Olmo M, et al. (2013) Primary NK/T cell lymphoma nasal type of the colon. *Rare Tumors* 5: e9.
4. Cheuk W, Chan JKC (2007) Salivary gland tumours. In: Fletcher CDM (ed). *Diagnostic stopathology of tumours* (3rd ed). Churchill livingstone, London, UK, 239–325.
5. Gupta D, Gahlot GPS, Rana V, Jagani R, Davendra Swarup D (2014) Primary aggressive non-Hodgkin lymphoma of the parotid gland in a young individual: A case report. *Int J Case Rep Ima* 5: 377–381.
6. Furukawa M, Suzuki H, Tohmiya Y, Matsuura K, Takahashi E, et al. (2003) Natural Killer Cell Lymphoma of the Parotid Gland. *ORL J Otorhinolaryngol Relat Spec* 65: 219–222.

7. Roh JL, Huh J, Suh C (2008) Primary non-Hodgkin lymphomas of the major salivary glands. *J Surg Oncol* 97: 35–39.
8. Barnes L, Eveson JW, Reichart P, Sidransky D (2005) Tumours of the salivary glands. World Health Organisation-Classification of Tumours, Pathology and Genetics of Head and Neck Tumours, IARC Press, Lyon 5: 209–81.
9. Kwong YL (2005) Natural killer-cell malignancies: diagnosis and treatment. *Leukemia* 19: 2186–2194.
10. Borovecki A, Korac P, Ventura RA, Perisa MM, Banham AH, et al. (2007) MALT1, BCL10 and FOXP1 in salivary gland mucosa-associated lymphoid tissue lymphomas. *Pathol Int* 57: 47–51.
11. Jaffe ES, Chan JK, Su IJ, Frizzera G, Mori S, et al. (1996) Report of the workshop on nasal and related extranodal angiocentric T/Natural Killer cell lymphomas. Definitions, differential diagnosis, and epidemiology. *Am J Surg Pathol* 20: 103-11.
12. Miller TP, Dahlberg S, Cassady JR, Adelstein DJ, Spier CM, et al. (1998) Chemotherapy alone compared with chemotherapy plus radiotherapy for localized intermediate- and high-grade non-Hodgkin's lymphoma. *N Engl J Med* 339: 21–26.
13. Ng SB, Selvarajan V, Huang G, Zhou J, Feldman AL, et al. (2011) Activated oncogenic pathways and therapeutic targets in extranodal nasal-type NK/T cell lymphoma revealed by gene expression profiling. *J Pathol* 223: 496-510.