

## Methylprednisolone for Antibiotic-Refractory *Haemophilus influenzae* Infection

Masafumi Seki<sup>1\*</sup>, Nozomi Oikawa<sup>1,2</sup>, Maya Hariu<sup>1,2</sup> and Yuji Watanabe<sup>1,2</sup>

<sup>1</sup>Division of Infectious Diseases and Infection Control, Tohoku Medical and Pharmaceutical University Hospital, Sendai, Miyagi, Japan

<sup>2</sup>Laboratory for Clinical Microbiology, Tohoku Medical and Pharmaceutical University Hospital, Sendai, Miyagi, Japan

\*Corresponding author: Masafumi Seki, Division of Infectious Diseases and Infection Control, Tohoku Medical and Pharmaceutical University Hospital, Sendai, Miyagi, Japan, E-mail: [seki@hosp.tohokumpu.ac.jp](mailto:seki@hosp.tohokumpu.ac.jp)

Received date: 07 Jan 2017; Accepted date: 05 Feb 2017; Published date: 10 Feb 2017.

Citation: Seki M, Oikawa N, Hariu M, Watanabe Y (2017) Methylprednisolone for Antibiotic-Refractory *Haemophilus influenzae* Infection. J Infect Pulm Dis 3(1): doi <http://dx.doi.org/10.16966/2470-3176.121>

Copyright: © 2017 Seki M, et al. This is an open-access article distributed under the terms of the Creative Commons Attribution License, which permits unrestricted use, distribution, and reproduction in any medium, provided the original author and source are credited.

### Abstract

A 72-year-old febrile man was diagnosed as pneumonia, for which he was given oral tosufloxacin and intravenous ceftriaxone. Although *Haemophilus influenzae* sensitive to fluoroquinolones and ceftriaxone was isolated from his sputum, there was no improvement of his severe cough and fever. Eventually, his symptoms and laboratory data improved after administration of methylprednisolone. These findings suggested that *H. influenzae* induced immunologic mechanisms and was strongly toxic.

**Keywords:** *Haemophilus Influenzae*; Tosufloxacin; Levofloxacin; Ceftriaxone; Methylprednisolone

### Introduction

*Haemophilus influenzae* is a bacteria that can infect people of all ages, with manifestations that range from mild (e.g., ear infection) to severe (e.g., bloodstream infection) [1,2]. This organism frequently colonizes the lower respiratory tract of patients with chronic obstructive pulmonary disease (COPD) and is also associated with acute exacerbation of COPD [3]. It is also an important cause of community-acquired pneumonia in adults. In the 1980s, beta-lactamase-negative, ampicillin-resistant (BLNAR) *H. influenzae* strains were discovered and has increased rapidly in incidence because of overuse of antibiotics, such as cephalosporin [4]. Recently, the prevalence of BLNAR strains has been reported to increase to nearly 50% in Japan [5,6].

In this report, we described a case of *H. influenzae* pneumonia that did not respond to sputum culture-guided antibiotic therapy, but was controlled by methylprednisolone.

### Case report

A 72-year-old man visited our hospital in May 2016 with complaints of productive cough and mild exertional dyspnea for a week. He had no significant past medical history and current intake of medications, but he was a previous smoker.

Physical examination showed chill, but no shock (temperature, 38.7 °C; blood pressure, 120/72 mmHg; heart rate, 86 bpm). His consciousness level was E3V4M5 on the Glasgow Coma Scale, and Coarse crackles and inspiratory rhonchi were heard on the right upper lung field, and his oxygen status was slightly decreased to SpO<sub>2</sub>: 95% at room air. 2 of 5 CURB65 severity items were identified. White blood cell (WBC) count was 8,300/μL (neutrophils 72.3%, eosinophils 1.5%, lymphocytes 16.9%, monocytes 8.8%, and basophils 0.5%). C-reactive protein level was 6.69 mg/dL (Figure 1). Chest X-ray identified infiltration shadows in right upper lung field (Figure 2).

*H. influenzae* was isolated from the sputum, with good drug susceptibilities to 3<sup>rd</sup> generation cephalosporins and fluoroquinolones although our isolated strain was BLNAR which resistant to penicillin

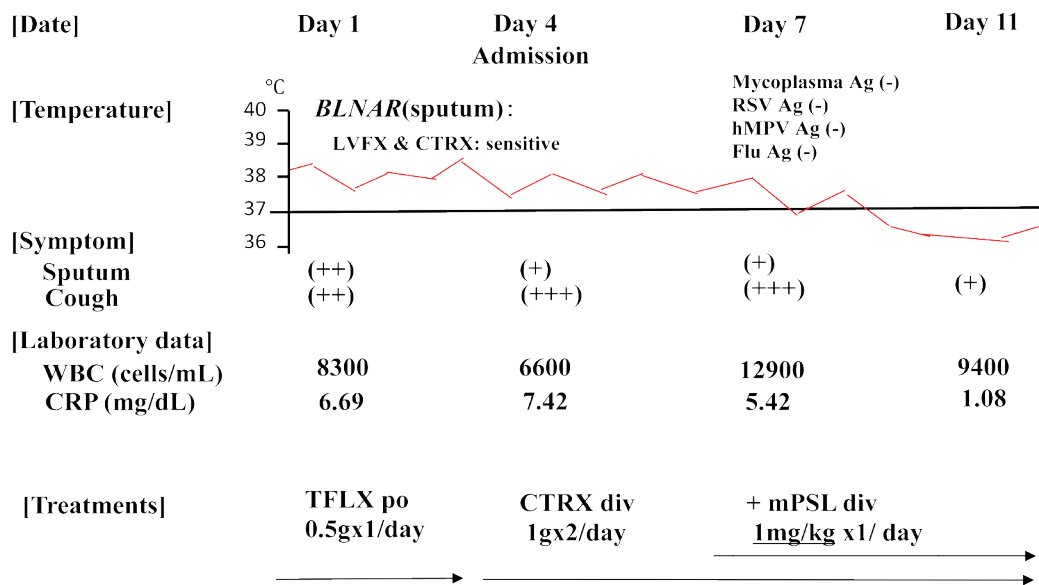
(Figure 1). Phagocytosis of the bacilli by many neutrophils (3+) was observed on microscopy and *H. influenzae* was also semiquantitatively detected at 3+ or >10<sup>7</sup> cfu/mL. No mycobacterial or Pseudomonas species were collected from the sputum.

Oral administration of Tosufloxacin (TFLX) 0.5g/day was started on Day1 at outpatient clinic, however, his fever and cough did not improve within 48 to 72 hours. 3 of 5 CURB65 severity items were identified. He was admitted our hospital at Day 4 and 1 L/min oxygen was started to be administer due to worsening respiratory status (SpO<sub>2</sub>: 94% at room air). *H. influenzae* was not detected from his sputum and blood culture on admission at Day 4. The antibiotic was changed to intravenous ceftriaxone (CTRX), but there was persistence of fever and symptoms, including cough at day 7. The number of WBC in blood was also increased at Day 7. *H. influenzae* and the other bacteria were not detected from his sputum and blood culture at Day 7. Superinfection of some atypical pathogens, such as mycoplasma, respiratory syncytial virus, human metapneumovirus, and influenza virus, was ruled out by negative antigens from his nasal, and pharyngeal swabs.

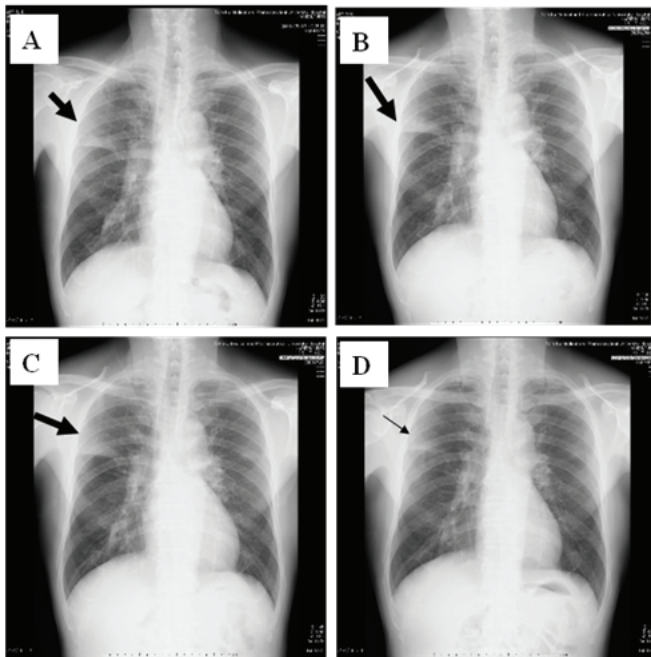
With suspicions of immunologic mechanisms of pneumonia and/or toxicities of antibiotics that caused non-resolving pneumonia, we added methylprednisolone (mPSL) 1mg/kg/day intravenously from Day 7 (Figure 1). After four days (at Day 11), his symptoms, laboratory data, and chest x-ray findings dramatically improved and we stopped mPSL. The patient was discharged and he kept healthy conditions thereafter.

### Discussion

This patient had non-resolving *H. influenzae* pneumonia despite appropriate antibiotic therapy and general management. Usually, fluoroquinolones and 3<sup>rd</sup> generation cephalosporins are effective against *H. influenzae*, which is known as one of the representative pathogens of community-acquired pneumonia. This case showed good drug susceptibility to two major fluoroquinolones: levofloxacin (LVFX) and ciprofloxacin (CPFX) and to a 3<sup>rd</sup> generation cephalosporin (ceftriaxone), which we used because our isolated strain was BLNAR and resistant to penicillin [6].



**Figure 1:** Clinical course of a 72-year-old man with *Haemophilus influenzae* pneumonia. Administration of TFLX and CTRX was not effective, but administration of mPSL improved his condition. TFLX, tosufloxacin; CTRX, ceftriaxone; mPSL, methylprednisolone



**Figure 2:** Chest X-ray changes of the patient. A: Day1, B: Day 4, C: Day 7, and D: Day 11, respectively. The infiltration shadows on right upper field did not changed at Day 1 and Day 4, but worsened at Day 7. However, they were improved at Day 11 after methylprednisolone were used.

We did not specifically investigate the drug susceptibility of the isolated *H. influenzae* to TFLX, but TFLX belongs to the same family of LVFX and CPFV; hence, it was unlikely that *H. influenzae* was resistant to only TFLX, one of the oral fluoroquinolones that also covers anaerobes and atypical pathogens, including mycoplasma and chlamydia, but not mycobacterium [7]. Therefore, TFLX were one of the most recommended antibiotics for BLNAR pneumonia cases in outpatient clinic in Japan [8,9]. However, it is important to note that TFLX had been frequently used for otitis media in Japanese children; as a result, emergence of TFLX-resistant bacteria had

been a recent cause for concern [7,9]. In fact, the grandchild of this patient received TFLX at the otolaryngology clinic and was found to harbor the same bacteria. We did not know the fact at Day 1, but we should take medical information including his grandsons' medications more carefully. Our next goal is to investigate TFLX-susceptibility of the isolate from his grandchild.

Bacterial toxicity might be one of the reasons for ineffective use of antibiotics. *H. influenzae* may be classified as serotypes a to f, depending on the capsular polysaccharide, or as non-typable, if the capsular polysaccharide is undetectable [10]. *H. influenzae* type b (Hib) is the most common cause of an invasive infection. On the other hand, non-typable *H. influenzae* (NTHi) is usually the causative organism of mild mucosal infections, such as bronchopneumonia or otitis media, but it has rarely been identified as the causative pathogen of invasive fatal infections.

As the use of Hib conjugate vaccines has become widespread, the incidence of invasive Hib disease has decreased markedly [11,12]. In contrast, the incidence of invasive infection caused by NTHi has increased; this phenomenon is known as pathogen shift [2]. In our case, the isolated strain was NTHi. In addition, characteristics of *H. influenzae* other than the particular capsular polysaccharide, or its absence, might explain the absence of response to adequate antibiotic therapy in this case. Further studies are needed to validate these hypotheses.

Some immunologic mechanism might have been present in our antibiotic-refractory case. Previously, we reported a case of invasive NTHi respiratory tract infection with a large quantity of neutrophil extracellular traps (NETs) in sputum [2]. NETs are fibrous structures that are released extracellularly from activated neutrophils during inflammation, such as in pneumonia, and rapidly trap and kill pathogens as a first line of immunologic defense [13-16]. However, the function and pathologic roles of NETs have not been fully investigated, and recently, excessive immunologic function was suggested to cause tissue damage when NETs showed extremely amount and extend as 'double-edged sword' [17-19]. Our patient had no history and backgrounds of atopy and immunologic diseases, but mPSL dramatically decreased inflammation, chest X-ray infiltrations, and symptom, including cough. The presence of NETs and excessive neutrophil reaction might have enhanced his severe pneumonia.

We unfortunately did not perform bronchoscope to diagnose the other nonresolving pneumonia, including organizing pneumonia (OP) because the patient refused further examinations. Previously, it was reported that *H influenzae* were isolated 3 of 10 OP with aggregates neutrophils patients, but none of other 4 OP without neutrophils infiltration cases [20]. These results suggested the relationship OP with neutrophils and *H influenzae*. Further analysis about the mechanisms of steroid effectiveness in these cases should be needed.

In steroid use, Torres A et al examined acute use of mPSL 0.5mg/kg BID for 5 days (n=61), and found less treatment failure compare with placebo (n=59) in community-acquired pneumonia suggested with high inflammatory status [21]. The use of corticosteroids is not routine clinical practice and there are no official recommendations yet, but we should investigated additional use of mPSL in severe and/or unresolving pneumonia cases, including our presented patient.

### Conclusion

In conclusion, we presented a case of *H. influenzae* pneumonia that did not improve despite culture-guided antibiotic therapy. Although the possibility of TFLX resistance cannot be ruled out, some other immunologic and toxic mechanisms, such as the presence of NETs, may have also contributed. Further investigation on the pathogenicity and immunopathology of *H. influenzae* infection in this era of widespread Hib vaccine use should be pursued.

**Conflict of Interest:** None

**Acknowledgement:** This work was supported by the Japanese Society for the Promotion of Science Grant-in-Aid for Scientific Research 26461158 (to M.S.).

### References

1. Agrawal A, Murphy TF (2011) *Haemophilus influenzae* infections in the *H. influenzae* type b conjugate vaccine era. *J Clin Microbiol* 49: 3728-3732.
2. Hamaguchi S, Seki M, Yamamoto N, Hirose T, Matsumoto N, et al (2012) Case of invasive nontypable *Haemophilus influenzae* respiratory tract infection with a large quantity of neutrophil extracellular traps in sputum. *J Inflamm Res* 5: 137-140.
3. Finney LJ, Richie A, Pollard E, Johnston SL, Mallia P (2014) Lower airway colonization and inflammatory response in COPD: a focus on *Haemophilus influenzae*. *Int J Chron Obstruct Pulmon Dis* 9: 1119-1132.
4. Murphy TF, Apicella M (1987) Nontypable *Haemophilus influenzae*: a review of clinical aspects, surface antigens, and the human immune response to infection. *Rev Infect Dis* 9: 1-15.
5. Goto H, Shimada K, Ikemoto H, Oguri T, Study Group on Antimicrobial Susceptibility of Pathogens Isolated from Respiratory Infections (2009) Antimicrobial susceptibility of pathogens isolated from more than 10,000 patients with infectious respiratory diseases: a 25-year longitudinal study. *J Infect Chemother* 16: 347-360.
6. Nakamura S, Yanagihara K, Seki M, Izumikawa K, Higashiyama Y (2007) Clinical characteristics of pneumonia caused by beta-lactamase negative ampicillin resistant *Haemophilus influenzae* (BLNAR). *Scand J Infect Dis* 39: 521-524.
7. Shiro H, Sato Y, Toyonaga Y, Hanaki H, Sunakawa K (2015) Nationwide survey of the development of drug resistance in the pediatric field in 2000-2001, 2004, 2007, 2010, and 2012: evaluation of the changes in drug sensitivity of *Haemophilus influenzae* and patients' background factors. *J Infect Chemother* 21: 247-256.
8. Mikasa K, Aoki, N, Aoki Y, et al. (2016) JAID/JSC Guidelines for the Treatment of Respiratory Infectious Diseases: The Japanese Association for Infectious Diseases/Japanese Society of Chemotherapy. *J Infect Chemother* 22: S1-S65.
9. Hasegawa M, Sato Y, Kanayama A, Matsuzaki K, Muraoka H, et al. (2006) Antibacterial activity of tosufloxacin against major organisms detected from patients with respiratory or otorhinological infections: comparison with the results obtained from organisms isolated about 10 years ago. *J Infect Chemother* 12: 152-156.
10. Kroll JS, Booy R (1996) *Haemophilus influenzae*: capsule vaccine and capsulation genetics. *Mol Med Today* 2: 160 -165.
11. Kastrin T, Paragi M., Kolman J, Cizman M, Kraigher A, et al. (2010) Characterisation of invasive *Haemophilus influenzae* isolates in Slovenia, 1993-2008. *Eur J Clin Microbiol Infect Dis* 29: 661-668.
12. Resman F, Ristovski M, Ahl J, Forsgren A, Gilsdorf JR, et al. (2011) Invasive disease caused by *Haemophilus influenzae* in Sweden 1997-2009; evidence of increasing incidence and clinical burden of non-type b strains. *Clin Microbiol Infect* 17: 1638-1645.
13. Brinkmann V, Reichard U, Goosmann C, Fauler B, Uhlemann Y, et al. (2004) Neutrophil extracellular traps kill bacteria. *Science* 303:1532-1535.
14. Hirose T, Hamaguchi S, Matsumoto N, Irisawa T, Seki M, et al. (2014) Presence of neutrophil extracellular traps and citrullinated histone H3 in the bloodstream of critically ill patients. *PLoS One* 9: e111755.
15. Hirose T, Hamaguchi S, Matsumoto N, Irisawa T, Seki M, et al. (2012) Dynamic changes in the expression of neutrophil extracellular traps in acute respiratory infections. *Am J Respir Crit Care Med* 185: 1130-1131.
16. Hamaguchi S, Hirise T, Matsumoto N, Akeda Y, Irisawa T, et al. (2014) Neutrophil extracellular traps in bronchial aspirates: a quantitative analysis. *Eur Respir J* 43: 1709-1718.
17. Kambas K, Mitroulis I, Apostolidou E, Girod A, Chrysanthopoulou A, et al. (2012) Autophagy mediates the delivery of thrombogenic tissue factor to neutrophil extracellular traps in human sepsis. *PLoS One* 7: e45427.
18. Meng W, Paunel-Görgülü A, Flohé S, Witte I, Schädel-Höpfner M, et al. (2012) Deoxyribonuclease is a potential counter regulator of aberrant neutrophil extracellular traps formation after major trauma. *Mediators Inflamm* 2012: 149560.
19. Fuchs TA, Brill A, Duerschmied D, Schatzberg D, Monestier M, et al. (2010) Extracellular DNA traps promote thrombosis. *Proc Natl Acad Sci U S A* 107: 15880-15885.
20. Watanabe K, Harada T, Yoshida M, Shirakusa T, Iwasaki A, et al. (2003) Organizing pneumonia presenting as a solitary nodular shadow on a chest radiograph. *Respiration* 70: 507-514.
21. Torres A, Sibila O, Ferrer M, Polverino E, Menendez R, et al. (2015) Effect of corticosteroids on treatment failure among hospitalized patients with severe community-acquired pneumonia and high inflammatory response: a randomized clinical trial. *JAMA* 313: 677- 686.