

Z-score LORETA Neurofeedback as a Potential Therapy for Patients with Seizures and Refractory Epilepsy

J. Lucas Koberda*, Lauren C. Frey²

¹Director of Tallahassee NeuroBalance Center, Tallahassee, FL 32309, USA

²Associate Professor at Epilepsy Center of University of Colorado, Aurora, CO, USA

*Corresponding author: J. Lucas Koberda, M.D., Ph.D., Director of Tallahassee NeuroBalance Center, Tallahassee, FL 32309, USA, Tel: +850-877-2802; E-mail: JLKoberda@yahoo.com

Received date: 5 January 2015; Accepted date: 26 January 2015; Published date: 31 January 2015.

Citation: Koberda JL and Frey LC (2015) Z-score LORETA Neurofeedback as a Potential Therapy for Patients with Seizures and Refractory Epilepsy. J Neurol Neurobiol, Volume1.1: <http://dx.doi.org/10.16966/2379-7150.101>

Copyright: © 2015 Koberda JL, et al. This is an open-access article distributed under the terms of the Creative Commons Attribution License, which permits unrestricted use, distribution, and reproduction in any medium, provided the original author and source are credited.

Abstract

Approximately 30 % of epilepsy patients are resistant to conventional medical therapy. Therefore, alternative forms of treatment are needed to improve efficiency of these therapeutic regimens. Neurofeedback (NFB) has been becoming recognized as one of the promising therapies improving control of medically refractory epilepsy cases. This multi-case paper describes our experience with LORETA Z-score NFB as a tool for control of patients with seizures.

Keywords: LORETA; Z-score NFB; Epilepsy; Seizures; EEG; QEEG

Introduction

Despite major progress in the treatment of epilepsy, unfortunately approximately 30% of patients are still refractory to medical treatment. Surgical treatment may be an option for some of those patients; however, many patients may not be interested or eligible for surgical therapy. Therefore, there is need to develop alternative treatments which would be able to offer a substantial seizure reduction. Currently, a mainstay of therapy in epilepsy is pharmacotherapy. Unfortunately, approximately 30% of patients with epilepsy do not respond to pharmacological treatment. These patients are classified as medically refractory and other forms of treatment need to be applied in order to reduce frequency of seizures. Dr. Sterman from UCLA initiated NFB experiments which have proven the effectiveness of Sensory Motor Rhythm (SMR) entrainment in epilepsy treatment [1,2]. His protocols were based on the one or two electrode type of NFB, which resulted in significant seizure reduction in drug-refractory patients. Approximately 60% seizure frequency reduction was noted in clinical studies with SMR entrainment [2]. In addition to SMR entrainment technique slow cortical potential (SCP) neurofeedback has been shown to be effective in therapy of epilepsy [3]. Currently, newer NFB protocols are being tested for effectiveness in the treatment of epilepsy including Z-score NFB.

Z-score surface and Low Resolution Electrode-magnetic Tomography Analysis (LORETA) 19-electrode (cap system) was recently introduced to the market (Applied Neurosciences, Inc.). This system has the potential for faster results based on the larger number of electrodes applied to treatment [4]. LORETA-based therapy also enables targeting electrical activity in cortex deeper than that monitored by standard EEG-based NFB. In addition, relatively inexpensive computer software and EEG hardware make this procedure potentially cost-effective. Z-score LORETA NFB is one of the newest forms of NFB where usually 19-electrode simultaneous therapy is conducted in order to normalize aberrant EEG with a goal of reaching a Z-score close to 0 [5-7]. LORETA Z-score NFB was recently shown to be an effective therapy in cognitive dysfunction, dementia, depression/anxiety, autistic spectrum disorder, attention deficit disorder, stroke rehabilitation and chronic pain management [8-14]. A preliminary data coming from our office indicate successful primary and secondary

generalized seizure response to this type of therapy. In this multiple case study results of ten subsequent seizure patients subjected to Z-score LORETA NFB therapy will be presented.

Materials and Methods

Deymed Truscan 32 (Deymed Diagnostic, Payette, ID) EEG equipment was combined with Neuroguide (Applied Neuroscience, Inc.) QEEG/neurofeedback software. The NFB protocol included surface and LORETA (NF1/NFB2) feedback, in an alternating protocol while focusing on a symptom checklist including: attention deficits, concentration problems, executive function problems and short-term memory, word finding difficulty, slow reader. A commercially available computerized neurocognitive testing battery was used for the initial assessment of many patients (NeuroTrax Corp, Bellaire, TX). NeuroTrax Corporation cognitive testing is a computerized neuropsychological assessment where the patient is compared to aged and education matched healthy controls where mean is 100 and the standard deviation is 15. QEEG analysis was completed using commercially available Neuroguide software (Applied Neuroscience, Inc.) and previously recorded 19 channel digital EEG.

Approximately 1-3 minutes of artifact-free eyes closed EEG segments were selected after previously recording EEG with the Deymed, Truscan 32, (Deymed Diagnostic, Payette, ID) and subjected to further QEEG analysis. NFB therapy consisted of 30-minute sessions once or twice a week using auditory and/or visual feedback. One patient who came for therapy from remote location was subjected initially to twice a day NFB therapy.

Results

Table 1 presents a summary of 10 patients who were treated with LORETA and/or surface Z-score NFB in our office.

Since we have not had so far any seizure patients who have not (at least partially) responded to this type of NFB, we can, so far, report 100% effectiveness of this therapy. In the following pages, we will give some more information on the above patients.

S.No	Z-Score NFB of Epilepsy patients
1	18 F with intractable epilepsy with secondary generalization.
2	17 F with intractable primary idiopathic epilepsy with generalization.
3	44 M with frontal epilepsy with generalization-S/P tumor resection.
4	46 F with focal epilepsy and intermittent generalization and cognitive dysfunction-S/P tumor resection.
5	16 F with intractable absence epilepsy with cognitive problems.
6	59 M with intractable generalized epilepsy and cognitive problems (ETOH).
7	18 M with Autistic spectrum and intractable partial complex epilepsy.
8	23 M with Autism and frequent generalized seizures.
9	28 F pharmacist with frequent intractable generalized seizures.
10	19 M with well controlled generalized epilepsy on valproate desiring discontinuation of medication.

Table 1: Summary of patients suffering from seizures

Case 1

18 year old female high school senior (from CA), whose seizures started at age 11, sometimes proceeded by eye blinking episodes. Her current medications included Keppra XR 1500 mg daily and Lamictal 150 mg daily. Prior MRI-of the brain was reported to be normal. EEG showed multiple sharps in several locations including P3, P4 T5, T6, O1, O2. Cognitive testing showed low information processing speed and memory (Figure 1). Despite extensive neurological evaluations at UCLA and multiple medications, no seizure reduction was observed. Her mother even reported an increase in seizure numbers with use of anti-epileptic medications. Dr. Barry Sterman was also consulted and SMR NFB was initiated with some seizure reduction noted. However, despite 90-100 sessions of NFB completion seizures were still occurring, but with lower frequency. This patient presented to our office for one week of intensive therapy with Z-score LORETA NFB (twice a day). LORETA imaging showed multiple areas of cortical electrical dysregulations (Figure 2). After completion of 8 NFB sessions longer remission was achieved (approximately 4 months). Further NFB therapy was continued at another location but with much lower frequency (once a week). Since the initiation of Z-score LORETA NFB therapy (approximately 20 months ago) only a few seizures were noted. In addition, marked improvement of cognitive status was found with resultant admission to college and very good grades during the freshmen year (mostly A's).

Case 2

17-year-old female well known to my practice for the last 3 years was diagnosed with primary generalized epilepsy resistant to pharmacological therapy. Her seizures consisted of multiple short lasting confusion episodes with intermittent generalization. Patient was previously on multiple medications including valproic acid, lamotrigine, clonazepam, zonisamide, levetiracetam, topiramate frequently in combination. Unfortunately her medications were also producing side effects including memory problems and drowsiness. Despite multiple adjustments of medications (lately included lamotrigine and zonisamide), patient still had intermittent breakthrough seizures. Patient also reported worsening of her school performance due to seizures and medications side effects.

Patient workup included normal magnetic resonance imaging of the brain. Electroencephalography showed multiple generalized electrographic seizures (Figure 3) in practically every EEG recording (multiple EEG in the past).

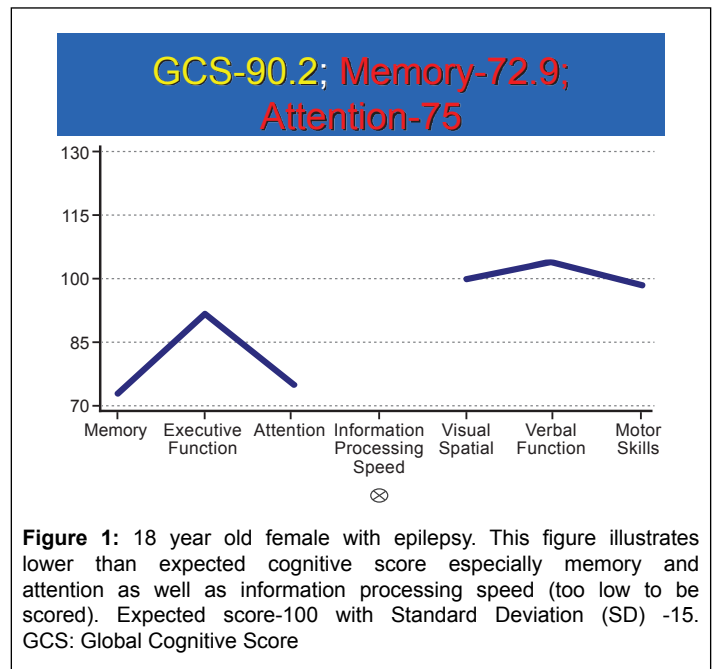


Figure 1: 18 year old female with epilepsy. This figure illustrates lower than expected cognitive score especially memory and attention as well as information processing speed (too low to be scored). Expected score-100 with Standard Deviation (SD) -15. GCS: Global Cognitive Score

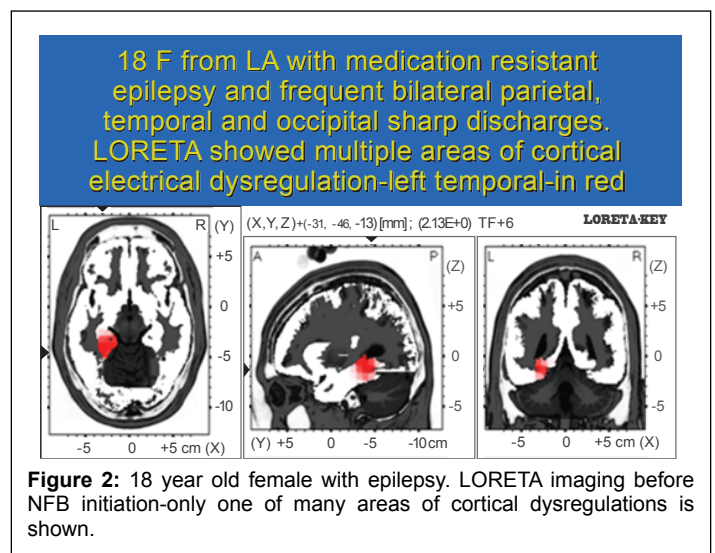


Figure 2: 18 year old female with epilepsy. LORETA imaging before NFB initiation-only one of many areas of cortical dysregulations is shown.

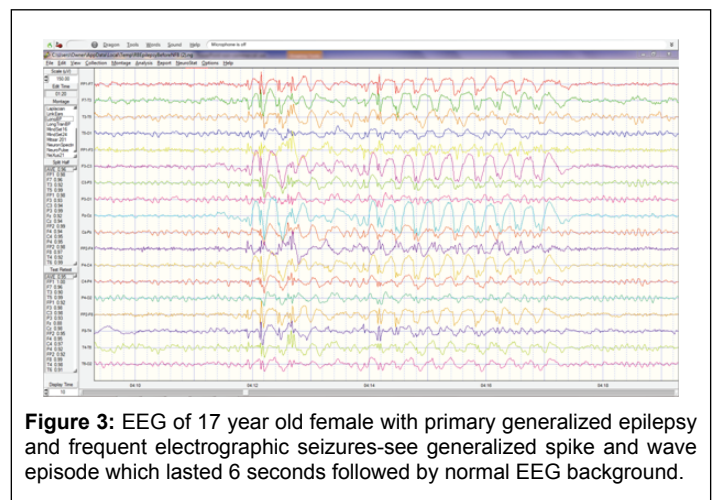


Figure 3: EEG of 17 year old female with primary generalized epilepsy and frequent electrographic seizures-see generalized spike and wave episode which lasted 6 seconds followed by normal EEG background.

Subsequent video EEG telemetry completed at University of Florida epilepsy section confirmed diagnosis of primary generalized epilepsy. Patient's computerized neuropsychological testing (Figure 4) showed global cognitive score of 85 (expected score 100) with deficiency in memory, information processing speed as well as other domains (Figure 4).

Due to her resistance to medications, the patient volunteered to try Z-score NFB focusing on normalization of grossly abnormal electroencephalogram with multiple spike and wave generalized discharges throughout the recording. Approximately 8 out of 10 planned sessions were completed due to the fact that the patient decided to withdraw from NFB therapy. Subsequent follow up visits revealed no more clinical seizures. Two follow up electroencephalograms were completed which showed complete normalization of EEG with no more evidence of electrographic seizures. In addition, quantitative EEG (QEEG) analysis also showed marked improvement (Figure 5 A and 5B) of previously abnormal spectral pattern. This patient remains seizure-free for more than a year since NFB initiation.

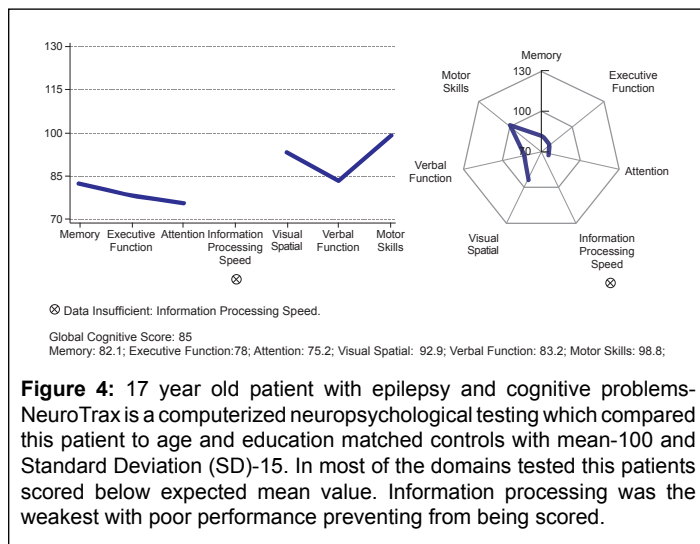


Figure 4: 17 year old patient with epilepsy and cognitive problems- NeuroTrax is a computerized neuropsychological testing which compared this patient to age and education matched controls with mean-100 and Standard Deviation (SD)-15. In most of the domains tested this patients scored below expected mean value. Information processing was the weakest with poor performance preventing from being scored.

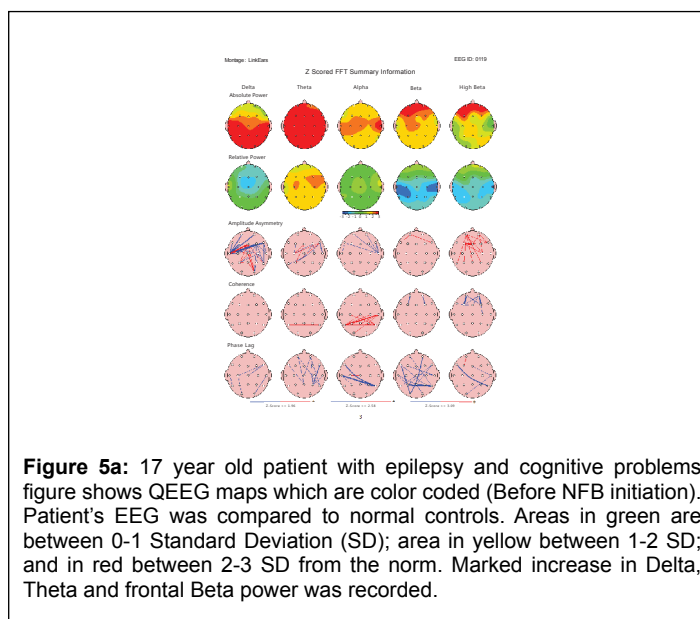


Figure 5a: 17 year old patient with epilepsy and cognitive problems figure shows QEEG maps which are color coded (Before NFB initiation). Patient's EEG was compared to normal controls. Areas in green are between 0-1 Standard Deviation (SD); area in yellow between 1-2 SD; and in red between 2-3 SD from the norm. Marked increase in Delta, Theta and frontal Beta power was recorded.

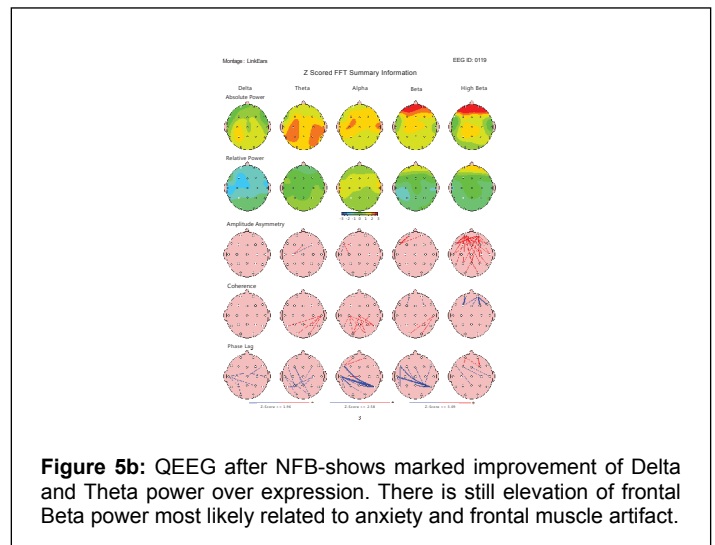


Figure 5b: QEEG after NFB-shows marked improvement of Delta and Theta power over expression. There is still elevation of frontal Beta power most likely related to anxiety and frontal muscle artifact.

The patient also reported improvement in her cognitive function and school performance. Currently, the patient is more than 12 months seizure-free and continues being on lamotrigine and zonisamide.

Case 3

A 40-year-old man noticed his first seizure after experiencing several episodes of the left upper extremity numbness associated with a headache. Generalized seizure was preceded by jerking movements of the left upper extremity. Several more seizures with an identical pattern were subsequently noted by the patient. The patient reported that, on a few occasions, he developed incontinence and tongue biting during a generalized seizure. The patient never experienced similar episodes in the past. The patient reported no other significant medical problems. The patient denied excessive alcohol consumption or smoking. MRI revealed a right frontal central contrast enhancing lesion-likely meningioma. EEG showed right frontal sharp waves, and was diagnosed with secondary generalized seizures.

The patient was started on anti-seizure medication levetiracetam (Keppra) for seizure prevention. Neurosurgical consultation was requested at Johns Hopkins University, and indicated high likelihood of meningioma. Subsequent surgery included frontal craniotomy and tumor resection, which confirmed a diagnosis of meningioma. Unfortunately, despite being on levetiracetam, the patient still experienced breakthrough seizures most likely due to a scar tissue formation after the surgery. Subsequent EEG showed right frontal central breach rhythm with possible epileptiform activity (Figure 6).

Subsequent Z-score NFB (10 sessions) resulted in clinical remission with no further clinical seizures. This patient comes periodically for "refresher" NFB sessions and the dose of Keppra has been gradually reduced from initial 1000 mg twice a day to 750 mg and subsequently 500 mg twice a day. Medication reduction was also associated with subjective improvement (feeling less drowsy) and he continued to be free of seizures. At the time of relocation to another state he has been seizure free for more than 30 months.

Case 4

50 year old female was seen in follow up of hospitalization for seizures due to frontal meningioma- status post tumor resection. Patient

complained of cognitive problems and occasional seizures despite being on Keppra 1000 mg twice a day. Her cognitive computerized testing before NFB showed global cognitive score 81.7 with memory score of 45.4 and information processing speed 66.7. Ten sessions of LORETA Z-score NFB resulted in complete seizure elimination and marked cognitive enhancement with global cognitive score 87, memory increased to 54.9 and higher information processing speed-88.5. This patient has been seizure free for more than 2 years.

Case 5

16 year old female presented for neurological evaluation due to absence seizures, and cognitive and visual integration problems. Due to “bullying” in school, her parents decided to convert her to a home schooling program. Initial computerized cognitive testing showed evidence of memory and information processing speed difficulties. LORETA imaging (Figure 7) revealed several areas of electrical dysregulation including BA-38 and 40, which correlated with her cognitive deficiencies (These areas are involved in regulation of memory, cognition, emotion and visual processing in addition to other functions). EEG showed multiple electrographic seizures (Figure 8). QEEG was also grossly abnormal (Figure 9).

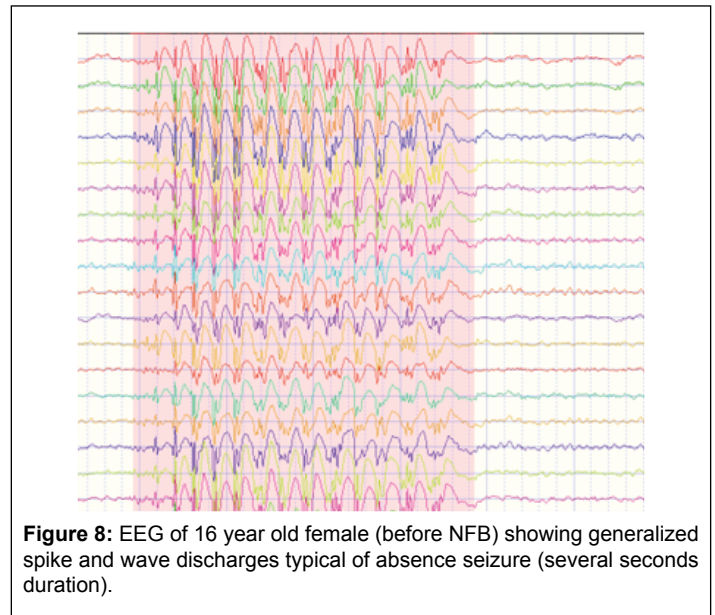


Figure 8: EEG of 16 year old female (before NFB) showing generalized spike and wave discharges typical of absence seizure (several seconds duration).

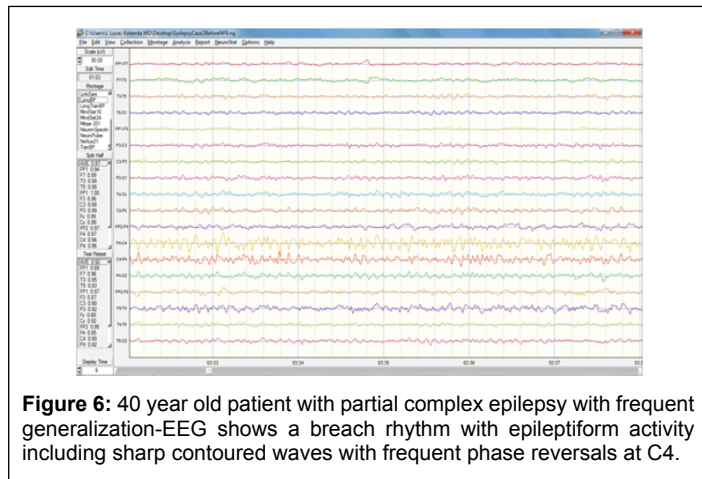
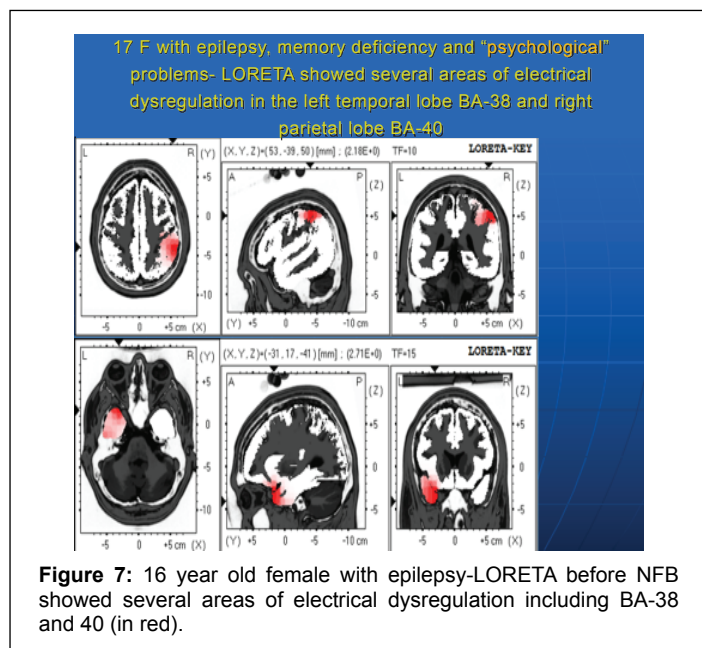


Figure 6: 40 year old patient with partial complex epilepsy with frequent generalization-EEG shows a breach rhythm with epileptiform activity including sharp contoured waves with frequent phase reversals at C4.



17 F with epilepsy, memory deficiency and “psychological” problems- LORETA showed several areas of electrical dysregulation in the left temporal lobe BA-38 and right parietal lobe BA-40

Figure 7: 16 year old female with epilepsy-LORETA before NFB showed several areas of electrical dysregulation including BA-38 and 40 (in red).

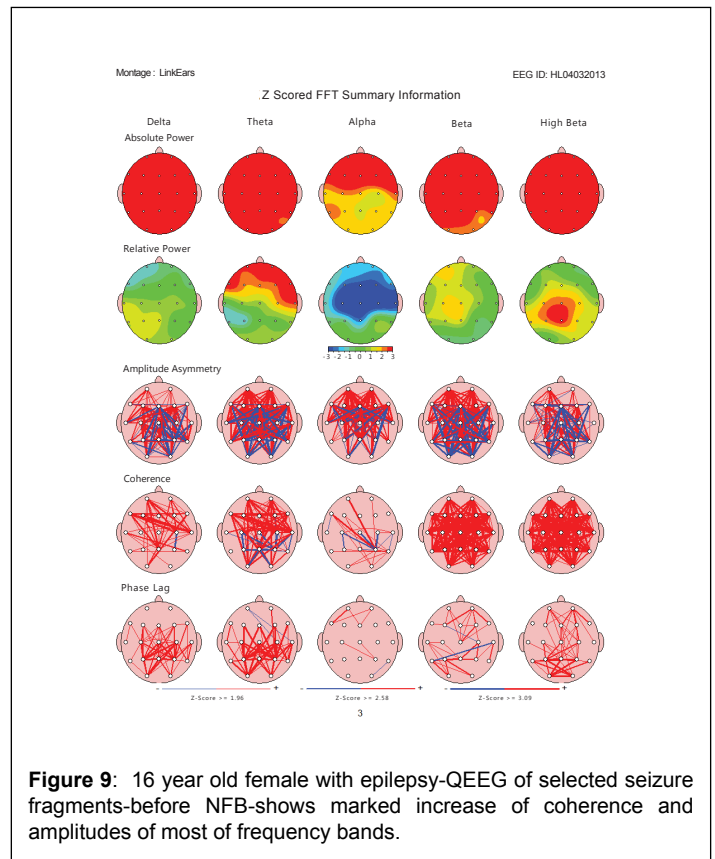


Figure 9: 16 year old female with epilepsy-QEEG of selected seizure fragments-before NFB-shows marked increase of coherence and amplitudes of most of frequency bands.

The patient and her family decided to enroll her in LORETA Z-score NFB, and after just a few NFB sessions a marked reduction of seizures frequency was noted (Figure 10).

After completion of 10 NFB sessions, a complete resolution of electrographic and clinical seizures was noted (Figure 11).

Repeated QEEG also showed marked improvement of previously identified abnormalities including power and coherence (Figure 12).

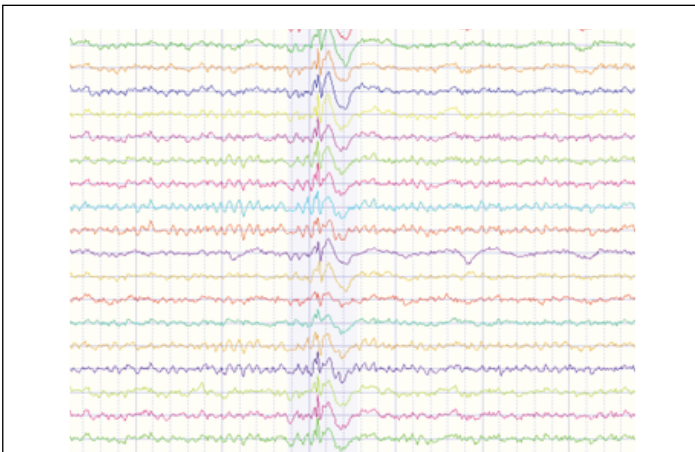


Figure 10: 16 year old with epilepsy-just a few NFB sessions caused marked reduction of frequency and duration of electrographic absence seizures (only 1 second of generalized spike and wave discharge was noted).

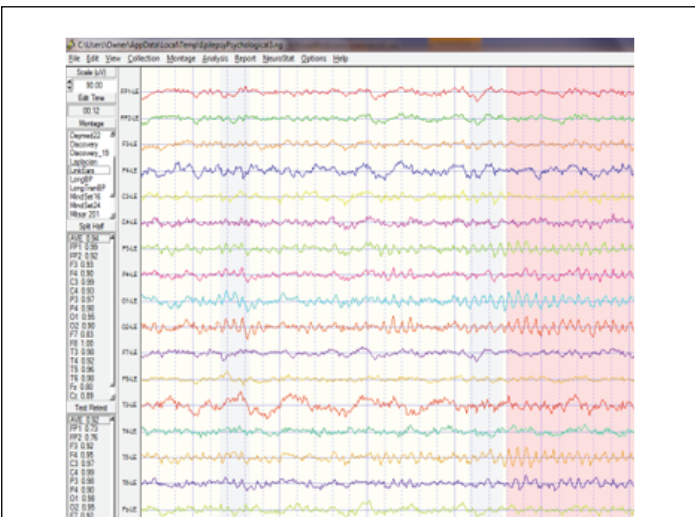


Figure 11: 16 year old female-EEG after 10 sessions of NFB-total resolution of epileptic discharges

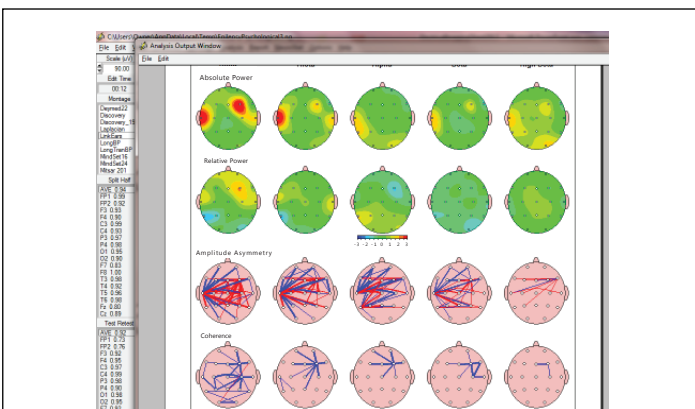


Figure 12: 16 year old female with epilepsy-QEEG after 10 sessions of LORETA Z-score NFB showed almost complete normalization of her QEEG.

Case 6

59 year old male with long standing history of alcohol abuse was diagnosed with multiple recurrent generalized seizures. In addition, cognitive problems and peripheral neuropathy were also identified, likely also related to his long history of alcohol abuse. The patient was placed on medications including Keppra, clonazepam and gabapentin, however, he still had intermittent breakthrough seizures (despite alcohol discontinuation) on a monthly basis. His interictal EEG was normal. After completion of course of Z-score NFB (total of 23 sessions) his seizures subsided and he has been seizure-free for approximately one year. In addition, his wife also reported an improvement of his cognitive status.

Case 7

18 year old male was diagnosed with high functioning autistic spectrum disorder and frequent partial complex seizures. EEG was read as normal on multiple occasions. Z-score NFB therapy caused 50% seizure frequency reduction and improvement in his cognition; however seizures were not completely eradicated.

Case 8

23 year old male diagnosed with low functioning autistic spectrum disorder characterized as major cognitive dysfunction with aphasia and social interaction problems. In addition, frequent generalized seizures were reported despite valproic acid administration. EEG was read as normal. QEEG showed increase in frontal delta and theta power (Figure 13). After course of LORETA Z-score NFB seizures completely subsided (for more than 24 months), and an improvement in social functioning was noted. Repeated QEEG also showed an improvement of previously overexpressed beta and theta power (Figure 14).

Case 9

A 25 year old pharmacist was complaining of frequent generalized seizures especially in the morning on awakening. Multiple EEGs were normal, as well as EEG telemetry completed at University of Florida. Her brain MRI was also normal. Seizures continued despite use of multiple anti-convulsant medications including Keppra 1000 mg twice a day, Topamax 200 mg twice a day and subsequently Vimpat 150 twice a day.

After a course of Z-score LORETA NFB (total of 18 sessions) the seizures subsided and all seizure medications were gradually discontinued.

Case 10

A 19 year old male was diagnosed with probable juvenile myoclonic epilepsy with frequent generalization, which was well controlled on Depakote. His interictal EEG was normal. Patient was interested in discontinuation of medication with help of NFB therapy. During the course of Z-score LORETA NFB, Depakote was gradually discontinued. Patient was seizure free for approximately six months after which intermittent myoclonic jerks started reoccurring. Patient elected to be back on his anti-epileptic medication due to fear of losing driving privileges.

Discussion and Conclusions

Analysis of 10 seizure patients from our clinic subjected to Surface/LOTERA Z-score NFB showed marked clinical improvement in all patients (and in some cases also showed an electrographic improvement), including long lasting clinical remissions or seizure frequency reduction regardless of type of epilepsy.

Many patients reported marked improvement after only 2-5 sessions of LORETA NFB.

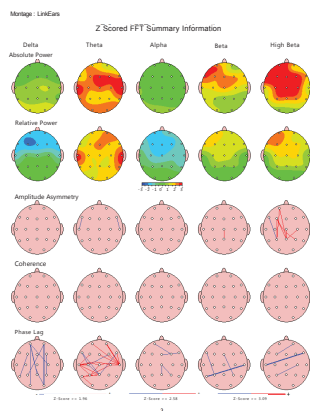


Figure 13: QEEG of 23 year old autistic male-before initiation of NFB. Markedly increased frontal beta power was recorded as well as frontal and temporal theta power.

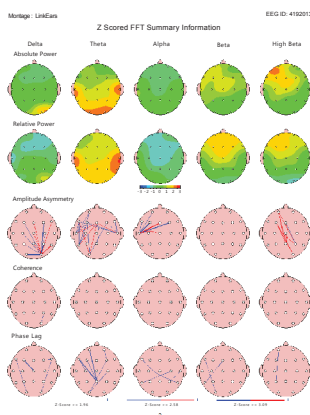


Figure 14: QEEG of 23 year old autistic male-after completion of the course of NFB-marked reduction of previously over expressed beta and theta power is noted.

Most of the patients reported some cognitive improvement, which could have been related to NFB in addition to seizure reduction.

The minimum frequency of NFB was once per week, however more frequent NFB sessions are likely to give more benefits.

The above cases illustrate the great potential of LORETA Z-score NFB as a therapy for a variety of seizures types including primary generalized and secondary generalized epilepsy. Since this paper presents an uncontrolled case series further controlled studies will be needed to best

determine true effectiveness of this therapy. There is also possibility that this type of therapy may also be effective for non-epileptogenic seizures as previously reported using standard 1-2 electrode NFB technique [15].

References

1. Sterman MB, Egner T (2006) Foundation and practice of neurofeedback for the treatment of epilepsy. *Appl Psychophysiol Biofeedback* 31: 21-35.
2. Sterman MB (2010) Biofeedback in the treatment of epilepsy. *Cleve Clin J Med* 3: S60-67.
3. Strehl U, Birkle SM, Wörz S, Kotchoubey B (2014) Sustained reduction of seizures in patients with intractable epilepsy after self-regulation training of slow cortical potentials-10 years after. *Front Hum Neurosci* 8: 604.
4. Koberda JL, Moses A, Koberda P, Koberda L (2012) Comparison of the Effectiveness of Z-Score Surface/LORETA 19-Electrodes Neurofeedback to Standard 1-Electrode Neurofeedback. *J of Neurotherapy* 4: 302.
5. Koberda JL, Moses A, Koberda L, Koberda P (2012) Cognitive Enhancement Using 19-electrode Z-score Neurofeedback. *J Neurotherapy* 3: 224-230.
6. Thatcher RW (2010) LORETA-Z-Score Biofeedback. *Neuroconnections*, December 9-13.
7. Thatcher RW (2013) Latest Developments in Live Z-Score Training: Symptom Check List, Phase Reset, and Loreta Z-Score Biofeedback. Version of record first published: 26 Feb. *J. of Neurotherapy*.
8. Koberda JL (2012) Autistic Spectrum Disorder (ASD) as a Potential Target of Z-score LORETA Neurofeedback. *Neuroconnection- winter 2012*, edition (ISNR) 24-25.
9. Koberda JL, Koberda P, Bienkiewicz A, Moses A, Koberda L (2013) Pain Management Using 19-Electrode Z-Score LORETA Neurofeedback. *Journal of Neurotherapy*, 17: 179-190.
10. Koberda JL ((2014)) Z-score LORETA Neurofeedback as a Potential Rehabilitation Modality in Patients with CVA. *J Neurol Stroke* 2014 1: 00029.
11. Koberda JL (2014) Z-score LORETA Neurofeedback as a Potential Therapy in Cognitive Dysfunction and Dementia. *J Psychology and Clinical Psychiatry*.
12. Koberda JL, Paula Koberda, Andrew Moses, Jessica Winslow, Andrew Bienkiewicz, et al. (2014) Z-score LORETA Neurofeedback as a potential therapy of ADHD–Summer-Special Edition-Biofeedback Magazine-2014.
13. Koberda, JL (2015) Z-score LORETA Neurofeedback as a Potential Therapy in Depression/Anxiety and Cognitive Dysfunction in “Z Score Neurofeedback: Clinical Applications”. Editors-Thatcher, RE and Lubar, JF-Academic Press, San Diego, CA.
14. Koberda, JL (2015) LORETA Z-score Neurofeedback in Chronic Pain and Headaches-in “Z Score Neurofeedback: Clinical Applications”. Editors-Thatcher, RE and Lubar, JF-Academic Press, San Diego, CA.
15. Swingle PG (1998) Neurofeedback treatment of pseudoseizure disorder. *Biol Psychiatry*. 1998 44: 1196-1199.