

Cervical Spinal Cord Compression and Demyelinating Neuropathy Complicating Neurofibromatosis Type 1: About A Case

Patrice Ntenga^{1*}, Kabulo K², Fogang YF¹, Bugeme M¹, Soumaila Boubacar¹, Salaheddine M¹, Aboubacar Nahantchi A¹, Cisse O¹, Diagne NS¹, Toure K^{1,3}, Ndiaye M¹ and Ndiaye MM¹

¹Neurological Clinic of the National Teaching Hospital-FANN, Dakar, Senegal

²Department of Neurosurgery, university of Zimbabwe, harare, Zimbabwe

³Department of Preventive Medicine and Public health, Faculty of Medicine, Pharmacy and Odontostomatology, University of Cheikh Anta Diop, Dakar, Senegal

*Corresponding author: Patrice Ntenga, Neurological Clinic of the National Teaching Hospital-FANN, Dakar, Senegal, Tel: +221 70 527 00 95; E-mail: drndaytenga@yahoo.fr

Received date: 27 Feb 2017; Accepted date: 25 Jul 2017; Published date: 01 Aug 2017.

Citation: Ntenga P, Kabulo K, Fogang YF, Bugeme M, Boubacar S, et al. (2017) Cervical Spinal Cord Compression and Demyelinating Neuropathy Complicating Neurofibromatosis Type 1: About A Case. *J Neurol Neurobiol* 3(2): doi <http://dx.doi.org/10.16966/2379-7150.141>

Copyright: © 2017 Ntenga P, et al. This is an open-access article distributed under the terms of the Creative Commons Attribution License, which permits unrestricted use, distribution, and reproduction in any medium, provided the original author and source are credited.

Abstract

Neurofibromatosis (NF) is a term that has been applied to a variety of related syndromes, characterized by neuroectodermal tumors arising within multiple organs and autosomal-dominant inheritance. At least 8 different clinical phenotypes of neurofibromatosis have been identified and are linked to at least two genetic disorders. Neurofibromatosis type I (NF-1) is the most common type of the disease accounting 90% of the cases. Spinal neurofibromas may cause neurologic symptoms by compressing the spinal cord or spinal roots within the foraminal spaces.

We report the case of 64 year old male, Senegalese; admitted in June 2016 at the Neurological Clinic of the National Teaching Hospital-FANN, Dakar-Senegal for a syndrome of slow cervical spinal cord compression and a demyelinating neuropathy of both upper and lower limbs. MRI confirmed compression of the sixth and seventh cervical spine segment, which is in favor of a neurofibroma and electroneuromyography showed sensory and motor impairment with slowing of conduction velocities and latencies. The progression was fatal with death after 34 days.

Keywords: Cervical spinal cord compression, Neurofibromatosis type1; Demyelinating neuropathy

Introduction

Neurofibromatosis (NF) is a term that has been applied to a variety of related syndromes, characterized by neuroectodermal tumors arising within multiple organs and autosomal-dominant inheritance. At least 8 different clinical phenotypes of neurofibromatosis have been identified and are linked to at least two genetic disorders. Neurofibromatosis type I (NF-1) is the most common type of the disease accounting 90% of the cases, and is characterized by multiple café-au-lait spots and the occurrence of neurofibromas along peripheral nerves [1].

Neurofibromatosis type 1(NF1) is a common human genetic disease with an incidence of about 1 in 2500-3300 [2].

It is transmitted in the autosomal dominant mode, its gene has been identified on chromosome 17 (17q11.2) [3]. It is usually caused by a mutation in the NF1 gene but about 5-10% of the cases is the result of a micro deletion in 17q11.2 [4]. The prevalence of clinically diagnosed neurofibromatosis1 varies from 1/2000 to 1/5000 in most population studies [5]. NF1 is a multi-visceral disease that affects more than one million people worldwide (more than 80000 in the US) [6].

Neurofibromas can be localized to the peripheral nervous system, skin and skeleton [7]. The neurological manifestations may arise from tumors and malformations of the nervous system, deformities of the skull and skeleton, or pressure by neurofibromas on the peripheral nerves, spinal nerve roots, and spinal cord [8,9]. Spinal neurofibromas may cause neurologic symptoms by compressing the spinal cord or spinal roots within the foraminal spaces. Symptoms may include pain, numbness,

weakness, or bowel/bladder dysfunction. When arising from the nerve root, the tumor grows in a dumbbell-shaped pattern as it passes through the foramen [10].

Case presentation

A 64 years old, presented to our outpatient department with one month history of progressive weakness of both upper and lower limbs and one week history of inability to walk, Patient reported also several years' history of paresthesia of lower limbs associated with urinary incontinence for which he was being followed at a local clinic, his medical history revealed that he was diagnosed of NF1 via tests performed for fibromas observed on his skin at 16 years of Age. There was no history of fever reported and no family history of neurofibromatosis type 1.

The patient was haemodynamically stable, The physical examination revealed invasive neurofibromas in his body the largest amount being on the trunk and limbs, ranging from a few millimeters to several centimeters in diameter, some of them pedunculated; multiple cafe-au-lait spots with diameter >1,5 cm; axillary and inguinal freckling. There were no visual, auditory or respiratory disorders, power was 3/5 and 1/5 on upper and lower limbs respectively in all muscle groups, reduced sensation bilaterally. The deep tendon reflexes (DTR) of the upper and lower extremities were brisk (4+), Hoffmann reflex was bilateral positive, and there was also dorsal scoliosis.

The performed magnetic resonance imaging (MRI) for spinal cord revealed neurofibromas that filled bilateral neural foramina at lower cervical region and upper thoracic and increased T2 signaling compatible

with myelomalacia causing a thinning of spinal cord at the level of cervicomedullar region and C6-C7 and a dorsal cyphoscoliosis.

An electroneuromyographic examination (ENMG) was carried out and showed demyelinating peripheral neuropathy and slowing of conduction velocities and latencies.

The patient was admitted and had benefited from functional rehabilitation, and symptomatic treatment. A surgical resection of the spinal neurofibroma responsible for cervical spinal cord compression was planned but could not be carried out for economic reasons. Then the patient deteriorated and died 34 days after admission (Figure 1).

Discussion

The association of cervical spinal cord compression and demyelinating polyneuropathy during neurofibromatosis is rare [11]. Our case is about cervical spinal cord compression associated with demyelinating polyneuropathy in neurofibromatosis type 1 patient.

Demyelinating polyneuropathies are rare in NF1, with a frequency of 2.3% in one of the largest series of the literature, a study done by Alain Drouet et al. [12] showed that There was a strong association between the presence of a peripheral neuropathy and large root diffuse neurofibromas ($P < 0.03$) and subcutaneous neurofibromas ($P < 0.0001$) and severe morbidity and mortality of patients with NF1 and peripheral neuropathies was 50%, much higher than what is observed in the general population of patients with NF1, and 100% in patients with the most severe symptoms and electrophysiological changes (demyelination with severe axonal features) [12], it was also reported in a series of Tanya Lehky et al. [13] that Peripheral Neuropathy was observed in 22% of subjects with NF1 and plexiform neurofibromas, most findings suggested an axonal process though two subjects had demyelinating features. Nerve pathology in one subject with demyelinating findings suggested that the presence of tumor may mimic conduction block and demyelination [13].

They settle in a chronic or subacute way. They are pauci- or asymptomatic in the majority of patients, and in some patients the use of the ENMG examination makes it possible to detect them. In our patient, paresthesia of the lower limbs was the only complaint reported over several years followed by weakness an inability to walk. Sensory and motor manifestations of varying severity are also described. Peripheral neuropathy during NF1 is strongly associated with the presence of subcutaneous neurofibromas ($p < 0.0001$) or diffuse radicular neurofibromas ($p < 0.03$). Neuropathy had a demyelinating character. It is found in 78% of the cases of peripheral neuropathy during the NF1, within half there is associated axonal involvement [14].

Malignant degeneration of neurofibromas is not uncommon, and is reported in 22% of patients with NF1 and with peripheral neuropathy. Central neurological complications are usually caused by extra-axial compression by neurofibroma either, 2.5% of cases [15].

Ndoye et al. [16] Reported in their study that cervical spinal cord compression by a neurofibroma was very rare. Over a period of 9 years only 4 cases of progressive spinal cord compression were reported. The mean age of patients was 26.75 years with extremes of 4 and 45 years. The sex ratio of patients was predominantly male (3/4 cases). In this same study it was reported of radiculargia and the appearance of deficiency sign of 3 to 4 months, as well as sphincteric disorders. No history of familial neurofibroma was found [16]. And yet our patient was 64 years old and male. The former did not present other nodule sites as described in the world, Lisch nodules in 95% of cases and optic glioma in 10% to 30% of cases [17].

Cognitive disorders and learning difficulties, epileptic seizures and cerebrovascular disorders have been reported in type 1 neurofibromatosis [3].

Our patient had a thoracic scoliosis. This localization corresponds to that described in many literatures, i.e, thoracic, cervical.

The association during NF1 of a peripheral neuropathy, of proximal root neurofibromas of large size constitutes the prototype of NF1 linked to a high morbidity-mortality or, 50%, of the cases as is the case in our patient. The malignant degeneration of neurofibromas, when present, also contributes to the prognosis [14].

At the clinical stage, there is a problem of differential diagnosis with toxic demyelinating neuromyelopathies. However, the highly evocative context of NF1 and the imaging and electrophysiology data support the diagnosis.

Conclusion

Regular neurological follow-up of patients with NF1, with exhaustive neurological examination, is beneficial for the diagnosis and prognosis of ENMG. It is indicated in case of call symptoms or numerous subcutaneous neurofibromas associated peripheral neuropathy.

One of the major areas of focus is the identification of prognostic factors that provide risk assessment for people with NF1-associated medical problems.

References

1. Dimitrova V, Yordanova I, Pavlova V, Valtchev V, Gospodinov D, et al. (2008) A Case of Neurofibromatosis Type 1. *Journal of IMAB - annual proceeding (scientific papers)* 14.
2. Créange A, Zeller J, Rostaing-Rigattieri S, Brugières P, Degos JD, et al (1999) Neurological complications of neurofibromatosis type 1 in adulthood. *Brain* 122: 473-481.
3. Wolkenstein P, Zeller J (1999) Neurofibromatoses. *La pathologie dermatologique en médecine interne* Edition Arnette, 321-326.
4. Vogels A, Fryns JP (2006) Micro délétion et génétique moléculaire: Le phénotype clinique et comportemental, 4-6.
5. Rasmussen SA, JM Friedman JM (2000) NF1 gene and neurofibromatosis 1. Center for Disease control and Prévention, Janvier, Atlanta, GA 30341, USA.
6. Crawford AH, Schorry EK (2006) Neurofibromatosis update. *J Pediatr Orthop* 26: 413-423.
7. Chick G, JY Alnot, JY, Silbermann-Hoffman O (2003) Multiple peripheral nerve tumors: update and review of the literature. *Chir Main* 22: 131-137.
8. Ferner RE (1998) Medical complications in neurofibromatosis 1. In: Upadhyaya M, Cooper DN, eds. *Neurofibromatosis 1: from genotype to phenotype*. BIOS: Oxford 21-22.
9. RE Ferner, RAC Hughes, SM Hall, M Upadhyaya, MR Johnson (2004) Neurofibromatous neuropathy in neurofibromatosis 1 (NF1) *J Med Genet* 41 :837-841.

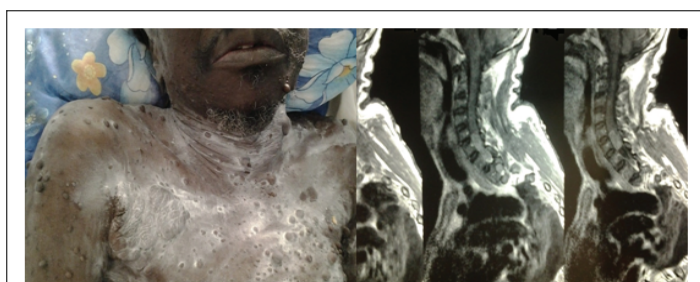


Figure 1: A) Patient's picture showing cutaneous neurofibromas, axillary freckling and café au lait spot; B) MRI cervico thoracic spine showing a spinal neurofibroma compression the cord at the level of C6-C7.

10. jacqueline anderson, David H Gutmann (2015) neurofibromatosis type 1 handbook of clinical neurology, vol. 132 (3rd series) neurocutaneous syndromes MP Islam and E.S. Roach, editors Elsevier.
11. Merker VL, Esparza S, Smith MJ, Stemmer-Rachamimov A, Plotkin SR (2012) Clinical features of schwannomatosis: a retrospective analysis of 87 patients. *Oncologist* 17: 1317-1322.
12. Drouet A, Wolkenstein P, Lefaucheur JP, Pinson S, Combemale P, et al. (2004) Neurofibromatosis 1-associated neuropathies: a reappraisal. *Brain* 127 : 1993-2009.
13. Tanya Lehky, Justin Kwan, Eva Dombi, Andrea aldwin, Srivandana Akshintala, et al. (2014) Peripheral Neuropathy (PN) in individuals with Neurofibromatosis Type 1 (NF1) and Plexiform Neurofibromas (PNF) (P6.093). *Neurology* 82: P6.093.
14. Drouet A, Wolkenstein P, Lefaucheur JP, Pinson S, Combemale P, et al. (2004) Neurofibromatosis 1-associated neuropathies a reappraisal. *Brain* 127 : 1993-2009.
15. Walker L, Thompson D, Easton D, Ponder B, Ponder M, et al. (2006) A prospective study of neurofibromatosis type 1 cancer incidence in the UK. *Br J Cancer* 95: 233-238.
16. Ndoye, et al. (2012) La compression médullaire lente cervicale par un neurofibrome dans le cadre de la maladie de Von recklinghausen à propos de 4 cas, Service de neurochirurgie Centre Hospitalier National et Universitaire de FANN. *Journal Africain de chirurgie*.
17. Listernick R, Charrow J, Greenwald M, Mets M (1994) Natural history of optic pathway tumors in children with neurofibromatosis type 1: a longitudinal study. *J Pediatr* 125: 63-66.