

LORETA Z-score Neurofeedback-Effectiveness in Rehabilitation of Patients Suffering from Traumatic Brain Injury

J Lucas Koberda^{1,2*}

¹Director of Tallahassee NeuroBalance Center, Tallahassee, FL 32309, USA

²CEO-Brain Enhancement, Inc, USA

*Corresponding author: J Lucas Koberda, Director of Tallahassee NeuroBalance Center, Tallahassee, FL 32309, USA, E-mail: JLKoberda@yahoo.com

Received date: 27 August 2015; Accepted date: 7 Sep 2015; Published date: 10 Sep 2015.

Citation: Koberda JL (2015) LORETA Z-score Neurofeedback-Effectiveness in Rehabilitation of Patients Suffering from Traumatic Brain Injury. *J Neurol Neurobiol* 1(4): doi <http://dx.doi.org/10.16966/2379-7150.113>

Copyright: © 2015 Koberda JL. This is an open-access article distributed under the terms of the Creative Commons Attribution License, which permits unrestricted use, distribution, and reproduction in any medium, provided the original author and source are credited.

Abstract

This is a multi-case study involving sixty-seven patients diagnosed with Traumatic Brain Injury (TBI) that were subjected to Z-score neurofeedback (NFB) therapy. Most of the patients were diagnosed with mild TBI and treated within the first year after brain injury. A few patients were diagnosed with more severe TBI and treated after one year or later following their head injury incident. Most of the patients complained of headaches and cognitive problems while some of them also suffered from dizziness and overlapping depression. Those who complained of cognitive problems were subjected to analysis with computerized cognitive testing (NeuroTrax, Inc.) before and after ten sessions of NFB. During the NFB therapy the subjective response from patients was collected in order to discern whether or not there was an improvement of their symptoms. In addition, QEEG maps were completed before each NFB session initiation in order to see an objective improvement of QEEG abnormalities. Subsequent analysis revealed that 59 out of 67 patients (88%) noticed subjective improvement of their symptoms within 10 sessions of NFB therapy, out of which most of them reported an improvement after only 1-3 NFB sessions. 54 patients also had an objective improvement of QEEG maps (80%) manifesting as reduction of excessive beta activity and/or normalization of delta or theta power.

45 patients completed prior and post NFB neurocognitive testing with 34 patients (76%) having significant cognitive enhancement (Global Cognitive Score increased between 3-30 points). These results are very encouraging and indicate high potential of Z-score LORETA NFB rehabilitation of patients suffering from TBI.

Keywords: Neurofeedback; TBI; Z-score; LORETA; EEG; QEEG

Introduction

Despite a relatively high occurrence of TBIs, the available therapies for this condition are limited. Pharmacotherapy, cognitive behavioral therapy, physical therapy, and occupational therapy are frequently employed in the rehabilitation of TBI patients. Neuromodulation represented by neurofeedback (NFB; also called EEG-biofeedback), has been known as a potential therapeutic modality for many years. This type of biofeedback uses real-time displays of EEG to illustrate brain activity and allows us to self-regulate brain EEG activity by diminishing excessive fast or slow waves, which may frequently be seen in TBI patients. Self-regulation of this excessive slow or fast EEG activity has been correlated with reduction of TBI symptoms and clinical recovery. Z-score Low Resolution Electromagnetic Tomography Analysis (LORETA) 19-electrode (cap system) NFB was relatively recently introduced to the market (Applied Neurosciences, Inc.). This system has the potential for faster results based on the larger number of electrodes (scalp sensors) applied during treatment [1]. In Z-Score NFB, a real-time comparison to an age-matched population of healthy subjects is used for data acquisition and therapy [2]. This technology has recently been shown to be an effective therapy of many neuropsychiatric disorders including: chronic pain, depression, stroke rehabilitation and cognitive dysfunction [3-5]. The potential advantage of neuromodulation over pharmacotherapy is its ability of bypassing the digestive tract to interact almost directly with dysregulated neurons. This creates the opportunity to potentially lower side effects while increasing therapeutic gains.

Our clinical research has previously demonstrated the efficiency of LORETA Z-score NFB in patients suffering from epilepsy, Alzheimer's

disease, autistic spectrum disorders, attention deficit hyperactivity disorder and other neuropsychiatric conditions [6-10]. Recently published papers [11,12] reported the marked improvements of cognitive function, MRI abnormalities, and quality of life of TBI patients subjected to NFB. Post-NFB findings have shown significant increase in cortical grey matter (GM) volumes and fractional anisotropy (FA) of cortical white matter (WM) tracts [11]. Similar MRI findings were previously reported by the University of Montreal group [13] in a randomized study performed on normal volunteers. Other groups have also reported beneficial effects of NFB in therapy of TBI patients [12,14].

Data coming from my clinic presented in this paper indicate a very promising response of TBI patients to LORETA Z-score NFB therapy.

Materials and Methods

Sixty-seven patients diagnosed with TBI were involved in this study with ages ranging between 16 and 71. Patients were seen in an outpatient setting of a neurological clinic. Most of the patients analyzed were seen under a motor vehicle accident policy or worker's compensation (WC) with only a minority of them seen under commercial health insurance or self-pay basis. The majority of patients were diagnosed with mTBI and seen within a few months since the date of injury. However, a few patients were seen in my clinic and subjected to NFB therapy as far as four years since the initial injury. In addition, some of the patients were diagnosed with severe TBI and required prolonged hospitalization and rehabilitation before a neurofeedback initiation. Most of them presented with a typical constellation of symptoms including headaches, memory and cognitive problems, depression and dizziness. After neurological consultation, patients were usually subjected to EEG/QEEG testing and

computerized cognitive testing (NeuroTrax, Inc.). Subsequently patients were given about ten NFB sessions with a frequency of once or twice per week - sometimes daily. However, minority of patients were subjected to more NFB therapy if they improved after 10 sessions and had a desire to continue therapy to further diminish their symptoms. After 10 NFB sessions, follow up NeuroTrax cognitive testing was conducted in order to see if any cognitive improvement was noted. At the same time, a follow up EEG/QEEG was completed and compared to pre-NFB testing in order to see if any correction of previously identified QEEG abnormalities was found. Additionally, patient subjective response (if any improvement was noted) to NFB was recorded.

Deymed Truscan 32 (Deymed Diagnostic, Payette, ID) EEG equipment was combined with Neuroguide QEEG/NFB (Applied Neuroscience, Inc.) software. The NFB protocol included surface and LORETA (NF1/NF2) feedback, in an alternating protocol while focusing on a symptom checklist including: attention, concentration problems, executive function problems and short-term memory, headaches, depression and anxiety. A commercially available computerized neurocognitive testing battery was used for the initial and follow up assessments of most of the patients (NeuroTrax Corp, Bellaire, TX). Neurotrax Corporation cognitive testing is a computerized neuropsychological assessment where the patient is compared to age and education matched healthy controls where mean is 100 and the standard deviation is 15. QEEG analysis was completed using commercially available Neuroguide software (Applied Neuroscience, Inc.) and previously recorded 19 channel digital EEG.

Approximately 1-3 minutes of artifact-free eyes closed EEG segments were selected after previously recording EEG with the Deymed, Truscan 32, (Deymed Diagnostic, Payette, ID) and subjected to further QEEG analysis. NFB therapy consisted of 30-minute sessions once or twice a week (or daily) using auditory and/or visual feedback.

To localize deeper cortical sources of scalp EEG activity, a low resolution electromagnetic tomography analysis (LORETA) [15] was employed.

Results

Sixty-seven patients diagnosed with prior TBI were enrolled in this study. Out of 67 patients, 59 (88%) patients reported subjective improvement of their symptoms within ten NFB sessions. However, most of these patients noticed improvement of their symptoms within the first three sessions of NFB therapy. Out of 67 patients, 54 (80%) patients were found to have an objective improvement of previously identified QEEG abnormalities within ten NFB sessions. Initial QEEG abnormalities frequently identified in TBI patients included excessive delta and/or theta power in frontal and temporal regions, increased frontal and occipital beta power as well as hyper- or hypo-coherence. Only three patients (4%) out of 67 who completed 10 sessions of NFB have not experienced improvement of their symptoms and did not have improvement of their previously identified QEEG abnormalities. Forty-five patients (out of 67 patients) were able to complete pre-and post-NFB computerized cognitive testing. Other TBI patients reported either no cognitive problems or did not complete follow up cognitive testing after 10 NFB sessions. Out of 45 patients, 34 (76%) patients were found to have at least 3 points improvement on global cognitive score (GCS) of Neurotrax, Inc. testing. Thirty (30) patients (67%) out of 45 showed an improvement on cognitive testing (at least 3 points or more) and objective improvement of QEEG and also reported subjective improvement within ten NFB sessions. A few representative cases will be discussed in more detail in order to illustrate results of NFB therapy.

Case 1

A seventeen-year-old male with a history of two mild concussions (last one 2 years ago) and a possible overlapping attention deficit disorder was

seen for consultation. The patient came with his mom from Atlanta for consideration of NFB due to poor high school performance and possible overlapping depression and behavioral problems. His initial computerized cognitive testing (NeuroTrax) showed lower than expected (expected score-100) global cognitive score (GCS)-90.9 (Table 1) with low memory score-89.3, as well as executive function-85.6. After initiation of Z-score LORETA NFB, a subjective improvement of his cognition (feeling sharper) as well as mood improvement was noted. After 10 sessions of NFB, marked improvement of cognitive score was recorded (GCS-101.5). An additional 10 sessions (total of 20 sessions) of NFB increased his GCS to 108.8, which was almost 18 points higher than the first test. The initial QEEG showed an elevated frontal and temporal theta power, as well as frontal alpha and beta power (Figure 1 A). An increased frontal and temporal theta power may be seen in patients with cognitive difficulties including ADD. Elevated frontal alpha is frequently seen in individuals with depression. High frontal beta may be encountered in patients with anxiety. Also, abnormalities in amplitude asymmetry, coherence and phase lag were noted. Additional TBI discriminant analysis showed TBI probability index of 97.5% and TBI severity index of 5.23, confirming evidence of prior concussions. LORETA imaging showed electrical dysregulation of the anterior cingulate and right temporal region-including several Brodmann's areas (BA): BA 20, 24 and 37 (Figures 1 B and 1C).

In addition to cognitive and behavioral improvements, a correction of previously identified QEEG abnormalities was achieved (Figure 2).

Case 2

This is a 33-year-old female who was evaluated in my office after MVA (2.5 years ago) with symptoms of forgetfulness (problems with remembering of names), word finding difficulty, depression and frequent headaches. Symptoms started after being rear-ended with possible short lasting loss of consciousness (LOC). Her work up included normal MRI of the brain. Patient was a former soccer player who represented the US women's soccer national team. Her initial QEEG maps showed increased occipital beta power as well as elevated temporal delta and theta power. In addition, multiple coherence (hypo-coherence) abnormalities were found (Figure 3A).

LORETA imaging showed several Brodmann's Areas (BA) electrical dysregulations in the right temporal lobe including BA 21, 22 and 41 (Figure 3B). The computerized NeuroTrax testing confirmed her existing cognitive problems with lower than expected scores in memory, attention and verbal function and GCS-83.9 (Table 2).

After completion of the first course of NFB therapy (10 sessions) patient reported marked improvement of her symptoms including headache frequency and intensity reduction. Repeated QEEG revealed reduction of temporal delta and theta power as well as excessive occipital beta overexpression (Figure 4). Follow up cognitive testing showed an improvement of her memory, attention and verbal functions (Table 2).

Number of NFB Sessions	0	10	20
Global Cognitive Score	90.9	101.5	108.8
Memory	89.3	86.2	108
Executive Function	85.6	98.5	113.6
Attention	93.7	102.7	112.7
Information Processing Speed	91.7	99.7	105.8
Visual Spatial	107.3	113.9	107.3
Verbal Function	83.2	114.2	112.1
Motor Skills	85.8	95.1	102

Table 1: 17-year-old with prior concussions and ADD. NeuroTrax computerized cognitive testing was completed before NFB initiation (first vertical column from left) and after completion of 10 and 20 NFB sessions (second and third column).

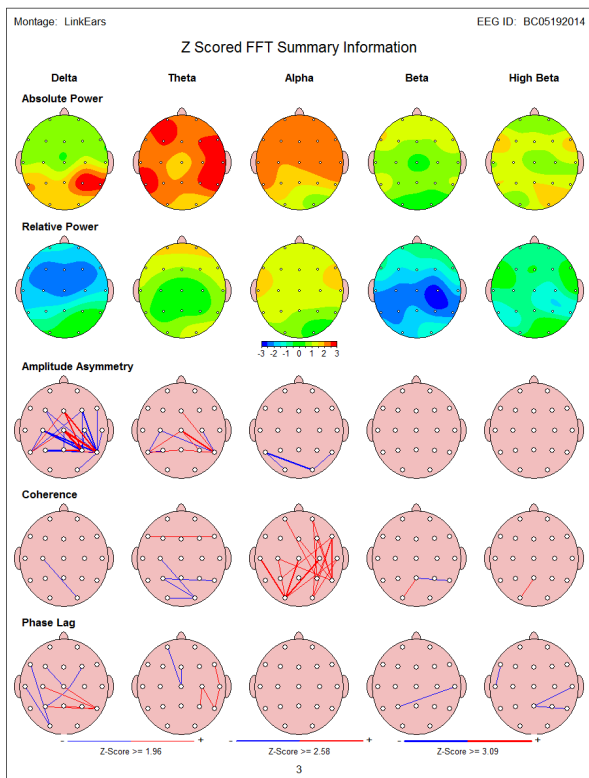


Figure 1 A: 17-year-old with prior concussions and overlapping ADD and behavioral problems - QEEG showed elevated frontal and temporal theta and alpha power (in red), increased frontal beta power and right temporal delta power. Green color shows absolute and relative power within one standard deviation (SD), yellow color within two standard deviations and red color within three SD.

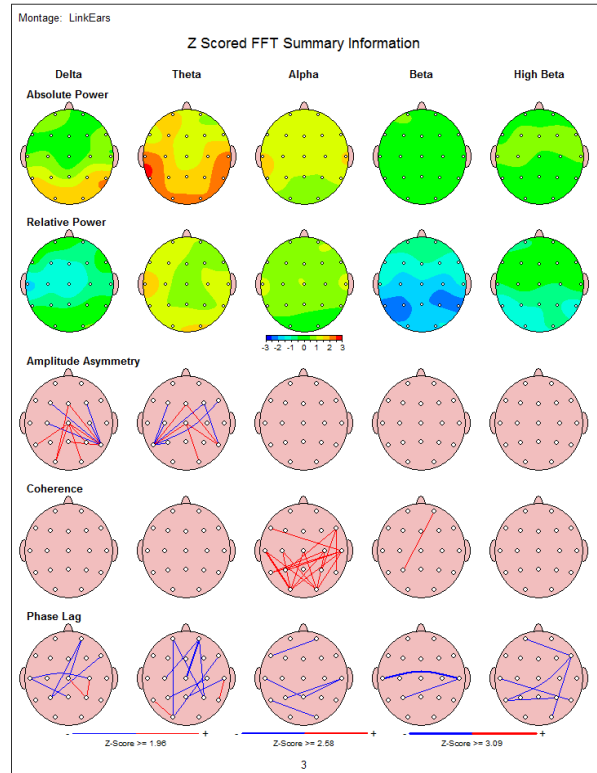


Figure 2: 17-year-old with prior concussions and overlapping ADD and behavioral problems – follow up QEEG (after 10 NFB sessions) showed improvement of previously elevated frontal and temporal theta and alpha power (in red), increased frontal beta power and right temporal delta power. Green color shows absolute and relative power within one standard deviation (SD), yellow color within two standard deviations and red color within three SD.

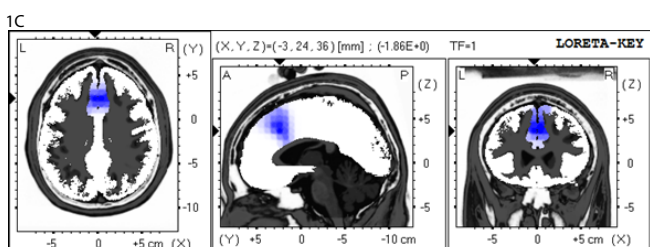
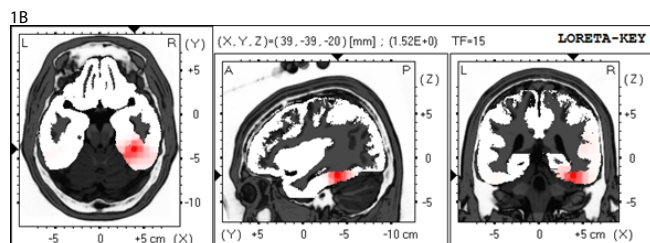


Figure 1 B and C: LORETA of 17-year-old male with prior concussions and ADD-area of electrical dysregulation of the right temporal lobe is shown in red (B) and anterior cingulate in blue (C).

Since this patient was interested in further continuation of NFB therapy, a total of 39 sessions was completed over the period of several months.

Case 3

This is 63-year-old male who was seen in my office one month after being injured by a car. He was a pedestrian - while walking along a street

Global Cognitive Score	83.9	104
Memory	95	101.1
Executive Function	94.1	94
Attention	87.5	100
Information Processing Speed	96.2	108.5
Visual Spatial	100.6	114.2
Verbal Function	25	106.9
Motor Skills	89.2	103

Table 2: 33-year-old female with prior concussion. NeuroTrax computerized cognitive testing was completed before NFB initiation (left vertical column) and after completion of 10 sessions (right vertical column). Red depicts lower cognitive scores.

he was hit and sustained short lasting LOC associated with left knee injury. At the time of the visit in my office he reported having frequent headaches, being depressed, forgetfulness as well as having sleeping problems. QEEG before NFB initiation showed marked increase in frontal and temporal delta and theta power (Figure 5) and coherence abnormalities (hyper-coherence). Additional TBI discriminant analysis confirmed diagnosis of post-concussive syndrome (Figure 6). Pre-NFB NeuroTrax testing showed low cognitive score on most of the domains tested with GCS-74.4.

After 10 sessions of NFB marked improvement of his symptom was reported. In addition follow up QEEG revealed correction of previously identified abnormalities of brain maps (Figure 7).

Repeated NeuroTrax testing after 10 NFB sessions showed marked improvement of cognitive testing especially memory (Table 3) which improved by more than 22 points.

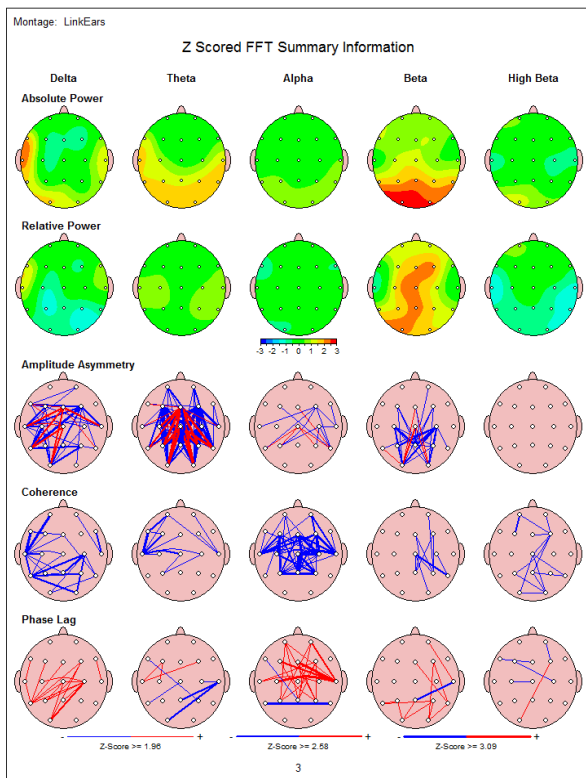


Figure 3 A: 33-year-old female with prior mTBI and subsequent headaches and cognitive problems - QEEG showed elevated temporal delta power as well as increased occipital beta power (in red) and coherence abnormalities. Green color shows absolute and relative power within one standard deviation (SD), yellow color within two standard deviations and red color within three SD.

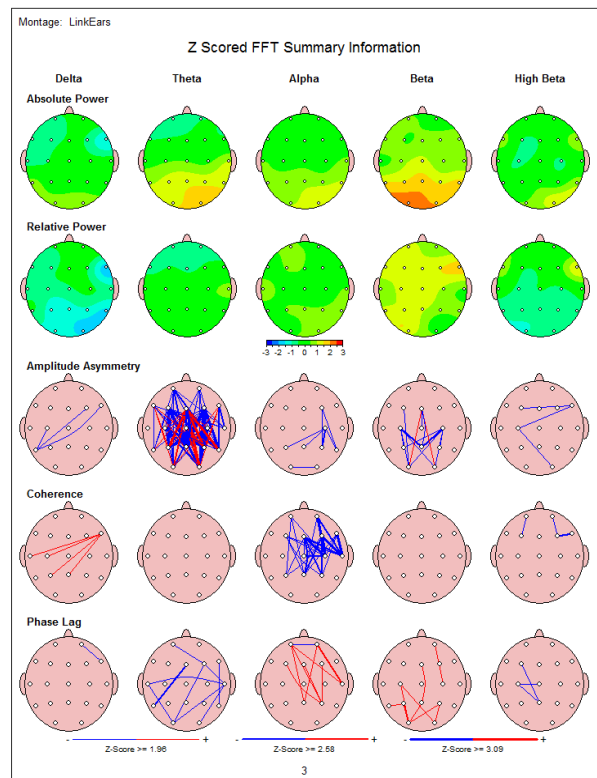


Figure 4: 33-year-old female with prior mTBI and subsequent headaches and cognitive problems - QEEG after 10 sessions of NFB showed improvement of increased occipital beta power (in red) and temporal delta and theta power. Green color shows absolute and relative power within one standard deviation (SD), yellow color within two standard deviations and red color within three SD.

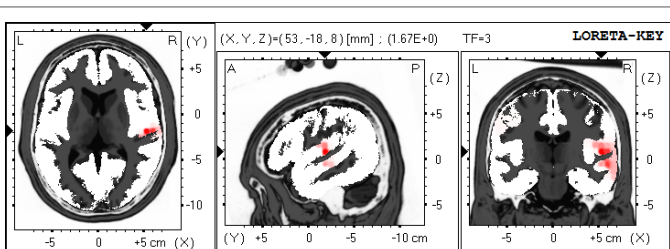


Figure 3 B: LORETA of 33-year-old female with prior mTBI - area of electrical dysregulation of the right temporal lobe is shown in red.

Global Cognitive Score	74.4	91.7
Memory	44.4	66.8
Executive Function	79.6	102.8
Attention	73.7	100
Visual Spatial	94.8	94.8
Verbal Function	64.6	86.1
Motor Skills	89.5	99.5

Table 3: 63-year-old male with prior concussion. NeuroTrax computerized cognitive testing was completed before NFB initiation (left vertical column) and after completion of 10 sessions (right vertical column). Red depicts abnormal low cognitive scores.

Case 4

This is 55-year-old male correctional officer who was seen in my clinic after being assaulted 1 year before by an inmate. During the assault he sustained multiple face and head injuries with LOC. Also, other body areas were involved requiring multiple surgeries including C-spine surgery and orthopedic surgeries on his extremities. His symptoms included headaches and depression with cognitive problems. He was also diagnosed with PTSD. CT and MRI of brain were reported normal. Initial brain maps showed increased frontal and temporal delta and theta power (Figure 8). Before NFB initiation QEEG revealed increase in frontal and temporal delta and theta power and coherence abnormalities (hyper-coherence). Additional TBI discriminant analysis confirmed diagnosis of post-concussive syndrome (Figure 9). Pre-NFB Neurotrax testing showed low cognitive score, especially in attention and executive function (Table 4) and information processing speed (IPS performance too low to be determined). After 10 NFB sessions, in addition to a subjective

improvement, marked increase of IPS (Table 5) and attention was recorded (IPS still low but above the minimal scoring threshold). Ultimately this patient was approved by WC for additional NFB sessions and completed a total of 70 sessions.

In a two year follow up his GCS of NeuroTrax testing was not changed. However, his cognitive score showed mild improvement in attention and more gains in IPS (Table 5). Overall this patient performance was much enhanced despite NFB therapy initiation after 1 year since his injury.

Information Processing Speed - too low to be determined.

Case 5

This is an age 19 male musician who was seen in my office with history of head injury while playing hockey (1 year ago). No LOC was reported but patient became dazed during the injury. MRI of brain was reported normal. Since that time he reported frequent headaches, depression, memory and multi-tasking problems. QEEG before NFB initiation

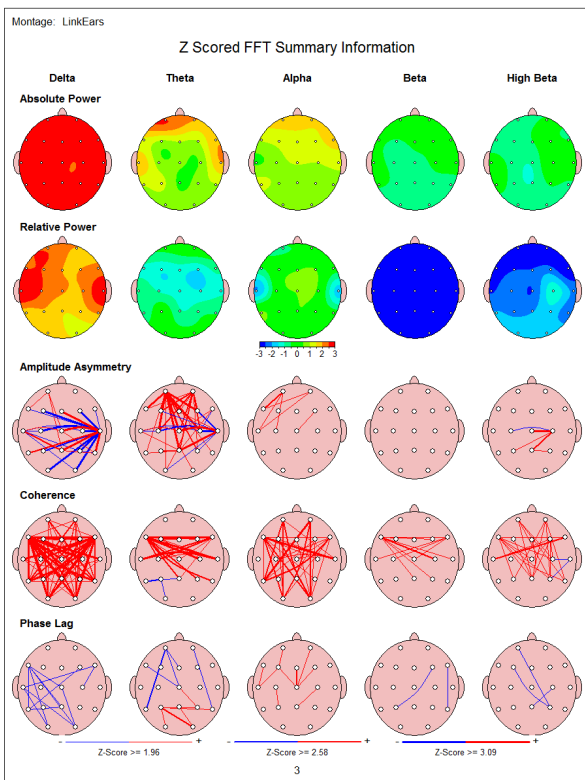


Figure 5: 63-year-old male with prior mTBI and subsequent headaches and cognitive problems - QEEG before NFB initiation showed marked increase in frontal and temporal delta and theta power and coherence abnormalities (hyper-coherence). Green color shows absolute and relative power within one standard deviation (SD), yellow color within two standard deviations and red color within three SD.

Global Cognitive Score	86.3
Memory	90.4
Executive Function	71.6
Attention	40.9
Visual Spatial	123.9
Verbal Function	107.7
Motor Skills	83.4

Table 4: 55-year-old male with prior concussion. NeuroTrax computerized cognitive testing was completed before NFB initiation. Red color depicts abnormal low cognitive scores.

showed marked increase in frontal and occipital beta power (Figure 11) mild coherence and LORETA (Figure 12) abnormalities (hyper-coherence). Pre-NFB NeuroTrax testing showed lower cognitive score in many domains including memory, executive function as well as IPS (Table 6). QEEG after 10 sessions of NFB showed an improvement of previously identified excessive beta power (Figure 13) as well as LORETA abnormalities. In addition to subjective improvement, follow up NeuroTrax testing also showed normalization of cognitive scores (except attention).

Case 6

This is a 21-year-old female college student who was evaluated in my office after severe TBI that she sustained in a MVA 3 years ago. Patient was found in coma and required prolonged hospitalization in ICU and subsequently in a rehabilitation facility. Her initial brain imaging (CT of the brain) showed evidence of left frontal and left temporal hemorrhages. Her subsequent major symptoms included headaches, depression, anxiety and residual cognitive problems. Brain mapping analysis showed (Figure 14) evidence of increased frontal and temporal delta and theta power,

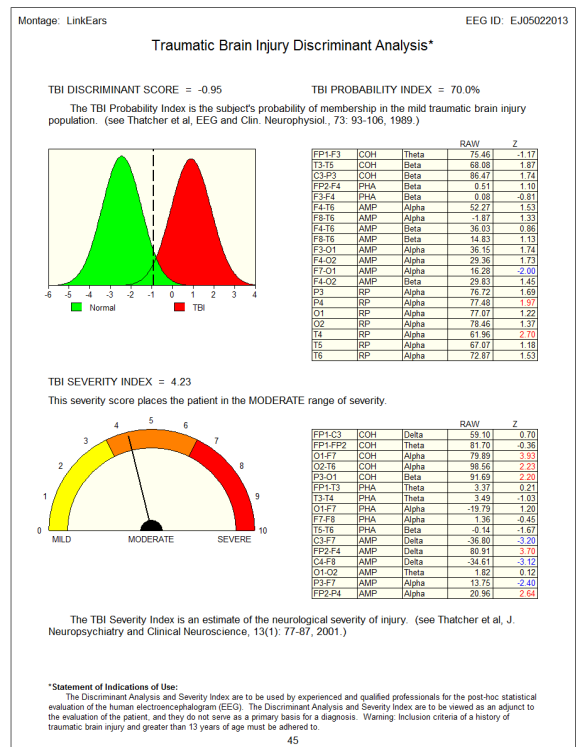


Figure 6: 63-year-old male with prior mTBI and subsequent headaches and cognitive problems – with TBI discriminant analysis which confirmed diagnosis of post-concussive syndrome.

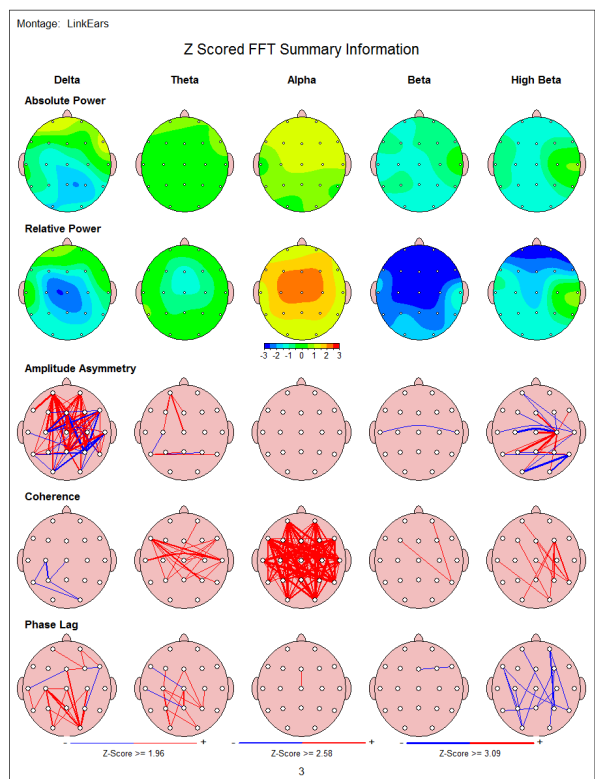


Figure 7: 63-year-old male with prior mTBI and subsequent headaches and cognitive problems - QEEG after 10 sessions of NFB showed improvement of previously identified abnormalities. Green color shows absolute and relative power within one standard deviation (SD), yellow color within two standard deviations and red color within three SD.

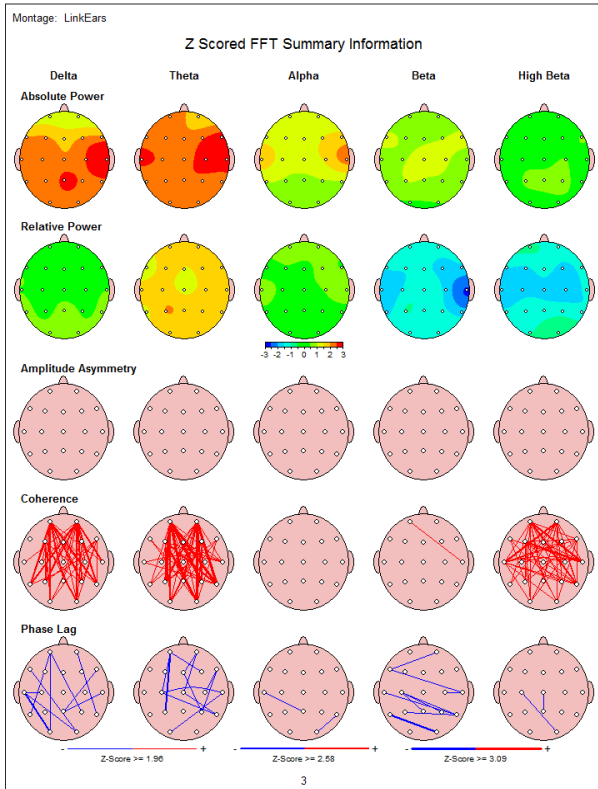


Figure 8: 55-year-old male with prior mTBI and subsequent headaches and cognitive problems - QEEG before NFB initiation showed marked increase in frontal and temporal delta and theta power and coherence abnormalities (hyper-coherence). Green color shows absolute and relative power within one standard deviation (SD), yellow color within two standard deviations and red color within three SD.

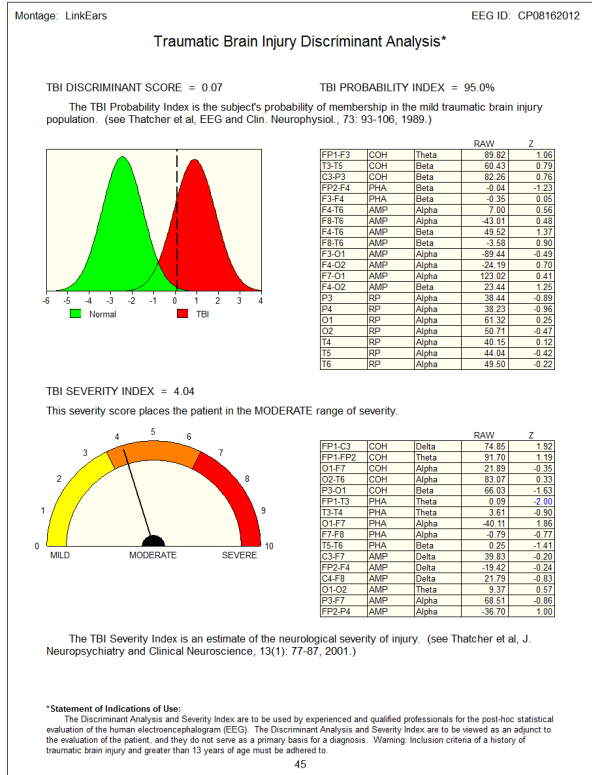


Figure 9: 55-year-old male with prior mTBI and subsequent headaches and cognitive problems – with TBI discriminant analysis which confirmed diagnosis of post-concussive syndrome.

occipital beta power and hyper-coherence. Initial NeuroTrax testing revealed low memory score 66.8 (Table 7). After 10 NFB sessions patient reported an improvement of her symptoms including depression/anxiety, headaches and cognitive performance. Repeated cognitive testing showed normalization of her memory score (Table 7).

QEEG after 10 sessions of NFB showed an improvement of previously identified abnormalities (Table 15).

Discussion

The six selected cases include two patients who were diagnosed with severe TBI that required hospitalization and four cases of mTBI. One of the patients was seen within one month since his injury, however remaining patients were seen for evaluation in my office later on as far as three years since TBI. Only one of the patients diagnosed with the most severe TBI was having abnormal brain imaging (when evaluated shortly after the injury). Remaining patients had normal CT or MRI of the brain, although QEEG analysis was able to confirm prior diagnosis of TBI. In one of our prior papers we have already reported clinical usefulness of QEEG in confirming diagnosis of mild traumatic brain injury (mTBI) [16].

The big majority of patients (88%) reported marked improvement of their TBI-related symptoms within ten NFB sessions, and many of them vocalized improvement after just 1-3 sessions. Many of them were also found to have an objective cognitive improvement documented by computerized cognitive testing. In addition to that, this type of NFB rehabilitation therapy was able to improve most QEEG abnormalities identified in TBI patients during the initial pre-NFB evaluations. The most interesting fact is that patients subjected to therapy with NFB were coming from the most historically “resistant” therapy group consisting of WC and auto injury cases. As we know, many patients seen in these circumstances are less likely to improve clinically due to expected compensation

	Dec-5-12 5:03 PM	Jun-8-15 4:43 PM
Global Cognitive Score	89	89
Memory	92.6	97.3
Executive Function	73.4	78.4
Attention	78.6	64
Information Processing Speed	59.7	75.4
Visual Spatial	123.9	98.6
Verbal Function	107.7	107.7
Motor Skills	87.4	101.7

Table 5: 55-year-old male with prior concussion. NeuroTrax computerized cognitive testing was completed after 10 NFB sessions (left vertical column) and 2 years after NFB therapy (right column). Red values are abnormal low cognitive scores.

Global Cognitive Score	86.9	98.4
Memory	82.5	99.6
Executive Function	84.9	95.5
Attention	86.7	84.6
Information Processing Speed	82.1	92.9
Visual Spatial	120	114.1
Verbal Function	73.6	109.1
Motor Skills	78.6	92.8

Table 6: 19-year-old male with prior concussion. NeuroTrax computerized cognitive testing was completed before NFB sessions (left vertical column) and after 10 sessions of NFB therapy (right column). In red abnormal-low cognitive scores recorded before NFB therapy was initiated.

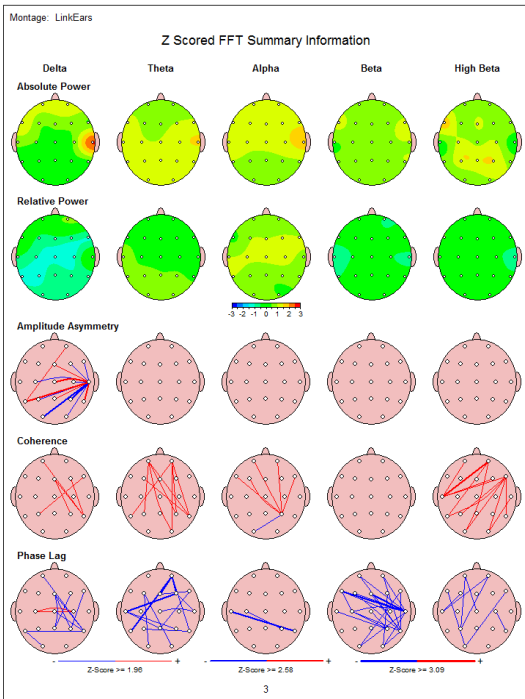


Figure 10: 53-year-old male with prior mTBI and subsequent headaches and cognitive problems – QEEG after 10 sessions of NFB showed improvement of previously identified abnormalities. Green color shows absolute and relative power within one standard deviation (SD), yellow color within two standard deviations and red color within three SD.

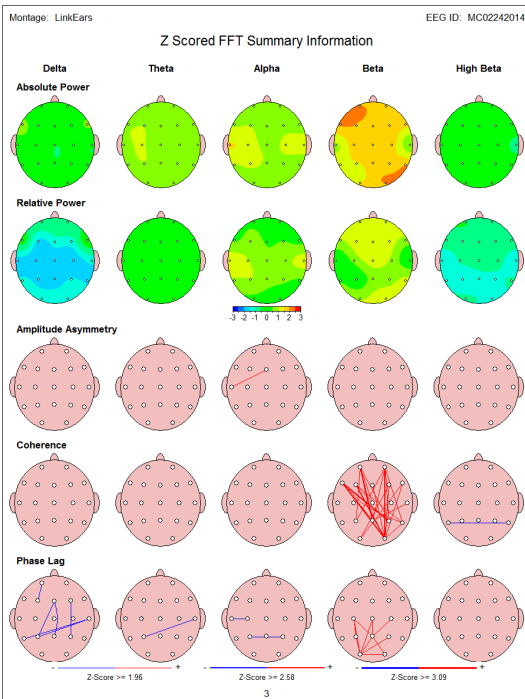


Figure 11: 19-year-old male with prior mTBI and subsequent headaches and cognitive problems - QEEG before NFB initiation showed marked increase in frontal and occipital beta power and mild coherence abnormalities (hyper-coherence). Green color shows absolute and relative power within one standard deviation (SD), yellow color within two standard deviations and red color within three SD.

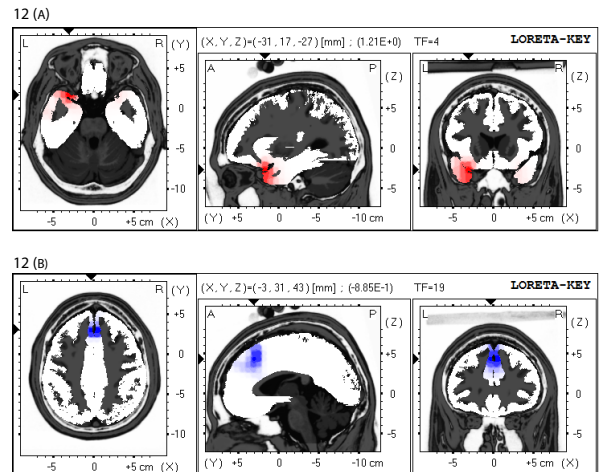


Figure 12 A, B: LORETA of 19-year-old male with prior concussion showed areas of electrical dysregulation of the left temporal lobe (BA-38) is shown in red (A) and anterior cingulate (BA-32) in blue (B).

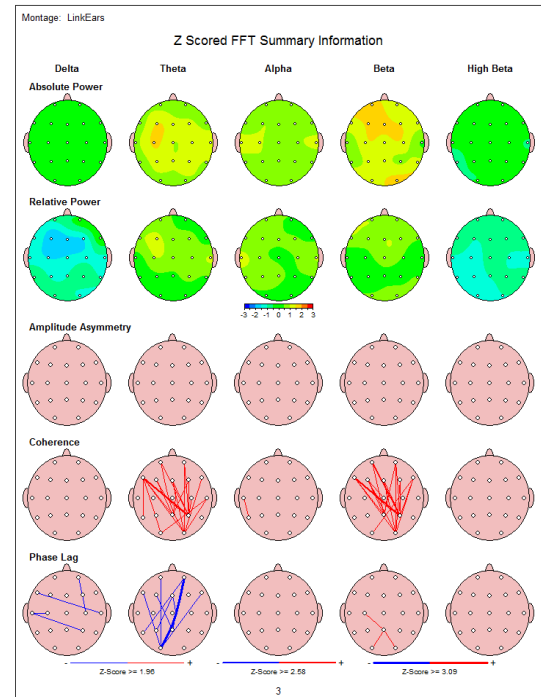


Figure 13: 19-year-old male with prior mTBI and subsequent headaches and cognitive problems - QEEG after 10 sessions of NFB showed improvement of previously identified beta power abnormalities. Green color shows absolute and relative power within one standard deviation (SD), yellow color within two standard deviations and red color within three SD.

(secondary gain) related to their possible permanent disability. Therefore, this therapy may become an interest to many insurance companies since it may be proving to be very cost effective. In addition, LORETA Z-score NFB seems to be effective in a variety of TBI cases regardless of the time of therapy initiation (less or more than one year since injury) and severity of TBI (mild vs. severe).

One of possible drawbacks of this study is a lack of larger control group to compare to the experimental NFB treatment. This was due to lack of

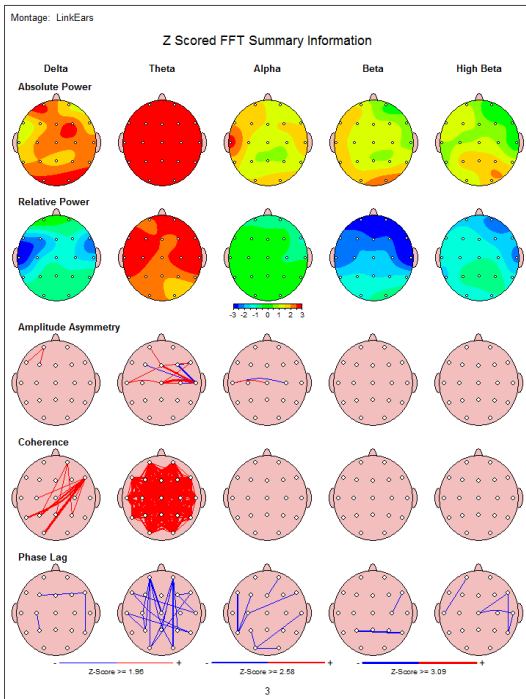


Figure 14: 21-year-old male with prior severe TBI and subsequent headaches and cognitive problems - QEEG before NFB initiation showed marked increase in frontal and temporal delta and theta as well as occipital beta power and coherence abnormalities (hypercoherence). Green color shows absolute and relative power within one standard deviation (SD), yellow color within two standard deviations and red color within three SD.

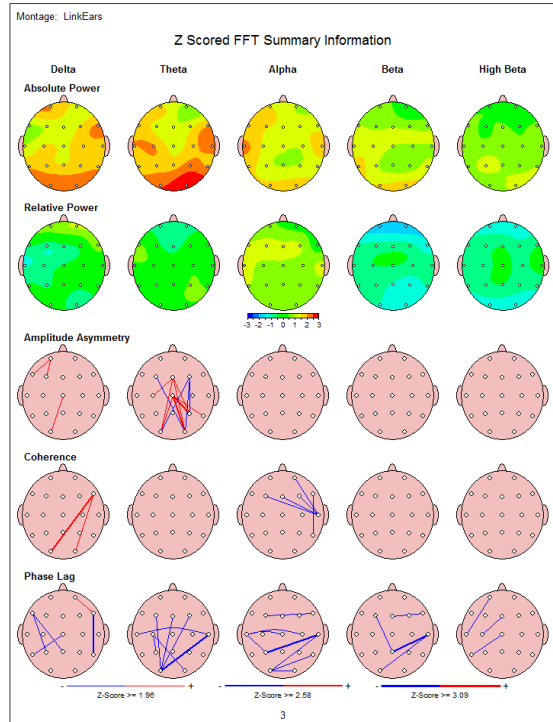


Figure 15: 21-year-old male with prior severe TBI and subsequent headaches and cognitive problems - QEEG after 10 sessions of NFB showed improvement of previously identified abnormalities. Green color shows absolute and relative power within one standard deviation (SD), yellow color within two standard deviations and red color within three SD.

Global Cognitive Score	95.8	100.1
Memory	66.8	102.3
Executive Function	96.5	96.9
Attention	96.1	102
Information Processing Speed	85.6	77.7
Visual Spatial	113.2	106.4
Verbal Function	108.7	108.7
Motor Skills	103.8	106.9

Table 7: 21-year-old female with prior severe TBI. NeuroTrax computerized cognitive testing was completed before NFB sessions (left vertical column) and after 10 sessions of NFB therapy (right column) - See low memory score before NFB therapy below.

appropriate funding but we hope that in the future we will also be able to conduct a controlled study. There are, however, several additional findings confirming effectiveness of NFB therapy. One of them is the fact that one of the TBI patients who was seen in our office but did not enroll in NFB therapy also did not improve on repeated computerized cognitive testing (GCS before NFB was 69.1 and repeated score was 69.8). This patient may be at least partially considered as one of the controls of this therapy. Another two patients who were seen in my office due to previous mTBI but had normal computerized cognitive testing at that time were subsequently seen in my office due to second injury with mTBI symptoms and showed marked deterioration of cognitive testing (First patient-GCS-99 before second injury and GCS-70 after second injury; Second patient GCS-93 before second injury and GCS-73 after second injury). There was also a very small group of patients who did not respond to NFB treatment either subjectively or objectively or no improvement was noted on NeuroTrax testing after completion of therapy. In addition, the manufacturer of

NeuroTrax has extensively tested reliability of this system. To minimize learning across sessions, three alternative forms of NeuroTrax cognitive tests were developed with identical psychometric properties but different items. Equivalence of three alternative forms was demonstrated to have acceptable test-retest reliability coefficients as well as alternative form reliability coefficients.

Preliminary results of this study were presented during the International Society for Neurofeedback and Research (ISNR) 2014 meeting and subsequently published in the abstract form [17]. In summary these therapy results are very encouraging and in the future, a larger placebo controlled study may be beneficial to further document efficiency of this type of NFB in therapy of TBI patients.

References

1. Koberda JL, Moses A, Koberda P, Koberda L (2012) Comparison of the Effectiveness of Z-Score Surface/LORETA 19-Electrodes Neurofeedback to Standard 1-Electrode Neurofeedback. *J Neurotherapy* 4: 302.
2. Thatcher RW (2013) Latest Developments in Live Z-Score Training: Symptom Check List, Phase Reset, and Loreta Z-Score Biofeedback-published: 26 Feb *J Neurotherapy*.
3. Koberda JL, Koberda P, Bienkiewicz A, Moses A, Koberda L (2013) Pain Management Using 19-Electrode Z-Score LORETA Neurofeedback. *J Neurotherapy* 17: 179-190.
4. Koberda JL, Moses A, Koberda L, Koberda P (2012) Cognitive Enhancement Using 19-electrode Z-score Neurofeedback. *J Neurotherapy* 3: 224-230.
5. Koberda JL (2014) Z-score LORETA Neurofeedback as a

- Potential Rehabilitation Modality in Patients with CVA. *J Neurol Stroke* 1: 00029.
6. Koberda JL (2015) Z-score LORETA Neurofeedback as a Potential Therapy in Depression/Anxiety and Cognitive Dysfunction in "Z Score Neurofeedback: Clinical Applications". Editors-Thatcher, RE and Lubar, JF-Academic Press, San Diego, CA.
 7. Frey LC, Koberda, JL (2015) LORETA Z-score neurofeedback in patients with medically-refractory epilepsy. *J Neurol Neurobiol* 1.
 8. Koberda JL (2012) Autistic Spectrum Disorder (ASD) as a Potential Target of Z-score LORETA Neurofeedback. *Neuroconnection- winter 2012, edition (ISNR)*, 24.
 9. Koberda JL (2014) Z-score LORETA Neurofeedback as a Potential Therapy in Cognitive Dysfunction and Dementia. *J Psychology Clinical Psychiatry*.
 10. Koberda JL, Frey LC (2015) Application of Z-score LORETA Neurofeedback in Therapy of Epilepsy. *J Neurol Neurobiol* 1.
 11. Koberda JL, Koberda P, Moses A, Winslow J, Bienkiewicz A, et al. (2014) Z-score LORETA Neurofeedback as a potential therapy of ADHD. *Special Edition-Biofeedback Magazine-summer 2014*.
 12. Munivenkatappa A, Rajeswaran J, Indira Devi B, Bennet N, Upadhyay N (2014) EEG Neurofeedback therapy: Can it attenuate brain changes in TBI? *Neuro Rehabilitation*. 35: 481-484.
 13. Reddy RP, Rajeswaran J, Bhagavatula ID, Kandavel T (2014) Silent Epidemic: The Effects of Neurofeedback on Quality-of-Life. *Indian J Psychol Med* 36: 40-44.
 14. Ghaziri JA, Tucholka V, Larue M, Blanchette-Sylvestre G, Reyburn G, et al. (2013) Neurofeedback Training Induces Changes in White and Gray Matter. *Clin EEG Neurosci* published online March 26.
 15. Duff J (2004) The usefulness of quantitative EEG (QEEG) and neurotherapy in the assessment and treatment of post-concussion syndrome. *Clin EEG Neurosci* 35: 198-209.
 16. Pascual-Marqui RD, Michel CM, Lehmann D (1994) Low resolution electromagnetic tomography: a new method for localizing electrical activity in the brain. *Int J Psychophysiol* 18: 49-65.
 17. Koberda JL (2013) Clinical advantages of quantitative electroencephalogram (QEEG)-electrical neuroimaging application in general neurology practice. *Clin EEG Neurosci* 44: 273-285.
 18. Dwolatzky T, Whitehead V, Doniger GM, Simon ES, Schweiger A, Jaffe D, Chertkow H (2004) Validity of the Mindstreams computerized cognitive battery for mild cognitive impairment. *J Mol Neurosci* 24: 33-44.
 19. Koberda JL, Bienkiewicz A, Koberda L, Koberda P, Moses A, et al. (2014) Accelerated Recovery from Traumatic Brain Injury (TBI) with Z-score Neurofeedback Therapy-presented during the ISNR meeting-San Diego, CA-October 16, 2014-published in *Neuro Regulation* 1: 273-316.