

Pediatric Bladder Neuroblastoma

Besut Daryanto^{1*}, Agung Adhitya¹, Taufiq Nur Budaya¹ and Kenty Wantri²

¹Urology Department, Medical Faculty, Brawijaya University, Malang, Indonesia

²Anatomy Pathology Department, Medical Faculty, Brawijaya University, Dr. Saiful Anwar General Hospital, Malang, Indonesia

*Corresponding author: Besut Daryanto, Urology Department, Medical Faculty of Brawijaya University- Saiful Anwar General Hospital Malang, Indonesia, E-mail: besut.daryanto@yahoo.co.id

Received: 11 Jun, 2018 | Accepted: 18 Jul, 2018 | Published: 24 Jul, 2018

Citation: Daryanto B, Adhitya A, Budaya TN, Wantri K (2018) Pediatric Bladder Neuroblastoma. *Int J Nephrol Kidney Fail* 4(3): dx.doi.org/10.16966/2380-5498.161

Copyright: © 2018 Daryanto B, et al. This is an open-access article distributed under the terms of the Creative Commons Attribution License, which permits unrestricted use, distribution, and reproduction in any medium, provided the original author and source are credited.

Abstract

Bladder cancer is the most common malignancy of the urinary tract and the seventh most common malignancy of men. The peak incidence of bladder cancer is in the sixth decade of life, while they are rarely seen in children, are only 1% of all cases of bladder cancer with 30% of cases in children aged ≤10 years. Transitional cell cancer (TCC) is the most common pathological finding compare with neuroblastoma is an extremely rare. In this case report we reported 8 years old male with bladder neuroblastoma.

Eight years old male, came with painless left flank mass since 3 months and painless intermittent hematuria since 1 month before admission followed by decreasing of renal function test and septic condition. MRI results revealed a malignant solid mass of the bladder with extension from serosa to perivesica accompanied with pelvic lymphadenopathy causing bilateral severe hydronephrosis. Patient had performed bilateral percutaneous nephrostomy (PNS) for urine diversion and trans-urethral resection of bladder tumor (TURBT) with the histopathology result from immunohistochemical staining is neuroblastoma. Patient had been planned for cystectomy followed by chemotherapy and radiation but patient died during admission due to septic shock.

Keywords: Pediatric neuroblastoma; Bladder malignancy; TURBT; Percutaneous nephrostomy

Introduction

Bladder cancer is the most common malignancy of the urinary tract and the seventh most common malignancy of men. The peak incidence of bladder cancer is in the sixth decade of life, while they are rarely seen in children, are only 1% of all cases of bladder cancer with 30% of cases in children aged ≤10 years. Transitional cell cancer (TCC) is the most common pathological finding compare with neuroblastoma is an extremely rare [1-3].

There has an anatomical difference in children such as smooth tissues of the pelvis are immature, the bladders are more intra abdominally and immature prostate may also present difficulties in the management of the bladder cancer. Patient in this case report were eight year olds boys with neuroblastoma.

Case Report

Eight years old boy, came with painless left flank mass since 3 months before admission and septic condition. History of painless intermittent hematuria since 1 month ago. Physical examination revealed 6 cm solid fixed left flank mass. Laboratory revealed increases of ureum and creatinine serum. USG revealed bilateral chronic obstructive parenchymatous disease, with bilateral severe hydronephrosis due to solid mass at pelvic cavity. MRI shows mass bladder with extension from serosa to perivesica accompanied with lymphadenopathy causing bilateral severe hydronephrosis (Figures 1,2).

Cystoscope shows mass invaded the entire wall of the bladder up to bladder neck. Left and right ureteral orifice difficult to evaluate due to expanding of the mass, prostate within normal limits, edge of the mass is difficult to evaluate. TURBT obtained 5 grams of bladder tissue. Left PNS obtained 70 cc cloudy initial urine production and Right PNS obtained 50 cc cloudy initial urine production. With daily urine production: right 250 cc yellowish clear and left 300 cc Cloudy (Figure 3).

On histopathologic examination it was concluded that there was tissue characteristic like malignant epithelial tumors with a differential diagnosis of endocrine neuro carcinoma, high grade urothelial carcinoma, and undifferentiated carcinoma. On immunohistochemical examination revealed vimentin: Negative, CK 20: Negative, NSE: Positive. With the conclusion is Exclude epithelial neither mesenchymal tumor and lead to neuroblastoma. Patient had been planned for cystectomy followed by chemotherapy and radiation. But patient died 10 day after nephrostomy and TURB due to septic shock (Figure 4).

Discussion

Bladder cancer is the most common malignancy of the urinary tract and the seventh most common malignancy of men. The peak incidence of bladder cancer is in the sixth decade of life, while they are rarely seen in children, are only 1% of all cases of bladder cancer with 30% of cases in children aged ≤10 years. Transitional cell cancer (TCC) is the most common pathological finding compare with

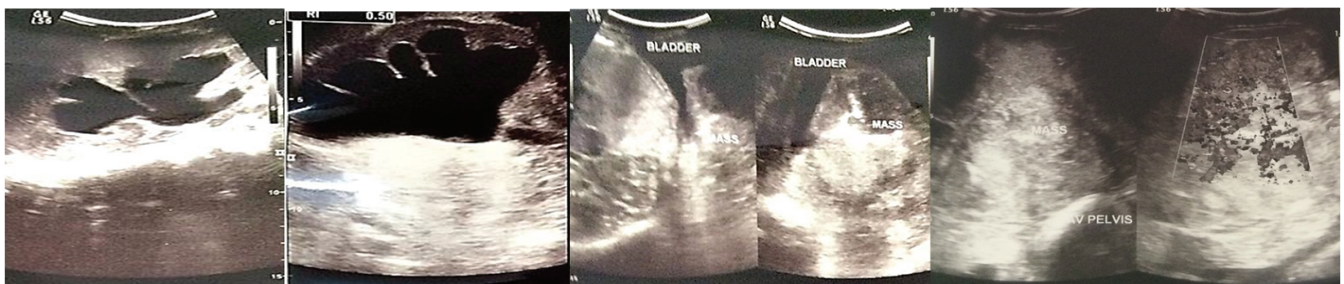


Figure 1: USG: bilateral chronic obstructive parenchymatous disease, with bilateral severe hydronephrosis due to solid mass pelvic cavity.

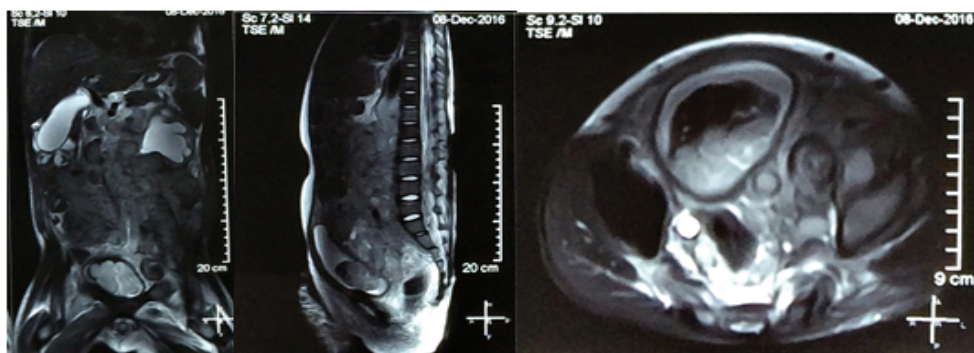


Figure 2: MRI: there are solid mass of malgina bladder with extension from serosa to perivesica accompanied with lymphadenopathy causing bilateral severe hydronephrosis.

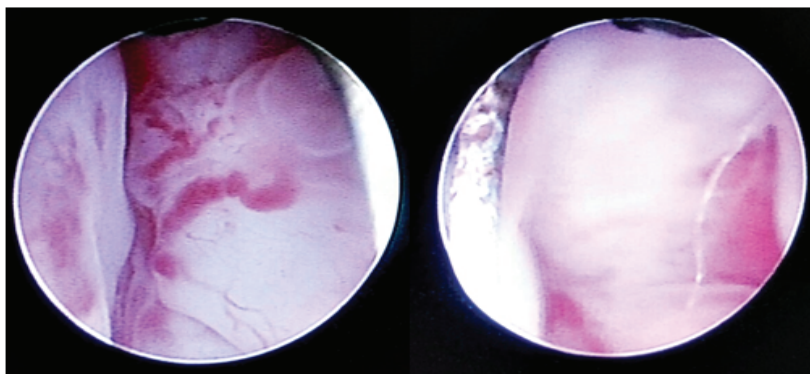


Figure 3: Cystoscope shows mass invaded the entire wall of the bladder up to bladder neck at 12 o'clock, the left and right ureteral orifice difficult to evaluate due to expanding of the mass, prostate within normal limits, edge of the mass is difficult to evaluate.

neuroblastoma is an extremely rare. In this case neuroblastoma of the bladder is the eighth has been reported and the stages are T3bN3M0 accordance with the TNM system 2009 in the guideline of the European Association Urology 2016 [2-5].

In a comprehensive review of cancers in the pediatric age group. Showed that 3% of the muscle invasive cancer and high grade are 1.7% of all cases. Because commonly pediatric malignancy was non muscle invasive and low grade has a better prognosis. In this case bladder cancer is already at the muscle invasive with extension to lymph node resulting locally advanced muscle invasive cancer [6-8].

Only 7 cases of neuroblastoma of the bladder have been reported previously. Three cases presented with gross hematuria, 1 case with a palpable mass on physical examination and the other cases were asymptomatic as a result of a mass screening program in japan. 6 out

of 7 neuroblastoma of the bladder develop at the dome of the bladder and one case happen in the anterior of bladder wall. In this case report patient with gross hematuria and the mass located at the entire wall of the bladder to bladder neck and both ureteral orifice [9-11].

The prognosis for patients with neuroblastoma is related with some of these prognostic factors and been combined to create risk groups to help define treatment. Such as age, Shimada grade, histology and genetics, allows patients to be grouped into 4 different prognostic risk groups ranging from very low, low, moderate and high. Refer to the International Neuroblastoma Risk Group Staging System section and the Children's Oncology Group Neuroblastoma Children of any age with localized neuroblastoma and infants aged 18 months and younger with advanced disease and favorable disease characteristics have a long term, disease-free survival, older children with advanced stage disease,

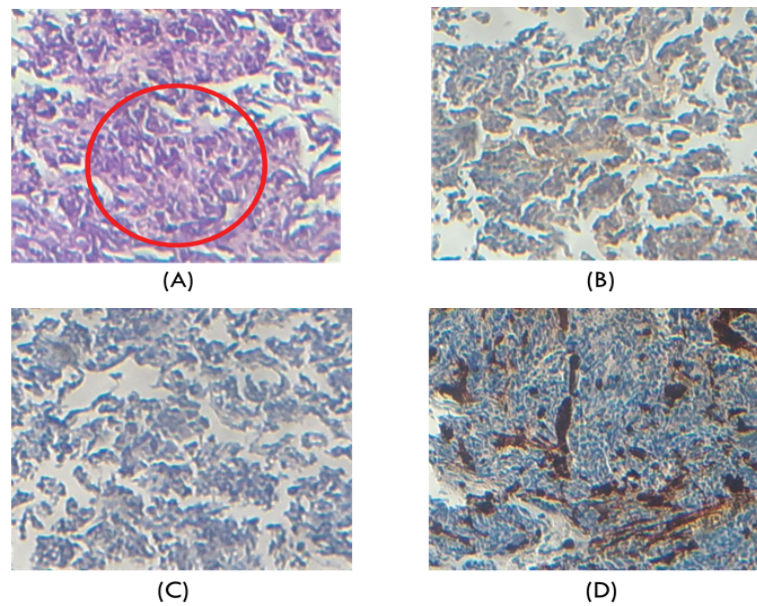


Figure 4: (A) Pseudorosette is common histologic feature in neuroblastoma. (B) Neuron Specific enolase: positive. (C) CK20: Negative. (D) Vimentin: Negative. IHC revealed that this malignancy is n't epithelial neither mesenchymal and lead to neuroblastoma.

however, have a significantly decreased chance for cure, despite intensive therapy. Neuroblastoma has a worse long-term prognosis in adolescents older than 10 years or adults, regardless of stage or site. The disease is more indolent in older patients than in children. According to the INSS, the presence of cancer in the regional lymph nodes on the same side of the body as the primary tumor has no effect on prognosis. In this case bladder cancer is already at the muscle invasive with extension to lymph node resulting poor prognosis [10,11].

Literature revealed that five patients underwent immediate partial cystectomy without neo adjuvant or adjuvant chemotherapy or radiation required, all were classified at stage 1, with favorable prognostic factors and long term survival. Two patients proceeded to have partial cystectomy with carboplatin and etoposide, then 2 cycle of cyclophosphamide, doxorubicin and vincristine chemotherapy with disease free at the 30-45 month follow-up. These two patient at stage 2 and above with extension to lymph node, the disease had poor-risk prognostic indicators such as unfavorable Shimada classification. This case TURBT revealed the malignancy is advanced locally neuroblastoma of the bladder with extension to lymph node and unfavorable Shimada classification and should treated by combination of Radical cystectomy followed by radiation and/or chemotherapy [9-11].

Conclusion

Pediatric bladder neuroblastoma is an extremely rare malignancy. Resection for diagnostic and urine diversion for prevention of late complication are important for holistic therapy. In patients with high grade neuroblastoma of the bladder used of multimodal therapy such as radical surgery for local control and chemotherapy for systemic therapy should be considered as curative or palliative treatment. Take many investigations for multimodal therapy for neuroblastoma of the urinary bladder which aim to improve overall survival.

References

1. National Cancer Institute. Surveillance, Epidemiology, and end Results Program. SEER Stat Fact Sheets: Bladder Cancer.

- Lukacz ES, Sampsel C, Gray M, Macdiarmid S, Rosenberg M, et al. (2011) A healthy bladder: a consensus statement. *Int J Clin Pract* 65: 1026-1036.
- Landis SH, Murray T, Bolden S, Wingo PA (1999) Cancer statistics, 1999. *CA Cancer J Clin* 49: 8-31.
- Alanee S, Shukla AR (2010) Bladder malignancies in children aged <18 years: results from the Surveillance, Epidemiology and End Results database. *BJU Int* 106: 557-560.
- Babjuk M, Oosterlinck W, Sylvester R, Kaasinen E, Böhle A, et al. (2011) EAU guidelines on non-muscle-invasive urothelial carcinoma of the bladder, the 2011 update. *Eur Urol* 59: 997-1008.
- Keetch DW, Manley CB, Catalona WJ (1993) Transitional cell carcinoma of bladder in children and adolescents. *Urology* 42: 447-449.
- Lee TK, Chaux A, Karam S, Miyamoto H, Miller JS, et al. (2011) Papillary urothelial neoplasm of low malignant potential of the urinary bladder: clinicopathologic and outcome analysis from a single academic center. *Hum Pathol* 42: 1799-1803.
- Fine SW, Humphrey PA, Dehner LP, Amin MB, Epstein JI (2005) Urothelial neoplasms in patients 20 years or younger: a clinicopathological analysis using the world health organization 2004 bladder consensus classification. *J Urol* 174: 1976-1980.
- Yokoyama S, Hirakawa H, Ueno S, Yabe H, Hiraoka N (1999) Neuroblastoma of the urinary bladder, preclinically detected by mass screening. *Pediatrics* 103: e67.
- Entz-Werle N, Marcellin L, Becmeur F, Eyer D, Babin-Boilletot A, et al. (2003) The urinary bladder: An extremely rare location of pediatric neuroblastoma. *J Pediatr Surg* 38: E10-E12.
- Zhu J, Hoag NA, Gustafson P, Afshar K, MacNeily AE (2013) Pediatric bladder neuroblastoma: Case report and literature review. *Can Urol Assoc J* 7: E609-E611.