

## Mesangioproliferative Glomerulonephritis Caused by Pegfilgrastim

Joseph Y Lee<sup>1\*</sup>, Mario Zarama<sup>1</sup> and Gretchen Crary<sup>2</sup>

<sup>1</sup>Kidney Specialists of Minnesota, USA

<sup>2</sup>Department of Pathology, Hennepin County Medical Center, Minneapolis, USA

\*Corresponding author: Joseph Y Lee, DO, FACP, Kidney Specialists of Minnesota, USA,

E-mail: [joeylee4600@yahoo.com](mailto:joeylee4600@yahoo.com)

Received date: 06 Sep 2016; Accepted date: 05 Oct 2016; Published date: 11 Oct 2016.

Citation: Lee JY, Zarama M, Crary GS (2016) Mesangioproliferative Glomerulonephritis Caused by Pegfilgrastim. *Int J Nephrol Kidney Failure* 2(4): doi <http://dx.doi.org/10.16966/2380-5498.135>

Copyright: © 2016 Lee JY, et al. This is an open-access article distributed under the terms of the Creative Commons Attribution License, which permits unrestricted use, distribution, and reproduction in any medium, provided the original author and source are credited.

### Abstract

Mesangioproliferative glomerulonephritis (MesPGN) is a nonspecific histologic diagnosis manifested by acute kidney injury (AKI), proteinuria, and hematuria. Its nonspecific histologic pattern is characterized by mesangial proliferation as a response to glomerular injury. Often the mesangial proliferative process in this disease is associated with immunoglobulin and/or complement deposits and can be caused by lupus nephritis, IgA nephropathy, resolving postinfectious glomerulonephritis, or an idiopathic cause. Pegfilgrastim is a granulocyte colony stimulating factor commonly given by injection to treat primary or secondary neutropenia, which includes the treatment of myelodysplastic syndrome (MDS). As far as what is reported in the literature, there has never been a direct association between the use of Pegfilgrastim causing MesPGN in the setting of hypocomplementemia. We report the first case of MesPGN directly caused by Pegfilgrastim.

**Keywords:** Acute kidney injury; Hypocomplementemia; Mesangioproliferative glomerulonephritis; Pegfilgrastim; Myelodysplastic syndrome

### Background

Mesangioproliferative Glomerulonephritis (MesPGN) is an uncommon cause of nephritis and acute kidney injury (AKI) with typical urine sediment showing dysmorphic red cells and occasionally red cell casts with variable degrees of proteinuria [1]. The diagnosis of MesPGN made by kidney biopsy based on a histologic pattern of glomerular injury on light microscopy characterized by an increase in mesangial cells in all or nearly all glomeruli [1]. The mesangial proliferation with matrix deposition associated with MesPGN is usually the result of immunoglobulin or complement deposition and are most commonly the result of lupus nephritis, IgA nephropathy, resolving postinfectious glomerulonephritis, or an idiopathic cause for which there are nonspecific immunoglobulin or complement deposition [2-4].

Pegfilgrastim is a pegylated form of recombinant human granulocyte colony-stimulating factor and is commonly given by injection to stimulate bone marrow production of neutrophils. It is a drug often used in patients with myelodysplastic syndrome (MDS) when they are neutropenic [5]. We report the first case of MesPGN with hypocomplementemia directly associated with Pegfilgrastim use.

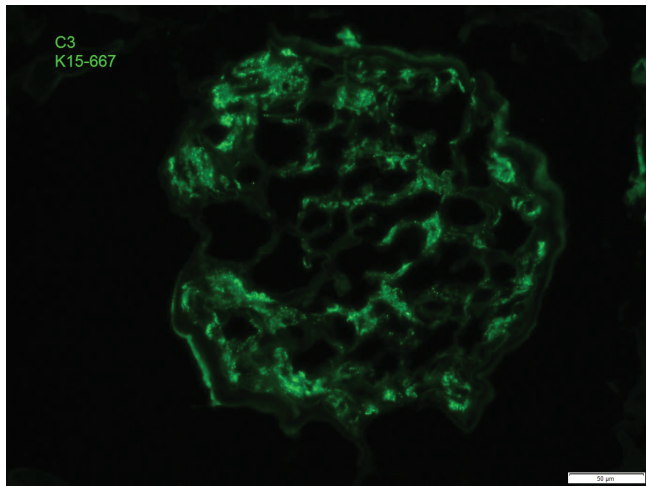
### Case Report

A 78 year old white female diagnosed with MDS by a recent bone marrow biopsy presented with 4 days of worsening shortness of breath and profound lower extremity weakness. The patient's past medical history includes diabetes, hypertension, gout, and hypothyroidism for which she had been on chronic stable medications before receiving one 6mg dose of Pegfilgrastim one day prior to the start of her symptoms for the treatment of her neutropenia related to her MDS. Initial assessment discovered AKI with a serum creatinine (scr) of 2.31 mg/dL which is a new finding from blood work performed 2 weeks prior to her Pegfilgrastim injection when her serum creatinine was 0.89 mg/dL. Her urinalysis (UA) showed large blood, greater than 500 mg/dL of protein with microscopy revealing 5-10 per white blood cells (WBCs) and 10-25 red blood cells

(RBCs) both per high power field. Her prior UA before Pegfilgrastim injection had been normal. The patient subsequently developed oliguric AKI requiring initiation onto hemodialysis 3 days after her admission with a scr that rose to 4.96 mg/dL. A C3 and C4 complement level done the day after admission as part of her work up for AKI were both found to be low at 44 and 4 mg/dL, respectively. Antineutrophilic cytoplasmic antibodies (ANCA) and anti neutrophilic antibody (ANA) tests were negative. A kidney biopsy was performed showing MesPGN with mesangial proliferation and glomerular capillary loop thickening on light and electron microscopy and marked C3 complement deposition on immunofluorescence microscopy. The patient eventually regained kidney function after 2 weeks on hemodialysis. Her 4 week outpatient follow-up after her discharge showed that her AKI, C3 complement levels, and active urine sediment had completely normalized without any definitive therapy other than stopping her Pegfilgrastim for which this patient only received one injected dose. This is the first reported case of kidney biopsy proven MesPGN with hypocomplementemia directly linked to Pegfilgrastim injection.

### Discussion

MesPGN not related to IgA nephropathy, lupus nephritis, or postinfectious glomerulonephritis is a relatively rare cause of nephritis in patients presenting with AKI with microscopic hematuria and proteinuria [3,4,6]. This case outlines a direct relationship between Pegfilgrastim and the development of AKI with microscopic hematuria and proteinuria diagnosed as a C3 mediated MesPGN by kidney biopsy in the setting of hypocomplementemia. There were multiple direct relationships of Pegfilgrastim causing MesPGN in this case. The fact that her MesPGN began after having a normal scr 2 weeks before receiving her Pegfilgrastim injection and a prior UA that was normal is supportive. Also this patient had hypocomplementemia with associated C3 complement deposition seen on immunofluorescent microscopy of her kidney biopsy specimen (Figure 1). She subsequently had normalization of her C3 complement level at her 4 week post discharge outpatient follow-up without any therapy other than holding Pegfilgrastim. The fact that this patient had no new



**Figure 1:** Severe granular mesangial C3 staining in mesangial areas

recent medication changes, acute illnesses, and her AKI and abnormal UA resolved spontaneously without any therapy other than holding further Pegfilgrastim injections fully support that this medication was the direct cause of this patient's MesPGN. Though there are reported case reports [7-9] of nephritis from Pegfilgrastim injection due to biopsy proven mesangio and membranoproliferative glomerulonephritis, these cases were confounded by either the patient being on multiple chemotherapeutic agents with normal complement levels, and/or an indirect association. In conclusion, Pegfilgrastim can cause a complement mediated AKI with microscopic hematuria, proteinuria, and hypocomplementemia as a result of MesPGN. Treatment is supportive while holding further Pegfilgrastim. In this case, supportive care while holding Pegfilgrastim resulted in the resolution of this patient's AKI, microscopic hematuria, C3 hypocomplementemia, and proteinuria.

### Conflict of Response

All authors disclose no potential conflicts of interest or support/funding for this study.

### References

1. Brown EA, Upadhyaya K, Hayslett JP, Kashgarian M, Siegel NJ (1979) The clinical course of mesangial proliferative glomerulonephritis. *Medicine (Baltimore)* 58: 295-303.
2. O'Donoghue DJ, Lawler W, Hunt LP, Acheson EJ, Mallick NP (1991) IgM-associated primary diffuse mesangial proliferative glomerulonephritis: natural history and prognostic indicators. *Q J Med* 79: 333-350.
3. Owada K, Suzuki H, Katoh T, Watanabe T (2010) Genetical, histological, and clinical characteristics of IgA-negative mesangioproliferative glomerulopathy. *Clin Exp Nephrol* 14: 56-62.
4. Waldherr R, Gubler MC, Levy M, Broyer M, Habib R (1978) The significance of pure diffuse mesangial proliferation in idiopathic nephrotic syndrome. *Clin Nephrol* 10: 171-179.
5. Steensma DP, Bennett JM (2006) The myelodysplastic syndromes: diagnosis and treatment. *Mayo Clin Proc* 81: 104-130.
6. Danilewicz M, Wągrowka-Danilewicz G (1998) Diffuse idiopathic mesangial proliferative glomerulonephritis in re-biopsied patients. A quantitative study. *Med Sci Monit* 4: CR955-959.
7. Arora S, Bhargava A, Jasnosz K, Clark B (2012) Relapsing acute kidney injury associated with pegfilgrastim. *Case Rep Nephrol Urol* 2: 165-171.
8. Waikhom R, Sarkar D, Patil K, Pandey R, Dasgupta S, et al. (2012) Non-IgA mesangioproliferative glomerulonephritis: a benign entity?. *Nephrol Dial Transplant* 27: 2322-2327.
9. Magen D, Mandel H, Berant M, Ben-Izhak O, Zelikovic I (2002) MPGN type 1 induced by granulocyte colony stimulating factor. *Pediatr Nephrol* 17: 370-372.