

Nuclear and Cytoplasmic Changes in Buccal Mucosal Cells of Alcoholic, Premalignant and Betel Quid/Nut Chewing with Tobacco (BQT) Cases

Riaz Abdulla¹, Vagish Kumar L Shanbhag^{2,*}, Jagadish Kudkuli³, Neevan D'Souza⁴, Pushparaja Shetty⁵ and Sarosh E Shroff⁶

¹Department of Oral Pathology and Microbiology, Yenepoya Dental College and Hospital, Yenepoya (Deemed to be University), University Road, Deralakatte, Mangalore, Karnataka, India.

²Department of Oral Medicine and Radiology, Yenepoya Dental College and Hospital, Yenepoya (Deemed to be University), University Road, Deralakatte, Mangalore, Karnataka, India.

³Yenepoya Research Centre, Yenepoya (Deemed to be University), University Road, Deralakatte, Mangalore, Karnataka, India.

⁴Department of Biostatistics, KS Hegde Medical Academy, Deralakatte, Mangalore, Karnataka, India.

⁵Department of Oral Pathology and Microbiology, AB Shetty Memorial Institute of Dental Sciences, Nitte University, Deralakatte, Mangalore, Karnataka, India.

⁶AB Shetty Memorial Institute of Dental Sciences, Nitte University, Deralakatte, Mangalore, Karnataka, India.

***Corresponding author:** Dr. Vagish Kumar L S, Reader, Department of Oral Medicine and Radiology, Yenepoya Dental College and Hospital, Yenepoya (Deemed to be University), University Road, Deralakatte, Mangalore-575018, Karnataka, India, E-mail: vagish-kumar_12@rediffmail.com

Received: 12 Apr, 2019 | **Accepted:** 30 Apr, 2019 | **Published:** 06 May, 2019

Citation: Abdulla R, Shanbhag VKL, Kudkuli J, D'Souza N, Shetty P, et al. (2019) Nuclear and Cytoplasmic Changes in Buccal Mucosal Cells of Alcoholic, Premalignant and Betel Quid/Nut Chewing With Tobacco (BQT) Cases. *Int J Dent Oral Health* 5(3): dx.doi.org/10.16966/2378-7090.293

Copyright: © 2019 Abdulla R, et al. This is an open-access article distributed under the terms of the Creative Commons Attribution License, which permits unrestricted use, distribution, and reproduction in any medium, provided the original author and source are credited.

Abstract

Introduction: Oral cytopathological techniques are widely used in the detection of malignant and premalignant lesions in cases of oral squamous cell carcinoma (OSCC) and to monitor clinically innocuous lesions complications in head and neck areas. The aim was to apply Papnicolaou (PAP), and Silver staining nuclear organizer regions (AgNOR) staining techniques to derive comparison and correlation of resulting parameters under study.

Materials and Methods: 120 cases of normal, alcoholic, betel quid with tobacco (BQT) and premalignant individuals were considered for the study. PAP and AgNOR staining were carried out to analyse cytoplasmic diameter (CD), nuclear diameter (ND), nuclear area (NA), cytoplasmic area (CyA), nuclear-to-cytoplasmic ratio (NA: CyA), and AgNOR scoring parameters. Tukey's HSD multiple comparison tests and Pearson's correlation method were done to compare and correlate the variables under study.

Results: When compared to controls, all the variables in all the groups (except AgNOR counts in alcoholic group) in the study showed a significant difference compared to controls. Similarly, correlation tests emphasized on significant diagnostic correlation between variables in all the groups with respect to controls (except ND and AgNOR count in alcoholic group, and CD and ND in premalignant group) under study.

Conclusion: Determination of cell and nuclear diameter by computer-assisted cytomorphometry and AgNOR staining methods are prominent reliable markers in the diagnosis of neoplastic, premalignant and malignant lesions. Also, being economical, effective and non-invasive, these simple techniques can be combined and standardized for optimal monitoring and detection of oral cancers.

Keywords: Cell diameter (CD); Nuclear diameter (ND); Silver staining nuclear organizer regions (AgNOR); Oral squamous cell carcinoma (OSCC); Diagnostic markers.

Introduction

Worldwide, head and neck cancer (HNC) accounts for more than 550,000 cases and 380,000 deaths annually with the male to female ratio ranging from 2:1 to 4:1 [1,2]. 90% of all cancers in oral cavity are oral squamous cell carcinomas (OSCCs) making them one of the major global health problem with increasing mortality rates [3]. The annual incidence rate is around 275,000 for oral and 130,000 for oropharyngeal cancers, two-third of the cases occurring in developing

countries. The incidence rate in India is around 19 per 100,000 of the population, and among oral cancers, squamous cell carcinoma (OSCC) comprises 90% of all oral malignancies [4]. Oral cancer is apparently innocuous to begin with; termed as pre-cancer which is clinically recognized, providing an opportunity for the prevention of oral cancer. Tobacco-related habits with or without combination with alcoholism may prompt formation of clinically detectable lesions and other changes like variations in Nucleolar Organiser Regions (NORs),

and nuclear sizes within the epithelial cells, which can be biopsied and confirmed. Aetiology of OSCC is multifactorial with both chemical (tobacco, alcohol); biological (Human papilloma virus (HPV) and Epstein-Barr virus) playing major role [5].

Early stage diagnosis can be achieved by exfoliative cytology, which is an important alternative to biopsy in certain situations. Cells shed from body surfaces, such as inside the mouth, are collected and examined. Stratified squamous cells of oral epithelium are maintained by a system of continuous renewal mechanism, by processes of desquamation to get rid of old cells and mitotic division to replenish with new cells [6]. Quantitative parameters like nuclear size, cell size, nuclear-to-cytoplasmic ratio, nuclear shape, nuclear discontinuity, optical density and nuclear texture are used in the cytopathologic diagnosis using exfoliative cytology. However, nuclear size determined by Nuclear diameter (ND), and cytoplasmic size determined by Cell diameter (CD), and their ratio have been shown to be of significance in the evaluation of oral lesion [7]. The inverse relationship between these two parameters occurs significantly in actively proliferating cells upon exposure to carcinogenic agents. Increase in the nuclear size is related to an increase in the nuclear contents required for replication and, the ability of cytoplasm to mature diminishes resulting in shrinkage of cells with increased activity [8].

AgNORs (silver staining nuclear organizer regions) are loops of ribosomal DNA located on the short arms of acrocentric chromosomes 13,14,15,21 and 22, which upon transcription forms rRNA [9]. Binding of silver and protein occurs in carboxyl and sulphhydryl groups, by colloidal precipitation of ionic silver. The carboxyl groups on the protein reduce the silver solution, forming the micronuclei of silver aggregates at disulfide and sulphhydryl group sites. These are seen by light microscopy as black intranuclear granules termed as AgNOR counts/scoring. In normal cells, the AgNORs are tightly packed and the nuclei are indiscernible [10]. In rapidly proliferating cells such as neoplastic cells, nucleolar disaggregation may take place resulting in the dispersion of individual AgNOR. The number of AgNORs per nucleus has been correlated with the ribosomal RNA transcription rate, cell proliferation, and DNA ploidy, and is an important assessment for index for assessment of proliferating cells [11].

With image-assisted automated techniques, both qualitative and quantitative cytomorphometry is possible upon PAP (Papanicolaou staining) of exfoliated cells. The procedure is non-invasive, economical and reproducible in the diagnosis of even minute dysplastic change and thus improving the detection of very small and early-stage tumours [12,13]. Oral exfoliative cytology is particularly valuable for mass screening purposes with a sensitivity of 94% and specificity of 100% [14]. In this study, cytomorphometric analysis was applied to a total sample size of 120 smears using PAP and AgNOR staining on 3 groups of cases, 30 each from alcoholic, BQT and premalignant, 30 healthy buccal smears as controls.

Materials and Methods

The study was approved by the Institutional Ethics Committee, A.B Shetty Memorial Institute of Dental Sciences, Mangalore, Karnataka, following which detailed history about the chewing habits and alcohol consumption was recorded, and an informed consent was signed by the participants. Non-anaemic patients [Hemoglobin (Hb) \geq 12.5 g/dL] above age 40 years were studied irrespective of sex, caste and socioeconomic status. 90 patients with the habit of betel quid with tobacco chewing, alcohol consumption and individuals with premalignant lesion were selected. 30 participants without any

pre-malignant or malignant lesions, tobacco, alcohol and oral cancer inducing habits were selected as controls for the study. The buccal mucosal scrape was collected using metal spatula and the slides were fixed immediately and subjected to PAP and AgNOR staining after one hour.

PAP staining

PAP staining procedure was carried out approximately in 300 seconds with procedures as per reference to the literature and lab standardization [15]. Staining was carried out by stepwise treatment with 95% alcohol and Haematoxylin, Orange-G6 and Polychromatic Eosin-Azure staining followed by final fixation on slides using Xylene.

AgNOR staining and counting

Fresh working solution was prepared by mixing one volume of 2% gelatin in 1% formic acid solution and two volumes of 50% aqueous silver nitrate solution followed by a 30 minute incubation at 45°C in a dark area not exposed to sunlight. The AgNOR count was established on 50 cells for each cytologic smear and examined at 1000x magnification under oil immersion microscopy [16]. The images of cells were captured with a 3-chip CCD camera attached to the microscope and analysis was done using the software Motic digital images 2000 software 1.1. The largest diameter of the cell and the nucleus was taken into consideration. Measurement was done in microns ($1\mu=1.6160$ pixels).

Statistical analysis

Tukey's HSD multiple comparison test was carried out to derive significance of the variables between control and different case groups. P value \geq 0.05 was considered to be significant. Pearson's correlation test was done to derive correlation of variables in the study (CD, ND and AgNOR) in alcoholic, BQT and premalignant cases with respect to control. Pearson's correlation coefficient (r)=(0-0.29) indicates no linear relationship, r =(0.3-0.49) =weak uphill positive (+ve) relationship, r =(0.5-0.69)=moderate uphill +ve relationship and, $r \geq$ 0.7=strong uphill +ve linear relationship [17].

Results

The values of CD, ND and AgNOR were averaged and expressed as Mean \pm S.D (Table 1). PAP stained and AgNOR stained oral squamous epithelium smears for cytomorphometry and AgNOR counting is presented in figures 1 and 2. Nuclear to cytoplasmic ratio (NA: CyA) was calculated from cytomorphological parameters of CyA and NA. Figure 3 shows gradual building up in NA: CyA ratio from normal to BQT and premalignant cases. However, in alcoholic cases, the ratio was the lowest owing to shrinkage in cytoplasmic area and swelling of nuclear area. The sensitivity of exfoliative cytology to detect early malignancy can be increased by observing the parameters NA, CyA, and NA: CyA. AgNOR scoring showed a gradual increase from normal to alcohol, BQT and premalignant cases. Tukey's multiple comparison tests were carried out to determine the significance of variation in ND, CD and AgNOR count variables in Normal, Alcohol, BQT and Premalignant cases (Table 2). Mean CD of BQT ($p=0.001$) and Premalignant ($p=0.001$) cases were significantly decreased compared to controls and nuclear diameter was found to be significantly reduced ($p=0.005$ and 0.001). However, in alcoholic cases, both CD and ND were significantly reduced as compared to controls ($p=0.014$ and 0.045). Comparing AgNOR count parameter, it was found that BQT ($p=0.001$) and premalignant ($p=0.001$) cases had a significant increase in the AgNOR count, while an increase in AgNOR counts of alcoholic cases was not significant compared with controls.

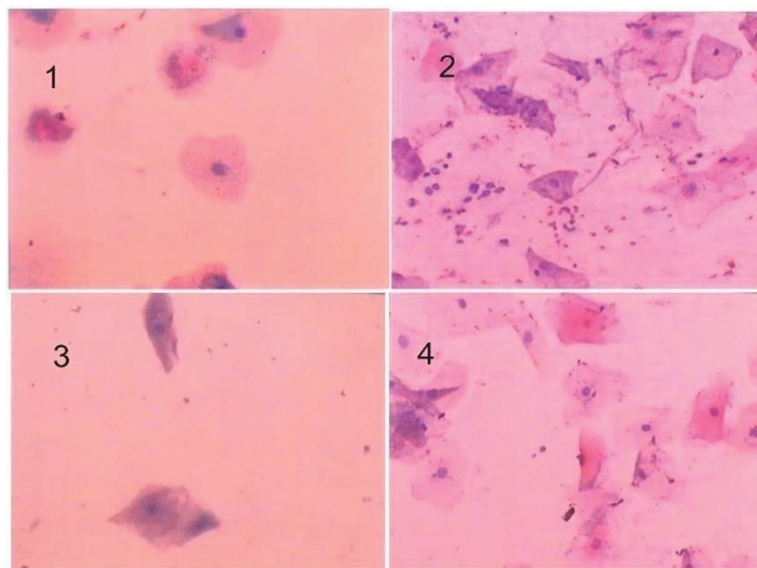


Figure 1: PAP stained buccal smears (X40) obtained from (1) Normal, (2) Premalignant, (3) Alcoholic and (4) BQT cases.

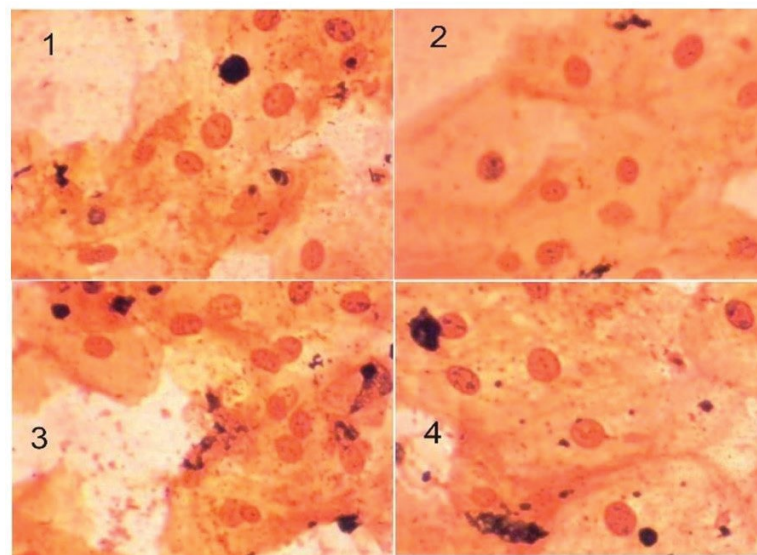


Figure 2: AgNOR stained buccal smears (X40) obtained from (1) Normal, (2) Premalignant, (3) Alcoholic and (4) BQT cases.

Pearson's correlation coefficient was obtained for each of the test cases and correlated with normal cases. Results presented in table 3 emphasise weak uphill (+ve) correlation for ND and CD of alcoholic cases when correlated with controls ($r = 0.315$), which denotes significant reduction ($p=0.014$) in nuclear and cell diameter of alcoholic cases with respect to controls. Correlation coefficient for CD and AgNOR parameters showed weak downhill (-ve) ($r=-0.311$) correlation denoting significant increase ($p=0.016$) in AgNOR counts with constriction of cell diameter in alcoholic cases with respect to controls. For BQT cases, CD and AgNOR parameters showed a moderate downhill (-ve) ($r=-0.452$) negative correlation, denoting significant increase ($p=0.001$) in AgNOR counts with reduction in cell diameter in BQT cases with respect to normal cases. ND and AgNOR parameters show a weak uphill (+ve) ($r=+0.268$) positive correlation, indicating significant proportional increase ($p=0.038$) in

AgNOR counts with Nuclear diameter of BQT cases, when compared with controls. In premalignant cases, CD and AgNOR counts showed a moderate downhill (-ve) ($r=-0.523$) correlation indicating significant reduction ($p=0.001$) in cell size with increase in AgNOR counts of premalignant cells with respect to controls. A similar observation was made for ND and AgNOR parameters, which showed a weak uphill (+ve) ($r=0.369$) correlation indicating significant proportional increase ($p=0.004$) in AgNOR counts with the nuclear diameter of premalignant cases with respect to controls.

Discussion

Exfoliative cytology is a rapid non-invasive procedure which gives objective measurements of quantitative parameters and acts as an important adjunct in making a cytopathological diagnosis [18]. Results based on a single cytological method are unpredictable

Table 1: Mean CD, ND and AgNOR counts in Normal, Alcoholic and BQT cases.

	Mean Cell Diameter (CD) (\pm S.E) (μ m)	Mean Nuclear Diameter (ND) (\pm S.E) (μ m)	Mean AgNOR counts
Normal (N=30)	65.38 \pm 1.49	10.27 \pm 0.25	2.53 \pm 0.12
Alcoholic (N=30)	62.42 \pm 0.24	9.51 \pm 0.11	2.66 \pm 0.14
Tobacco (N=30)	61.54 \pm 0.25	11.8 \pm 0.14	3.3 \pm 0.13
Premalignant (N=30)	58.78 \pm 0.39	12.32 \pm 0.14	3.83 \pm 0.15

*CD: Cell Diameter, ND: Nuclear Diameter, AgNOR: Silver staining nucleolar organizing regions, BQT: Betel quid with tobacco.

Table 2: Tukey HSD Multiple comparison tests for ND, CD and AgNOR count variables in Normal, Alcohol, BQT and Premalignant cases.

Variables	Cases	P value [95% CI]		
		Alcohol	BQT	Premalignant (N=30)
ND	Normal (N=30)	0.014*	0.001*	0.001*
	Alcohol (N=30)		0.001*	0.001*
	BQT (N=30)			0.17
CD	Normal	0.045*	0.005*	0.001*
	Alcohol		0.864	0.008*
	BQT			0.071
AgNOR	Normal	0.905*	0.001*	0.001*
	Alcohol		0.005*	0.001*
	BQT			0.058

*Implies statistically significant observations

#CD: Cell Diameter, ND: Nuclear Diameter, AgNOR: Silver staining nucleolar organizing regions, BQT: Betel quid with tobacco.

Table 3: Correlation of Controls with Alcoholic, BQT and Premalignant cases for NA, CyA and AgNOR parameters.

		Control w/t Alcohol		Control w/t BQT		Control w/t Premalignant	
		ND	AgNOR	ND	AgNOR	ND	AgNOR
CD	Pearson Correlation	0.315*	-0.311*	-0.003	-0.452*	-0.198	-0.523*
	P	0.014	0.016	0.98	0.001	0.129	0.001
ND	Pearson Correlation	1	-0.022	1	0.268*	1	0.369
	P		0.865		0.038		0.004

#CD: Cell Diameter, ND: Nuclear Diameter, AgNOR: Silver staining nucleolar organizing regions, BQT: Betel quid with tobacco.

*Implies statistically significant observations.

and hence different methods are combined for greater sensitivity in detecting incipient malignant changes and for application in secondary prevention programs [19]. Incorporating computer-assisted image analyser into cytomorphometry nullifies intra-observer variation to a major extent, enabling direct comparison from person to person with high reproducibility. The premalignant condition is determined by some standard histological features like drop-shaped rete processes, altered cellular polarity, nuclear changes, basal cell hyperplasia and extensive surface keratinization in buccal squamous epithelium and is assessed through histological Haematoxylin and Eosin (H&E) stain preparation followed by TNM staging as premalignant, malignant, etc [20].

In our study, cytomorphometric parameters-CD, ND, and AgNOR were evaluated in normal cases, BQT, alcohol consumers, and premalignant lesions and a correlation was obtained. Decrease in CD

in tobacco and premalignant buccal smears are an early indication of dysplastic change [21]. In oral leukoplakia, samples with reduced CD were observed compared to that of normal oral mucosa. However, it relied on a single parameter, CD for example, and found varying results among the cells in various layers; wherein CD increased in basal and parabasal, but those of spinous cells were reduced. Such changes occurring in the basal cells were thought to indicate an increased metabolic activity prior to the invasion of the underlying connective tissue [21]. If the CD changes are considered proportional to changes in cytoplasmic area, then the reduction in CD of cells obtained from oral leukoplakia could be an early cytological indication of dysplastic change. Increase in ND in tobacco and premalignant group is due to increased DNA content of the nucleus, causing inflammatory change and chronic irritation [22]. Increase in ND with dysplasia and squamous cell carcinoma have been reported in cervical smears

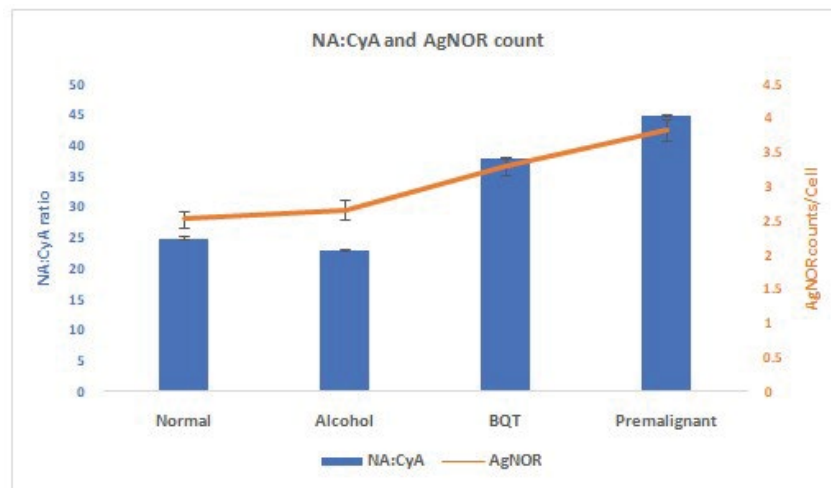


Figure 3: Correlation of Controls with Alcoholic, BQT and Premalignant cases for CD, ND and AgNOR parameters.

and experimental lesions in hamster cheek pouch epithelium [23]. Alcoholism was found to reduce both the nuclear and cytoplasmic area, which was thought to be due to dehydrating action of alcohol on the cells [24]. Alcoholic group in our study was an exclusive sample devoid of any other habits, and the rate of consumption was assessed merely based on history of recent drinking pattern. Reduction of CD and ND in alcoholic group indicates epithelial atrophy which was also observed in *in vivo* studies with rats and human lingual epithelium [25]. Most of the alcohol is metabolized by alcohol dehydrogenase to acetaldehyde, a highly toxic substance suspected to cause tissue damage, attributed to alcohol ingestion. However, acetaldehyde is rapidly metabolized to a non-toxic state (acetate) by aldehyde dehydrogenase [25,26]. Thus, individual variation in the oxidation of ethanol to acetaldehyde, and in particular the length of time required to catalyse the latter to acetic acid by acetaldehyde dehydrogenase (ALDH), are important factors for cytomorphological variation.

Although, there is no clear evidence for carcinogenic risk from the use of betel quid, areca nut, and slaked lime; addition of smokeless raw tobacco to this combination would expose to carcinogens like Tobacco-Specific Nitrosamines (TSNs), N-nitrosornicoline (NNN), Aromatic hydrocarbons and Benzopyrene to underlying mucosa, and thus risks initiation of carcinogenic mechanism [26,27]. Tobacco in any form can cause health risks. It is suspected that reduction in the Langerhan's cells at the site of contact by smokeless tobacco and the tobacco-specific nitrosamines is the main etiologic factor in smokeless tobacco-related oral cancer lesions. Smokeless tobacco products are not burned and the lesion caused by smokeless tobacco habit is 7.5 times more common in the gingivobuccal complex [28]. All the patients in the study were non-anemic, and none of them gave any history of radiotherapy. Nutritional deficiencies like hypochromic anemia (iron deficiency) and megaloblastic anemia (deficiency of vitamin B12 and folic acid) disturb DNA synthesis, with consequent increase in both cytoplasm and nucleus size [29]. Earlier studies have shown no significant variation in NA and CA, above the age of 40 years in non-habitual normal oral squamous samples [8]. Hence, our study included patients above 40 years of age and non-anaemic to rule out the variation of the cytoplasmic and nuclear size.

Work using the AgNOR technique has demonstrated a correlation between the number of AgNORs per nucleus and the proliferative

activity on a variety of pathologic entities. Malignant cells presented large numbers per nucleus and irregular shaped AgNORs, while in benign cells the AgNOR number per nucleus was comparatively smaller and the AgNORs had regular shape. A correlation was seen between AgNORs in benign and malignant cells in fine needle aspiration cytology of salivary gland masses [30]. In cytologic smears, the analysis of AgNORs is more accurate because the whole nucleus can be assessed rather than only a part of it as it occurs in tissue sections. It is proposed that the amount of AgNOR protein is related to cell cycle, increasing progressively from G-0 to S phase, and is proportional to proliferative activity of neoplastic cells, as demonstrated by the correlation with the indices of cell proliferation [31]. The AgNOR method may be of some use in early diagnosis of oral cancer, particularly for epidemiologic studies. Earlier studies demonstrated that the mean AgNOR count at 2.37 may represent a cut off point for making a diagnosis. Leukoplakic lesions with mean AgNOR count of 2.37 or more could be diagnosed as dysplastic leukoplakia and those with less than 2.37 be diagnosed as non-dysplastic leukoplakia [32]. In our study, the mean AgNOR count was significantly high in tobacco chewers (3.33) and premalignant lesions (3.83) when compared to normal controls. The mean AgNOR count for the alcohol consumers group (2.67) was statistically not significant when compared to the normal controls.

Determining the degree of correlation in the parameters, it is essential to validate and establish the experiment and obtained data. Feulgen staining assessment was done on frequency of micronuclei (MN), Binucleated cells (BN), Broken eggs (BE) and Karyorrhexis (KR) and significant increase in the frequency of MN was observed in cells exfoliated from the tongue of cocaine users ($p=0.01$); and alcoholics showed a higher frequency of KR in cells obtained from the floor of the mouth [33]. Diagnostic variables like AgNOR, nuclear to cytoplasmic area ratio, satellites and clusters were assessed for their accuracy through sensitivity-specificity analysis, and total number of AgNOR was considered to be a reliable marker for detecting neoplastic cells and buccal mucosal exfoliations from diabetic patients [34,35]. Despite the fact that cytomorphometric parameters are proven in terms of accuracy and their mechanism, correlating these multiple criteria is not found in recorded literature. Revelations of our work emphasize that there is a significant correlation between CD and AgNOR count parameters in BQT, alcoholic and premalignant cases

with respect to that of controls. Similarly, ND and AgNOR count parameters also had significant correlation in BQT and premalignant cases with respect to that of controls. Therefore, assessment of oral squamous epithelium with a combination of CD, ND and AgNOR scoring would yield explicit results about indications of malignancy and hence act as reliable prognostic and diagnostic markers.

Cytomorphometric analysis cannot be used as a substitute for histologic evaluation by means of biopsy. But it can provide an important adjunct in the assessment of patients with potentially cancerous oral lesion. Quantitation of cell components such as DNA is possible with techniques like flow cytometry [36]. Stereological techniques are useful in measuring three-dimensional changes and ploidy status of the cell, but have not been applied to cytological smears wherein only linear measurements are possible. Consideration should be made for the use of cytology in monitoring clinically innocuous lesions since it provides the pathologist with a representative sample of that lesion. In cases where patients are nervous and reject biopsy procedures, cytology can be implemented since it is non-invasive and less stressful. Cytology can also be of value where surgery is contraindicated or in cases of post radiotherapy follow up [37]. Our results with PAP staining to measure CD and ND combined with AgNOR staining to measure silver stained Nucleolar organizer regions (NORs) indicate that quantitative cytology could be of great value for monitoring and follow up of suspicious lesions and provide an excellent additional diagnostic test for detecting early oral malignancy. Inculcating AgNORs count techniques and deriving correlation with cytomorphometric parameters could be useful tool standardized for the early detection of malignancy.

Conclusion

The reduction in cell diameter and increase in nuclear diameter could be early indications of malignant change in cytomorphometry. The simple, inexpensive and easy cytomorphometric analysis method used in the study has potential to make the early detection of cancer in subjects with habitual tobacco chewing, alcohol consumers and premalignant lesions more objective and practically applicable one. Quantitative parameters are objective and reproducible as they are important aids in making cytopathologic diagnosis. Thus, with the advancement in the field of quantitative oral exfoliative cytology, interest in oral cytology has once again emerged in the diagnosis of malignancy. The recent spectacular developments in objective analysis of the cell, cell components and to some extent histologic tissue sections relate to the development in computer science, allowing the automation of many functions previously requiring manual calculations. Silver staining nucleolar organizer regions (AgNORs) count used as an objective marker in the study to correlate buccal mucosa of tobacco consumers, alcoholics and premalignant lesions proves to be a useful tool for the early detection of malignancy.

References

1. Fitzmaurice C, Allen C, Barber RM, Barregard L, Bhutta ZA, et al. (2017) Global, regional, and national cancer incidence, mortality, years of life lost, years lived with disability, and disability-adjusted life-years for 32 cancer groups, 1990 to 2015: a systematic analysis for the global burden of disease study. *JAMA Oncol* 3: 524-548.
2. Tilakaratna W, Warnakulasuriya S (2014) *Oral medicine and Oral pathology. A guide to diagnosis and management*. 1st edition, Jaypee brothers, India.
3. Choi S, Myers JN (2008) Molecular pathogenesis of oral squamous cell carcinoma: implications for therapy. *J Dent Res* 87: 14-32.
4. Binmadi NO, Basile JR (2011) Perineural invasion in oral squamous cell carcinoma: a discussion of significance and review of the literature. *Oral oncol* 47: 1005-1010.
5. Stenson KM, Brockstein BE, Ross ME (2016) *Epidemiology and risk factors for head and neck cancer*.
6. Nanci A (2018) *Ten Cate's Oral Histology: Development, Structure, and Function*. 9th edition, Elsevier, St Louis, Missouri, USA.
7. Singh M, Sircar K, Tandon A, Chowdhry A, Popli DB (2014) The role of tobacco as an etiological agent for oral cancer: Cytomorphometrical analysis of the buccal mucosa in tobacco users. *Dent Res J (Isfahan)* 11: 649-655.
8. Cowpe JG, Longmore RB, Green MW (1985) Quantitative exfoliative cytology of normal oral squames: an age, site and sex-related survey. *J R Soc of Med* 78: 995-1004.
9. Biswal BM, Othman NH (2010) Correlation of Nuclear Morphometry and AgNOR Score with Radiation Response in Squamous Cell Cancers of the Head and Neck: A Preliminary Study. *Malays J Med Sci* 17: 19-26.
10. Treere D (2000) AgNOR staining and quantification. *Micron* 31: 127-131.
11. Cancado RP, Yurgel LS, Filho MS (2001) Evaluation of the nucleolar organizer region associated proteins in exfoliative cytology of normal buccal mucosa. Effect of smoking. *Oral oncol* 37: 446-454.
12. Syamala B, Chitturi RT, Chandrasekhar P, Prakash Chandra KL, Kumar KK, et al. (2017) Cytomorphometric analysis of exfoliated buccal cells to evaluate the malignant changes in individuals with tobacco smoking and chewing habits. *J NTR Univ Health Sci* 6: 143-148.
13. Nadaf A, Bavle RM, Thambiah LJ, Paremala K, Sudhakara M, et al. (2014) A phase contrast cytomorphometric study of squames of normal oral mucosa and oral leukoplakia: Original study. *J Oral Maxillofac Pathol* 18: S32-S38.
14. Rajesh SB, Reddy SB, Ramamurthy TK, Srinivas K, Patil S (2012) Cytomorphometric analysis of obtained squames obtained from normal oral mucosa and lesions of oral submucous fibrosis. *J Indian Acad Oral Med Radiol* 24: 200-205.
15. Thakur M, Guttikonda VR (2017) Modified ultrafast Papanicolaou staining technique: A comparative study. *J Cytol* 34: 149-153.
16. Crocker J, Boldy DA, Egan MJ (1989) How should we count AgNORs? Proposals for a standardized approach. *J pathol* 158: 185-188.
17. Mindrila D, Balentyne P (2013) Scatterplots and Correlation.
18. Ogden GR, Cowpe J, Wight AJ (1997) Oral exfoliative cytology: review of methods of assessment. *J Oral Pathol Med* 26: 201-205.
19. Joseph BK (2002) Oral cancer: prevention and detection. *Med Princ Pract* 11: 1: 32-35.
20. Wien RO (2005) *Oral cancer*. Jatin P. Shah, Newell W. Johnson, John G. Batsakis, Martin Dunitz, Thieme Medical Publishers, Inc, New York, 2003, Head Neck 27:81-81.
21. Cowpe JG (1984) Quantitative exfoliative cytology of normal and abnormal oral mucosal squames: preliminary communication. *J R Soc Med* 77: 928-931.
22. Ramaesh T, Mendis BR, Ratnatunga N, Thattil RO (1998) Cytomorphometric analysis of squames obtained from normal oral mucosa and lesions of oral leukoplakia and squamous cell carcinoma. *J Oral Pathol Med* 27: 83-86.

23. Franklin CD, Smith CJ (1980) Stereological analysis of histological parameters in experimental premalignant hamster cheek pouch epithelium. *J Pathol* 130: 201-215.
24. Ogden GR, Wight AJ, Rice P (1999) Effect of alcohol on the oral mucosa assessed by quantitative cytomorphometry. *J Oral Pathol Med* 28: 216-220.
25. Mascre C, Ming-Wen F, Joly JG (1984) Morphologic changes of the esophageal mucosa in the rat after chronic alcohol ingestion. *Exp Pathol* 25: 147-153.
26. Ogden GR, Cowpe JG, Green MW (1990) Quantitative exfoliative cytology of normal buccal mucosa: effect of smoking. *J Oral Pathol Med* 19: 53-55.
27. Zain RB, Ikeda N, Gupta PC, Warnakulasuriya S, vanWyk CW, et al. (1999) Oral mucosal lesions associated with betel quid, areca nut and tobacco chewing habits: consensus from a workshop held in Kuala Lumpur, Malaysia, November 25-27, 1996. *J Oral Pathol Med* 28: 1-4.
28. Winn DM (2001) Tobacco use and oral disease. *J Dental Educ* 65: 306-312.
29. Koss LG, Melamed MR (2005) *Koss' diagnostic cytology and its histopathologic bases*. Fifth edition, Lippincott Williams & Wilkins, Wolters Kluwer, USA.
30. Cardillo M (1992) Ag-NOR technique in fine needle aspiration cytology of salivary gland masses. *Acta Cytol* 36: 147-151.
31. Cia EM, Trevisan M, Metze K (1999) Argyrophilic nucleolar organizer region (AgNOR) technique: a helpful tool for differential diagnosis in urinary cytology. *Cytopathol* 10: 30-39.
32. Chattopadhyay A, Ray JG, Caplan DJ (2002) AgNOR count as objective marker for dysplastic features in oral leukoplakia. *J Oral Pathol Med* 31: 512-517.
33. Webber LP, Pellicoli AC, Magnusson AS, Danilevicz CK, Bueno CC, et al. (2016) Nuclear changes in oral mucosa of alcoholics and crack cocaine users. *Hum Exp Tox* 35: 184-193.
34. Gonzalez Segura I, Secchi D, Carrica A, Barelo R, Arbelo D, et al. (2015) Exfoliative cytology as a tool for monitoring pre-malignant and malignant lesions based on combined stains and morphometry techniques. *J Oral Pathol Med* 44: 178-184.
35. Prasad H, Ramesh V, Balamurali PD (2010) Morphologic and cytomorphometric analysis of exfoliated buccal mucosal cells in diabetes patients. *J Cytol* 27: 113-117.
36. Ogden GR, Cowpe JG (1989) Quantitative cytophotometric analysis as an aid to the detection of recurrent oral cancer. *Br J Oral Maxillofac Surg* 27: 224-228.
37. Scuibba JJ (1999) Improving detection of precancerous and cancerous oral lesions. Computer-assisted analysis of the oral brush biopsy. U.S. Collaborative Oral CDx study group. *J Am Dent Assoc* 130: 1445-1457.