

# The Effect of Cross-Linked Hyaluronic Acid in Surgical Extraction of Impacted Mandibular Third Molars

Amr Bayoumi, Mohammed Nadershah\*, Ali Albandar, Batool Alsulaimani, Ibrahim Sankour, Lubabah Gadi, Omar Osama, Rawan Tayeb, Rufaida Quqandi, Weaam Dabroom and Yasser Merdad

Department of Oral and Maxillofacial Surgery, Faculty of Dentistry, King Abdulaziz University, KSA

\*Corresponding author: Mohammed Nadershah, Assistant Professor and Consultant, Oral & Maxillofacial Surgery, Faculty of Dentistry, King Abdulaziz University, Jeddah, Saudi Arabia, Tel: +966126401000; E-mail: [mnadershah@gmail.com](mailto:mnadershah@gmail.com)

Received: 01 Apr, 2018 | Accepted: 16 Apr, 2018 | Published: 24 Apr, 2018

**Citation:** Bayoum A, Nadershah M, Albandar A, Alsulaimani B, Sankour I, et al. (2018) The Effect of Cross-Linked Hyaluronic Acid in Surgical Extraction of Impacted Mandibular Third Molars. *Int J Dent Oral Health* 4(2): [dx.doi.org/10.16966/2378-7090.254](http://dx.doi.org/10.16966/2378-7090.254)

**Copyright:** © 2018 Bayoum A, et al. This is an open-access article distributed under the terms of the Creative Commons Attribution License, which permits unrestricted use, distribution, and reproduction in any medium, provided the original author and source are credited.

## Abstract

**Objectives:** The aim of the study was to evaluate the effectiveness of cross-linked Hyaluronic Acid (HA) gel on facial swelling, pain, and trismus after extraction of impacted mandibular third molars.

**Method and Materials:** This randomized, double-blinded, split-mouth clinical trial included 14 patients. For each patient, a combination of cross-linked HA with Gelfoam scaffold were randomly applied to one extraction site, while Gelfoam alone was applied to the other extraction site. Measurements of three facial reference points, pain and maximum mouth opening were recorded preoperatively, as well as on the 2<sup>nd</sup>, 4<sup>th</sup> and 7<sup>th</sup> days after the surgery.

**Results:** The scores for facial swelling, pain and trismus were the highest on the 2<sup>nd</sup> postoperative day and decreased gradually on the 4<sup>th</sup> to the 7<sup>th</sup> days in both groups. Cross-linked HA group demonstrated statistically significant reduction in swelling, pain, and trismus on the 7<sup>th</sup> postoperative day when compared to its control group ( $p < 0.05$ ).

**Conclusion:** The application of cross-linked HA after extraction of impacted mandibular third molars has a positive impact on postoperative swelling, pain and trismus after the extraction of impacted lower third molars.

**Keywords:** Hyaluronic acid; Third molar; Impacted teeth

## Introduction

Tooth impaction is defined as the failure of tooth eruption within its anticipated time frame. The most common impacted teeth in the oral cavity are the mandibular third molars [1]. The American Association of Oral and Maxillofacial Surgeons recommends removing impacted mandibular third molars that do not have enough space for their normal eruption at an early age, granting the patient the benefit of fast healing with minimal incidence of morbidity [1].

Patients 'quality of life (QoL) deteriorates in the first few days after surgical extraction of mandibular third molars due to postoperative manifestations such as facial swelling, pain, and trismus [2,3]. Multiple studies have demonstrated a beneficial effect of the postoperative use of corticosteroids and nonsteroidal anti-inflammatory drugs in reducing these manifestations [4,5]. Nevertheless, these medications may result in significant systemic side effects and are contraindicated in a subset of patients. These issues encouraged researchers to investigate the topical application of agents without systemic side effects, such as hyaluronic acid (HA) applied directly to the extraction sites.

Hyaluronic acid is a high molecular weight (generally, 50-8000 kilodalton), nonsulfated glycosaminoglycan (GAG) compound found throughout the body including skin, synovial joints, and periodontal tissues. It is also found in the capsular component of certain bacterial such as Streptococci and Staphylococci. These have been biotechnologically developed and are now a main source of commercial Hyaluronic acid. It is essential for wound healing during the inflammatory, granulation, and re-epithelialization stages [6,7]. Koray et al. reported that HA spray was more effective in the reduction of facial swelling, pain, and trismus after extraction of mandibular third molars when compared to benzydaminehydrochloride spray [8]. However, a study conducted in 2015 found that the use of HA in combination with collagen scaffold (Gelfoam) in extraction sockets did not significantly reduce the incidence of dry socket and postoperative pain [9].

Hyaluronic acid is naturally present in an unbound liquid form that is metabolized within twelve hours. In contrast, cross-linked HA has a gel consistency and a prolonged metabolism allowing it to last for up to seven days [10]. The effect of cross-linked HA gel on facial swelling, pain, and trismus after surgical extraction of impacted mandibular third molars has not been reported in the literature. This study aims to evaluate the effectiveness of cross-linked HA gel on facial swelling, pain, and trismus after surgical extraction of impacted mandibular third molars.

## Materials and Methods

The study design was a randomized, double-blind, split-mouth clinical trial conducted at King Abdulaziz University Dental Hospital (KAUDH). The Research Ethical Committee at KAUDH approved this study (proposal no. 021-15). Patients treated by undergraduate dental students at KAUDH were screened clinically and radio graphically using a panoramic radiograph. The inclusion criteria were as follows: healthy individuals, aged 25 to 40 years old, with bilateral symmetrical asymptomatic impacted mandibular third molars. Informed consent was obtained from each patient before they were enrolled in this study.

Preoperative assessment included measuring the maximum interincisal mouth opening (MMO) using a caliper, pain by visual analogue scale (VAS), and swelling using three reference points. These points were located at the tragus of the ear, corner of the mouth, and angle of the mandible, forming a triangle in which the surface area was calculated.

The same oral and maxillofacial surgeon performed all surgical procedures. A four-week gap was allowed between the surgical extraction of the right and left mandibular third molars of the same patient. Patients and examiners were blinded to the allocation of the cross-linked HA gel throughout the study. Inferior alveolar nerve block, lingual nerve block, and long buccal nerve infiltration were performed using 2% Lidocaine with 1: 100,000 Epinephrine. A three-cornered full-thickness mucoperiosteal flap was reflected to access the impacted mandibular third molars. After the surgical extraction was completed, the clinician injected 0.33 ml cross-linked HA gel (HyaDENT BG®, 20 mg HA/ml) into a Gelfoam cube and placed it in the test extraction socket. On the contra lateral side, plain Gelfoam was placed in the control extraction site. Then, the flap was repositioned and sutured using 3-0 Vicryl sutures. A gauze pressure packs were applied to the surgical site to assist in hemostasis, and routine postoperative instructions were given to the patient. Additionally, Amoxicillin/Clavulanic acid tablets (625mg every eight hours for five days) and Paracetamol tablets (1000mg every eight hours for five days) were prescribed for each patient.

Facial swelling, pain, and trismus were measured, as previously described, on the 2nd, 4th, and seventh postoperative days. There were four follow-up examiners. Each examiner

measured both sides of the same patient. The examiners were calibrated for measuring technique. Data were assessed using SPSS (20.0 versions). Paired Student's t-test and repetitive measure tests were used for parametric constant data. A statistical significance level of  $P < 0.05$  for the 95% confidence interval was selected.

## Results

Fourteen patients (seven males, seven females) met the inclusion criteria for this study. The mean age was  $25.25 \pm 3.1$  years (range: 22-32 years). Facial swelling was significantly increased on the 2<sup>nd</sup> and 4<sup>th</sup> postoperative days in both groups, as well as the control group on the 7<sup>th</sup> day when compared to their preoperative measurements ( $P < 0.001$ ). The study group on the 7<sup>th</sup> postoperative day did not show a significant difference compared to its preoperative measurements. On the 7<sup>th</sup> postoperative day, the facial swelling of the study group was significantly lower than that of the control ( $P < 0.05$ ) (Graph 1).

The mean pain VAS scores were at their highest on the 2<sup>nd</sup> postoperative day and decreased gradually in both groups on the 4<sup>th</sup> and seventh postoperative days. The mean pain VAS scores were lower for the study group compared to the control on the 7<sup>th</sup> postoperative day ( $P < 0.05$ ) (Graph 2).

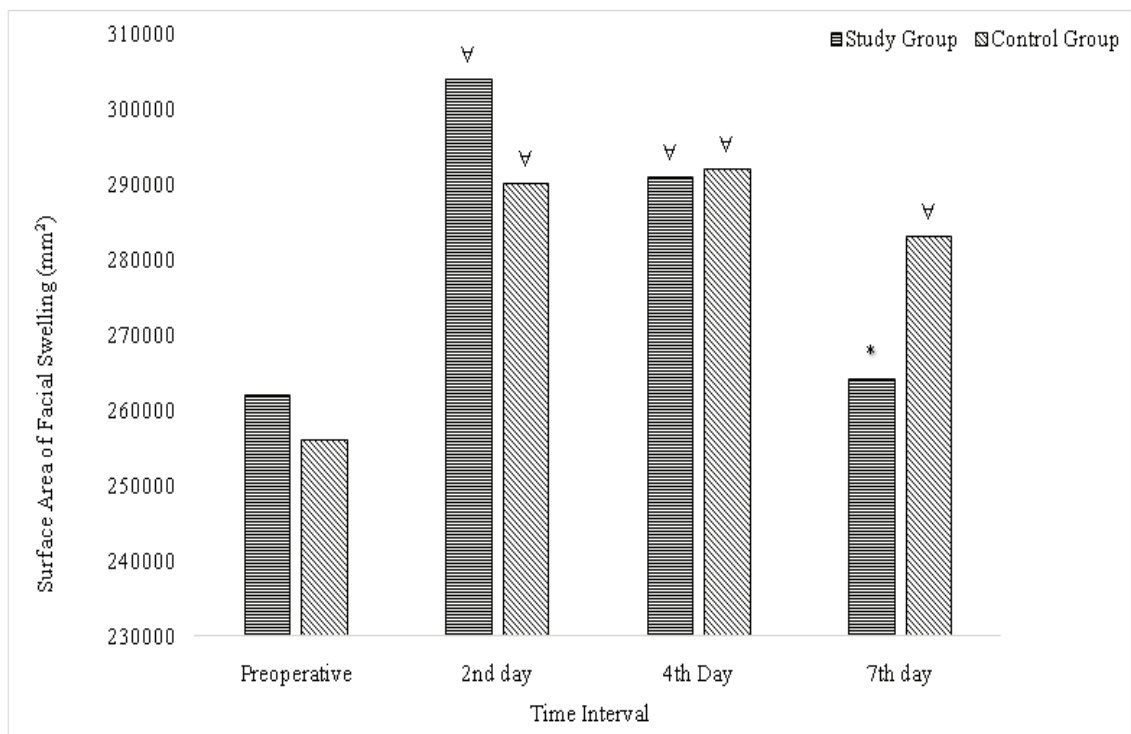
The mean MMO was significantly lower on each postoperative day compared to preoperative measurements ( $P < 0.001$ ), and it increased gradually throughout the study period. The study group recorded a statistically significant improvement in MMO compared to the control group on the 7<sup>th</sup> postoperative day ( $P < 0.001$ ) (Graph 3).

None of the patients experienced any other surgical complications or systemic side effects from the drug regimen.

## Discussion

Patients' QoL deteriorates within the first week after extraction of impacted mandibular third molars [2,3]. Different materials with different application techniques were applied to reduce facial swelling, pain, and trismus after the extraction of impacted mandibular third molars. Hyaluronic acid has been used in many fields to wound healing and pain relief without side effects [4,8,10-14]. Hanci and Altun reported on its application post-tonsillectomy for pain relief [15].

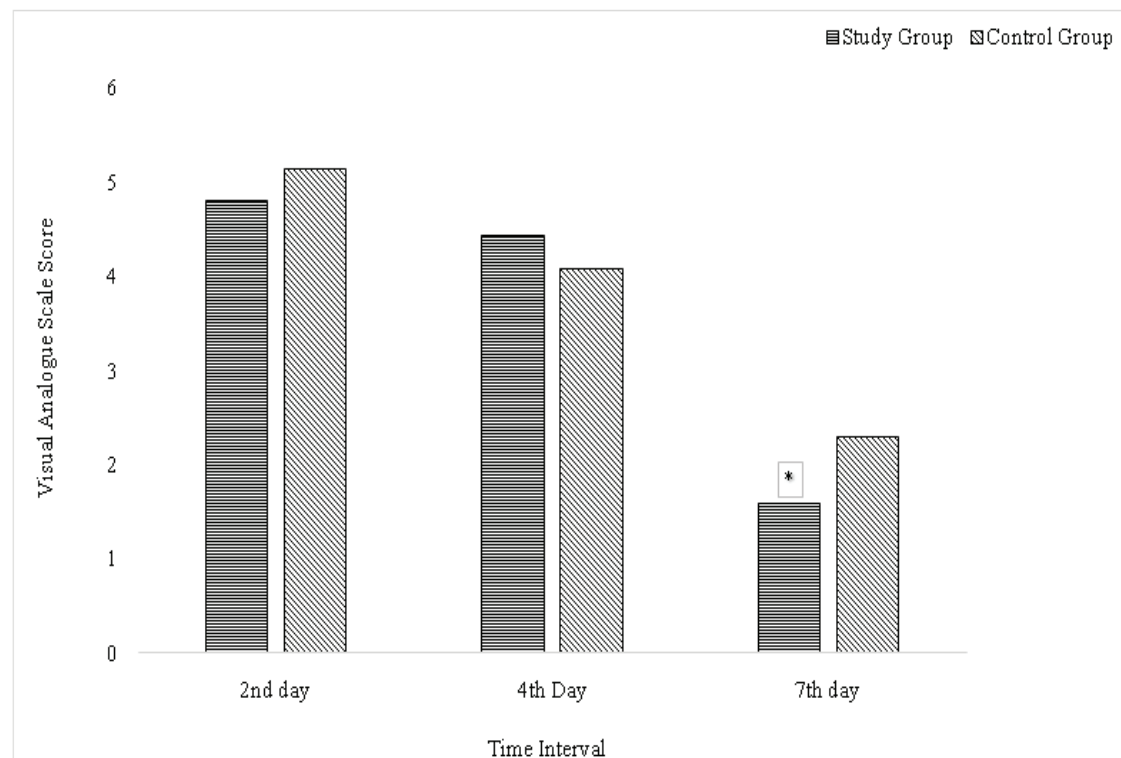
The main drawback of unbound HA was the rapid washout within the first twelve hours. Cross-linking HA with polymer can prolong its duration and delay its washout for up to seven days, thus increasing the availability of HA at the trauma site for a week and reducing postoperative symptoms [11,12,16]. Chang et al. reported improved bone healing *in vitro* study using cross-linked HA in a calvarian bone defect model [17]. Moreover, the uses of cross-linked HA have been recognized in various sites and conditions in the oral cavity. Lee et al. stated that HA gel applied topically on oral ulcers improved subjectively and objectively the number of ulcers, healing period, and (VAS) for pain [18]. Romeo et al. reported that the



**Graph 1:** Comparison of Clinical Parameter (Swelling) Between Groups on Different Time Intervals.

\*Significant difference compared to control (P<0.05)

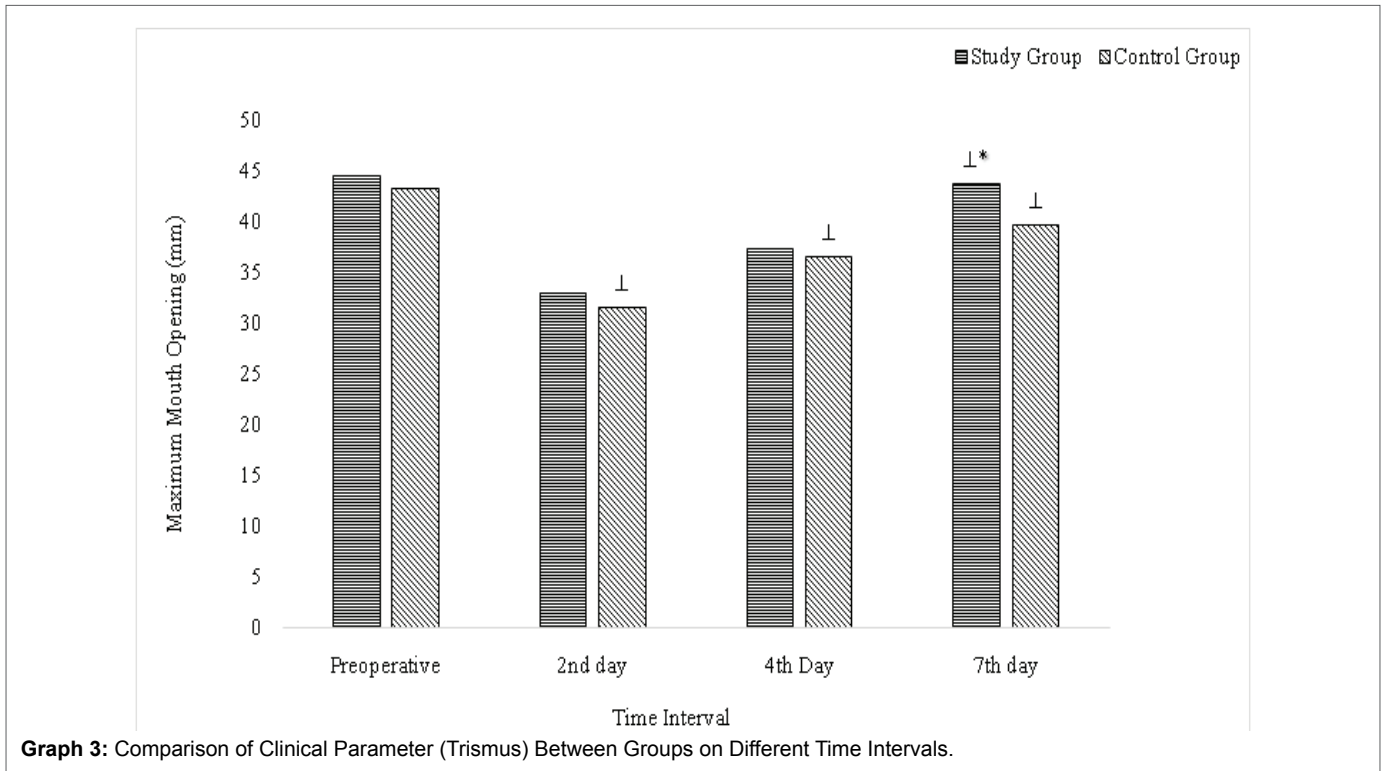
∇Significant increase compared to preoperative measurements (P<0.001)



**Graph 2:** Comparison of Clinical Parameter (Pain) Between Groups on Different Time Intervals.

\*Significant difference compared to control (P<0.05)

⊥Significant decrease compared to preoperative measurements (P<0.001)



topical application of HA gel in combination with amino acids enhanced healing by secondary intention in patients who had an excisional biopsy of different oral tissues [19]. Gontiya et al. stated that the subgingival application of cross-linked HA along with SRP in patients exhibiting chronic periodontitis improved the gingival and bleeding indices in contrast to control sites [20]. On the other hand, Gocmen et al. reported that HA gel prolonged bleeding time and increased swelling in the early postoperative period (2-3 days) after extraction of vertical half-impacted mandibular third molars [21]. This study was designed to evaluate the effect of cross-linked HA gel in the reduction of facial swelling, pain, and trismus following the surgical extraction of impacted mandibular third molars.

The results of this study revealed that the injection of cross-linked HA gel in the extraction site reduced facial swelling, pain, and trismus on the 7<sup>th</sup> postoperative day. Surgical extraction of an impacted mandibular third molar usually results in fluid accumulation at the extraction site. Consequently, facial swelling reaches its peak on the 1<sup>st</sup> and second postoperative days and then gradually resolves [22]. Our results revealed that cross-linked HA gel aided in quicker resolution of facial swelling by the 7<sup>th</sup> postoperative day. This finding might be attributed to the hydrophilic nature of cross-linked HA gel that rapidly increases fluid at the surgical site, which reaches its peak on the 3<sup>rd</sup> postoperative day and subsides by the 7<sup>th</sup> postoperative day [23]. Koray et al. reported that HA spray after third molar extraction reduced facial swelling on the 2<sup>nd</sup> postoperative day without affecting pain VAS scores. However, the surgeon and patients were blinded in their study to the allocation of the HA spray, but the follow up examiner was not. In addition,

the application technique was different as they applied the HA spray superficially on the wound [8].

A standing dose of Paracetamol was prescribed to reduce postoperative pain with minimal effect on swelling measurements for both groups. The mean pain VAS scores peaked on the day following the procedure. By the 7<sup>th</sup> postoperative day, they were significantly lower in the study group. In contrast, Bayoumi et al. reported that non-cross-linked HA had no effect on pain or dry socket following tooth extraction [9]. The non-cross-linked HA used was estimated to dissolve in the first twelve hours. This phenomenon was avoided in our study by using a cross-linked HA gel, which increased the gel consistency, slowing down its metabolism and increasing its duration up to seven days [11,12,16].

Trismus results from fluid accumulation in the fascia limiting patients' ability to function properly during eating and speaking [24]. The present study showed that cross-linked HA gel did not affect trismus in the 2<sup>nd</sup> and fourth postoperative day. However, it resulted in a return to baseline MMO on the 7<sup>th</sup> postoperative day in the study group but not the control group. In contrast, Koray et al. reported that non-cross-linked HA spray reduced trismus on the 2<sup>nd</sup> postoperative day, but both groups were back to baseline MMO by the 7<sup>th</sup> postoperative day [8]. This may be due to the application technique: the HA spray was given to the patients, and they were instructed to use it three times daily, two pumps each time [8].

Alveolar osteitis and postoperative infections are the most common complications after extraction of mandibular third molars, with a rate of 25-30% and 2-12% respectively [25,26].



To prevent these complications, antibiotics were prescribed to both groups. Postoperative complications did not occur for any patient included in this study. The limitations of the present study include a small sample size and multiple follow-up examiners.

## Conclusion

The application of cross-linked HA gel in the surgical site of an extracted impacted mandibular third molar reduces patients' facial swelling, pain, and trismus. Further studies need to be conducted on larger sample size to confirm these results.

## References

1. Knaus H, Haberl H, Thomale U (2010) Clinical Paper. *Am Assoc Oral Maxillofac Surg*.
2. Lim D, Ngeow WC (2017) A Comparative Study on the Efficacy of Submucosal Injection of Dexamethasone Versus Methylprednisolone in Reducing Postoperative Sequelae After Third Molar Surgery. *J Oral Maxillofac Surg* 75: 2278-2286.
3. McGrath C, Comfort MB, Lo ECM, Luo Y (2003) Changes in life quality following third molar surgery - The immediate postoperative period. *Br Dent J* 194: 265-268.
4. Herrera-Briones FJ, Prados Sánchez E, Reyes Botella C, Vallecillo Capilla M (2013) Update on the use of corticosteroids in third molar surgery: Systematic review of the literature. *Oral Surg Oral Med Oral Pathol Oral Radiol* 116: e342-51.
5. Yamaguchi A, Sano K (2013) Effectiveness of preemptive analgesia on postoperative pain following third molar surgery: Review of literatures. *Jpn Dent Sci Rev* 49: 131-138.
6. Prestwich GD (2011) Hyaluronic acid-based clinical biomaterials derived for cell and molecule delivery in regenerative medicine. *J Control Release* 155: 193-199.
7. Laurent TC (1998) The chemistry, biology, and medical applications of hyaluronan and its derivatives. 341 p.
8. Koray M, Ofluoglu D, Onal EA, Ozgul M, Ersev H, et al. (2014) Efficacy of hyaluronic acid spray on swelling, pain, and trismus after surgical extraction of impacted mandibular third molars. *Int J Oral Maxillofac Surg* 43: 1399-1403.
9. Amr M Bayoumi, Ahmed Jan WA-A, Shakir M (2015) The Effects of Using Hyaluronic Acid on the Extraction Sockets. *Int J Dent Oral Heal* 2.
10. Williams DL, Wirostko BM, Gum G, Mann BK (2017) Topical cross-linked HA-based hydrogel accelerates closure of corneal epithelial defects and repair of stromal ulceration in companion animals. *Investig Ophthalmol Vis Sci* 58: 4616-4622.
11. Snibson GR, Greaves JL, Soper NDW, Tiffany JM, Wilson CG, et al. (1992) Ocular surface residence times of artificial tear solutions. *Cornea* 11: 288-293.
12. Williams DL, Mann BK (2014) Efficacy of a crosslinked hyaluronic acid-based hydrogel as a tear film supplement: A masked controlled study. *PLoS One* 9: 1-6.
13. Hammad HM, Hammad MM, Abdelhadi IN, Khalifeh MS (2011) Effects of topically applied agents on intra-oral wound healing in a rat model: A clinical and histomorphometric study. *Int J Dent Hyg* 9: 9-16.
14. Kaczmarzyk T, Wichlinski J, Stypulkowska J, Zaleska M, Woron J (2010) Preemptive effect of ketoprofen on postoperative pain following third molar surgery. A prospective, randomized, double-blinded clinical trial. *Int J Oral Maxillofac Surg* 39: 647-652.
15. Hancı D, Altun H (2015) Effectiveness of hyaluronic acid in post-tonsillectomy pain relief and wound healing: A prospective, double-blind, controlled clinical study. *Int J Pediatr Otorhinolaryngol* 79: 1388-1392.
16. Mochizuki H, Yamada M, Hato S, Nishida T (2008) Fluorophotometric measurement of the precorneal residence time of topically applied hyaluronic acid. *Br J Ophthalmol* 92: 108-111.
17. Chang YL, Lo YJ, Feng SW, Huang YC, Tsai HY, et al. (2016) Bone healing improvements using hyaluronic acid and hydroxyapatite/beta-Tricalcium phosphate in combination: An animal study. *Biomed Res Int*.
18. Lee JH, Jung JY, Bang D (2008) The efficacy of topical 0.2% hyaluronic acid gel on recurrent oral ulcers: Comparison between recurrent aphthous ulcers and the oral ulcers of Behçet's disease. *J Eur Acad Dermatology Venereol* 22: 590-595.
19. Romeo U, Libotte F, Palaia G, Galanakis A, Gaimari G, et al. (2014) Oral soft tissue wound healing after laser surgery with or without a pool of amino acids and sodium hyaluronate: a randomized clinical study. *Photomed Laser Surg* 32: 10-16.
20. Gontiya G, Galgali SR (2012) Effect of hyaluronan on periodontitis: A clinical and histological study. *J Indian Soc Periodontol* 16: 184-192.
21. Gocmen G, Aktop S, Tuzuner B, Goker B, Yarat A (2017) Effects of hyaluronic acid on bleeding following third molar extraction. *J Appl Oral Sci* 25: 211-216.
22. de Santana-Santos T, de Souza-Santos JAS, Martins-Filho PRS, da Silva LCF, de Oliveira e Silva ED, et al. (2013) Prediction of postoperative facial swelling, pain and trismus following third molar surgery based on preoperative variables. *Med Oral Patol Oral Cir Bucal* 18: e65-70.
23. Longaker MT, Chiu ES, Adzick NS, Stern M, Harrison MR, et al. (1991) Studies in fetal wound healing: V. A prolonged presence of hyaluronic acid characterizes fetal wound fluid. *Ann Surg* 213: 292-296.
24. Shugars DA, Gentile MA, Ahmad N, Stavropoulos MF, Slade GD, et al. (2006) Assessment of Oral Health-Related Quality of Life Before and After Third Molar Surgery. *J Oral Maxillofac Surg* 64: 1721-1730.
25. Ren Y-F, Malmstrom HS (2007) Effectiveness of Antibiotic Prophylaxis in Third Molar Surgery: A Meta-Analysis of Randomized Controlled Clinical Trials. *J Oral Maxillofac Surg* 65: 1909-1921.
26. Blum IR (2002) Contemporary views on dry socket (alveolar osteitis): A clinical appraisal of standardization, aetiopathogenesis and management: A critical review. *Int J Oral Maxillofac Surg* 31: 309-317.