

# Bone Regrowth and Healing of Periapical Lesions Nine Months after Removal of Silver Points and Retreatment with the GentleWave Procedure

Randy W Garland\*

Doctor of Dental Surgery, Private Practice, Encinitas, California, USA

\*Corresponding author: Randy W Garland, DDS, 531 Encinitas Blvd, Suite 101, Encinitas, California 92024, USA, Tel: (760) 944-0048; Fax (760) 944-1432; E-mail: [dr.rwgarland@gmail.com](mailto:dr.rwgarland@gmail.com)

Received date: 30 May 2017; Accepted date: 03 Jul 2017; Published date: 07 Jul 2017.

Citation: Garland RW (2017) Bone Regrowth and Healing of Periapical Lesions Nine Months after Removal of Silver Points and Retreatment with the GentleWave Procedure. *Int J Dent Oral Health* 3(4): doi <http://dx.doi.org/10.16966/2378-7090.237>

Copyright: © 2017 Garland RW. This is an open-access article distributed under the terms of the Creative Commons Attribution License, which permits unrestricted use, distribution, and reproduction in any medium, provided the original author and source are credited.

## Abstract

**Introduction:** Endodontists occasionally encounter patients who were treated with silver points from prior root canal therapy (RCT). Obturation with silver points became part of endodontic therapy in the 1930s, however they are no longer recommended as they do not provide complete obturation and have been shown to be associated with negative clinical sequelae. When silver points begin to fail or produce correlated pathological changes, retreatment is indicated.

**Objective:** This case report describes an elderly patient who presented for retreatment due to a failing silver point RCT. The patient was experiencing biting tenderness in the lower right quadrant, and radiographic examination revealed prior silver point RCT with periapical lesions on the mesial and distal roots of the right mandibular first molar. Based on the clinical and radiographic findings, a diagnosis of acute apical periodontitis was made. The treating endodontist chose to provide retreatment with the GentleWave Procedure, which uses multisonic energy to clean and disinfect the root canal system and any anatomical complexities. This procedure was chosen as the optimal choice for the prevention of reinfection and for the removal of any residual bacteria after the silver point removals.

**Results:** The patient was successfully retreated and post-procedure paper points did not show the typical residue and metallic debris that is seen after silver point removal. Nine-month follow-up examination and diagnostic imaging showed full resolution of the apical periodontitis with significant bone regrowth.

**Conclusion:** Root canal retreatment can prevent unnecessary extraction of a root-filled tooth with apical periodontitis. In this case report, the treating endodontist provided retreatment to an elderly patient with acute apical periodontitis due to failing RCT with silver point obturation. Retreatment using the GentleWave Procedure led to a successful outcome and resolution of the apical periodontitis with significant bone regrowth over a 9-month recall period.

**Keywords:** Root canal therapy; Silver point retreatment; GentleWave Procedure; Multisonic Ultracleaning; Apical periodontitis

## Introduction

Endodontists occasionally encounter patients who were treated with silver points from prior root canal therapy (RCT). Obturation with silver points became part of endodontic therapy in the 1930s [1]. However, the American Association of Endodontists recommends against the use of silver points [2], as they have been shown to be associated with negative clinical sequelae [3-6]. Silver points do not provide comprehensive conformity within the root, and usually corrode over time [1,3]. When silver points begin to fail or produce correlated pathological changes, extraction or retreatment is indicated.

Silver points were initially recommended as a method of obturating root canals because of their rigidity and simplicity of placement [5]. However, over time it became apparent that silver points were problematic for RCT due to ongoing corrosion of the points and associated toxic exposures to the patient [7]. Past research has shown that corrosion occurs from exposure to tissue fluids, and this corrosive process can cause argyrosis and lead to periradicular inflammation [1,2].

Retreatment which involves removal of silver points is usually more technically demanding than primary RCT [8]. The removal procedure requires the creation of appropriate space around the silver point, the skilled use of ultrasonic vibration, specialized instruments, and eventual

removal [8]. After removal, the successful retreatment must include complete debridement of the root canal system and effective obturation. Since improper cleaning and obturation can lead to endodontic failure, it is vital that endodontic treatment and retreatments ensure a successful outcome for the patient.

This case report describes a 71-year-old patient who presented for retreatment due to a failing silver point root canal treatment with acute apical periodontitis. The treating endodontist chose to provide retreatment with the GentleWave Procedure, a novel device which uses multisonic energy to clean and disinfect the entire root canal system regardless of root system complexities [9].

## Case Presentation

A 71-year-old female presented with biting tenderness in the lower right quadrant. The treating endodontist reviewed the patient's medical history and deemed it non-contributory. Clinical examination of the mandibular right first molar (#30) showed tenderness to bite, with a mildly painful response to percussion and palpation. Radiographic examination revealed a previously placed porcelain-fused-to-metal (PFM) crown and prior silver point RCT with periapical lesions on the mesial and distal roots (Figure 1). Based on the clinical and radiographic findings, a diagnosis of acute apical periodontitis was made. The treatment plan was reviewed with the

patient, who agreed and consented to retreatment with the GentleWave Procedure, a device which uses multisonic energy to clean and disinfect the entire root canal system simultaneously [9-13]. This procedure was chosen as the optimal choice for the prevention of reinfection and for the removal of any residual bacteria after the silver point removal.

The patient received local anesthesia per standard techniques, and a dental dam was applied to isolate the tooth for endodontic treatment. A conservative straight line access was prepared, including removal of all pulp horns, overhangs and ledges.

Visualization of the pulp chamber floor revealed three distinct canals with previous silver point obturation, whereby each point was cut off at the orifice of the canal. Due to difficulties with removal of the points, ultrasonics (Satelec® Ultrasonic Tip ET20D, Acteon®, Eiffel, France) were utilized to create a narrow trough next to each silver point, then a Hedström file was placed laterally to the silver points until it bound. The Hedström file was turned to engage the silver point and then pulled for removal (Figure 2).

To maximize the preservation of existing tooth structure, orifice shapers or Gates Glidden Drills (Kerr™, Orange, CA) were not used during the instrumentation process. EdgeFile® rotary files X3 size N1 (EndoEdge™, Albuquerque, New Mexico) were utilized to minimally shape the canals merely to facilitate a fluid path and provide room for obturation.

A temporary platform was created to maintain a sealed environment for optimum MultiSonic Ultracleaning™ during the GentleWave Procedure. The GentleWave System was employed to remove pulp tissue remnants, debris, smear layer, and bacteria from the entire root canal system. The

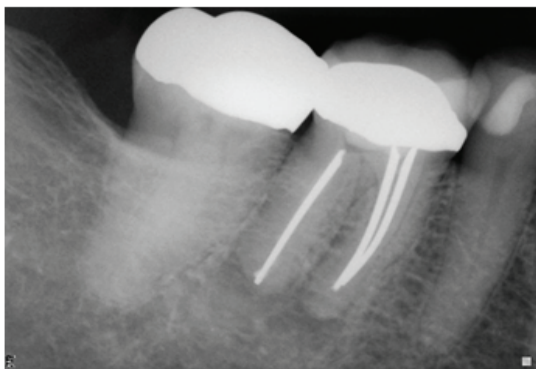
GentleWave Procedure was chosen over standard endodontic treatments for this case due to its ability to thoroughly clean and disinfect the entire root canal without removing excessive dentin.

After the GentleWave Procedure, paper points were used to dry each canal. It was noted that the paper points were clean when removed, and that there was no presence of black sediment as typically seen after silver point root canal retreatment. Obturation was completed using a warm vertical technique with gutta-percha and AH Plus® sealer (Dentsply, Konstanz, Germany).

The patient reported no discomfort during or after the procedure. Immediate post-procedure radiographic and cone-beam computed tomography (CBCT) (Carestream CS 9000, Carestream Health, Rochester, NY) imaging showed complete obturation without complications (Figures 3 and 4). At a nine-month follow-up visit, clinical evaluation showed the tooth was asymptomatic, and CBCT imaging showed significant bone regrowth and periradicular healing (Figure 5).

## Discussion

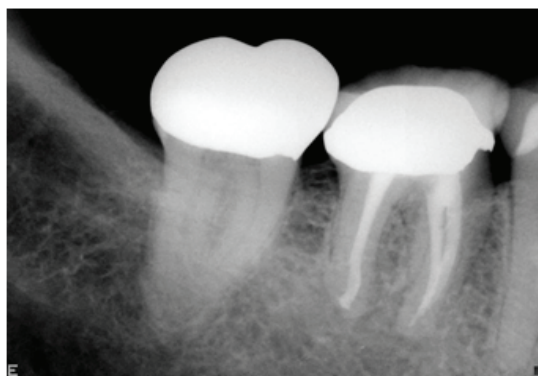
It has been previously established that periradicular disease is more prevalent in root-filled teeth [14] and that the type and quality of root filling can be a contributing factor [15,16]. Patients with silver point RCT are often candidates for retreatment, since endodontic success can be compromised by the corrosive effects of the silver points, and this corrosive process can result in the release of highly cytotoxic contaminants



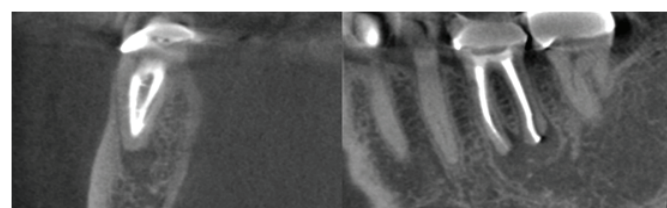
**Figure 1:** Pre-Procedure Radiograph Showing the Previously Placed Silver Points



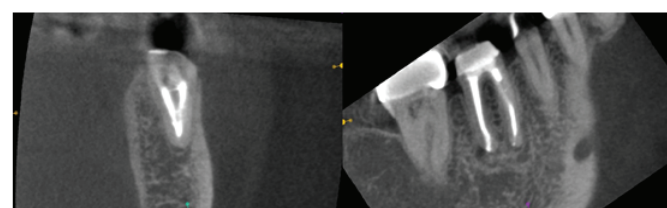
**Figure 2:** Removed Silver Points. Three silver points were removed, two are shown here



**Figure 3:** Radiograph Taken after the GentleWave Retreatment Procedure



**Figure 4:** Post-Procedure CBCT Image, Immediate



**Figure 5:** Post-Procedure CBCT Image, 9-Month Follow-Up

and potentially compromise the patient's health [3]. For these and other reasons, silver point RCT is no longer recommended [2] and retreatment is an option where indicated.

In this case report, a patient presented with failing silver points and was retreated with the GentleWave Procedure, a novel device on the endodontic market which has been shown to demonstrate improved debridement efficacy in the root canal system [9-11,13]. Although silver points typically leave a cytotoxic residual metallic debris in the canals [5,17,18], post-treatment evaluation in this case showed no sediment residue. Generally, removing the corrosive remnants associated with silver point removal can be an arduous and lengthy process, though in this case the GentleWave Procedure was able to remove the debris without protracted procedure time. This may in part be explained by the GentleWave System's ability to provide rapid dissolution of tissue and more effective debridement as compared to standard RCT [13]. The GentleWave System cleans and disinfects all root canals simultaneously through advanced fluid dynamics, acoustics, and tissue dissolution chemistry [9,12,19]. This procedure also preserves dentin, which is crucial since greater clinical success in endodontics has been correlated to the maintenance of the patient's original canal form and lack of any canal irregularities [20]. Traditional apical enlargement is known to not only cause various complications like apical transportation, ledges, and instrument separation, but also causes greater removal of natural tooth structure which weakens the tooth and thereby increases the likelihood of root fractures [21].

As a prognostic measure, the present case had CBCT imaging conducted immediately after the GentleWave Procedure and again at 9-months follow-up. Using CBCT imaging as a metric for outcomes allowed for objective evaluation of periradicular healing and bone regrowth after removal of the silver points, as the use of CBCT has been proven to yield high sensitivity in measuring periradicular lesions and bone levels [22,23]. Remarkably, the patient experienced significant healing at 9-months post-treatment, which is an unusual finding particularly given the patient's age. Past research has shown that the average time required for a periapical lesion to heal is just under 12 months, with longer healing periods required for patients over 40 years of age [24]. Although patient-specific factors also influence healing, it's reasonable to presume that retreatment in this patient facilitated healing of the prior endodontic disease and stimulated the regrowth of bone where the prior lesions had been. This return of periradicular health and normal bone levels was likely a direct result of the retreatment with the GentleWave Procedure, likely due to complete debridement of the canal system, the removal of the failing silver points and associated debris, and effective obturation.

Past meta-analyses of endodontic treatment studies have reported success rates of 97% for the GentleWave System [12], and recent research has shown that endodontic retreatment using more modern-day techniques leads to improved quality of life for patients [25]. The elderly patient in this report was able to have a failing, outdated RCT retreated and to obtain resolution of acute apical periodontitis within 9 months after retreatment with the GentleWave Procedure, while also preserving the existing tooth structure. Since retreatment of endodontically failing teeth is generally preferred over extraction, clinicians may consider the GentleWave Procedure as a preferred retreatment option.

## Conclusion

Root canal retreatment can prevent unnecessary extraction of a root-filled tooth with apical periodontitis [26]. In this case report, the treating endodontist provided retreatment to a patient with acute apical periodontitis due to failing silver points. Extraction of the silver points necessitated retreatment of the root canal system, and the GentleWave Procedure was chosen to thoroughly clean and disinfect the canals and

to remove any residual metallic debris. Retreatment using this method led to a successful outcome and resolution of the apical periodontitis with significant bone regrowth in an unexpectedly short amount of time, suggesting that the GentleWave Procedure is an appropriate and effective retreatment option for those with silver points.

## Acknowledgement

The authors would like to thank Kathleen Pillsbury Hopf for medical writing support.

## Disclosure

Dr. Randy Garland is a consultant for Sonendo Inc.

## References

- Gulati S, Sumanthini MV, Shenoy V (2012) Retreatment of Silver Point Obturation: A Case Report and an Overview. *J Contemp Dent* 2: 114-118.
- American Association of Endodontics (2013) Position Statement: Use of Silver Points.
- Brady JM, del Rio CE (1975) Corrosion of endodontic silver cones in humans: a scanning electron microscope and X-ray microprobe study. *J Endod* 1: 205-210.
- Zielke DR, Brady JM, del Rio CE (1975) Corrosion of silver cones in bone: a scanning electron microscope and microprobe analysis. *J Endod* 1: 356-360.
- Chana H, Briggs P, Moss R (1998) Degradation of a silver point in association with endodontic infection. *Int Endod J* 31: 141-146.
- Harris WE (1971) Disintegration of a Silver Point: Report of Case. *J Am Dent Assoc* 83: 868-872.
- Margelos J, Eliades G, Palaghias G (1991) Corrosion pattern of silver points *in vivo*. *J Endod* 17: 282-287.
- Ford TR, Rhodes JS (2004) Root canal retreatment: 2. Practical solutions. *Dent Update* 31: 97-102.
- Molina B, Glickman G, Vandrang P, Khakpour M (2015) Evaluation of Root Canal Debridement of Human Molars Using the GentleWave System. *J Endod* 41: 1701-1705.
- Vandrang P, Basrani B (2015) Multisonic Ultracleaning™ in Molars with the GentleWave™ System. *Oral Health* 72-86.
- Vandrang P (2016) Evaluating Penetration Depth of Treatment Fluids into Dentinal Tubules Using the GentleWave® System. *Dentistry* 6: 366.
- Sigurdsson A, Garland RW, Le KT, Woo SM (2016) 12-month Healing Rates after Endodontic Therapy Using the Novel GentleWave System: A Prospective Multicenter Clinical Study. *J Endod* 42: 1040-1048.
- Haapasalo M, Wang Z, Shen Y, Curtis A, Patel P, et al. (2014) Tissue dissolution by a novel multisonic ultracleaning system and sodium hypochlorite. *J Endod* 40: 1178-1181.
- López-López J, Jané-Salas E, Estrugo-Devesa A, Castellanos-Cosano L, Martín-González J, et al. (2012) Frequency and distribution of root-filled teeth and apical periodontitis in an adult population of Barcelona, Spain. *Int Dent J* 62: 40-46.
- Peters LB, Lindeboom JA, Elst ME, Wesselink PR (2011) Prevalence of apical periodontitis relative to endodontic treatment in an adult Dutch population: a repeated cross-sectional study. *Oral Surg Oral Med Oral Pathol Oral Radiol Endod* 111: 523-528.
- Kim S (2010) Prevalence of apical periodontitis of root canal-treated teeth and retrospective evaluation of symptom-related prognostic factors in an urban South Korean population. *Oral Surg Oral Med Oral Pathol Oral Radiol Endod* 110: 795-799.

17. Seltzer S, Green DB, Weiner N, DeRenzis F (2004) A scanning electron microscope examination of silver cones removed from endodontically treated teeth. 1972. *J Endod* 30: 463-474.
18. Zmener O, Dominquez FV (1985) Corrosion of silver cones in the subcutaneous connective tissue of the rat: a preliminary scanning electron microscope, electron microprobe, and histological study. *J Endod* 11: 55-61.
19. Shon WJ (2016) Introducing the GentleWave System. *Restor Dent Endod* 41: 235.
20. da Silva Limoeiro AG, Dos Santos AH, De Martin AS, Kato AS, Fontana CE, et al. (2016) Micro-Computed Tomographic Evaluation of 2 Nickel-Titanium Instrument Systems in Shaping Root Canals. *J Endod* 42: 496-499.
21. Haapasalo M, Endal U, Zandi H, Coil JM (2005) Eradication of endodontic infection by instrumentation and irrigation solutions. *Endodontic Topics* 10: 77-102.
22. Dutta A, Smith-Jack F, Saunders WP (2014) Prevalence of periradicular periodontitis in a Scottish subpopulation found on CBCT images. *Int Endod J* 47: 854-863.
23. Estrela C, Bueno MR, Leles CR, Azevedo B, Azevedo JR (2008) Accuracy of cone beam computed tomography and panoramic and periapical radiography for detection of apical periodontitis. *J Endod* 34: 273-279.
24. Azim AA, Griggs JA, Huang GT (2016) The Tennessee study: factors affecting treatment outcome and healing time following nonsurgical root canal treatment. *Int Endod J* 49: 6-16.
25. He J, White RK, White CA, Schweitzer JL, Woodmansey KF (2017) Clinical and Patient-centered Outcomes of Nonsurgical Root Canal Retreatment in First Molars Using Contemporary Techniques. *J Endod* 43: 231-237.
26. Ford TR, Rhodes JS (2004) Root canal retreatment: I. Case assessment and treatment planning. *Dent Update* 31: 34-39.