

Peripheral Cemento- Ossifying Fibroma – A Case Report with Unusual Presentation

Saurabh Arya*, Krishnan Sriram, and Anshul Jain

HP Govt. Dental College and Hospital Shimla, 171001, Himachal Pradesh, India

*Corresponding author: Saurabh Arya, HP Govt. Dental College and Hospital Shimla, 171001, Himachal Pradesh, India, E-mail: sourav.arya@gmail.com

Received date: 28 July 2015; Accepted date: 17 Sep 2015; Published date: 23 Sep 2015.

Citation: Arya S, Sriram K, Jain A (2015) Peripheral Cemento- Ossifying Fibroma – A Case Report with Unusual Presentation. Int J Dent Oral Health 1(4): doi <http://dx.doi.org/10.16966/2378-7090.131>

Copyright: © 2015 Arya S, et al. This is an open-access article distributed under the terms of the Creative Commons Attribution License, which permits unrestricted use, distribution, and reproduction in any medium, provided the original author and source are credited.

Abstract

Peripheral cemento-ossifying fibroma (PCOF) is a reactive neoplasm and presents itself as a gingival overgrowth. It most commonly arises from the periosteum/periodontal ligament. It comprises 9% of all gingival growths and predominantly affects adolescents and young adults. A number of factors have been implicated in the pathogenesis of PCOF including trauma, local irritation such as calculus, ill fitting dentures or faulty restorations. We report a rare case of PCOF of the maxilla in a 4 year old child with previous history of flap surgery in relation to the unerupted tooth. Clinicians and oral and maxillofacial surgeons must be aware of such lesions occurring in the maxilla and must consider it in the differential diagnosis in the appropriate clinical setting.

Introduction

Benign fibro osseous often present themselves as an epulis like growth. Cemento ossifying fibroma is an encapsulated lesion consisting of fibrous tissue containing variable amounts of mineralized material resembling bone, cementum or both [1]. It accounts for 3.1% of all tumours and 9.6% of all gingival lesions and originates from the periosteal cells or periodontal ligament [2]. The pathogenesis of peripheral cemento ossifying fibroma can be conceptually explained as follows- 1. Dystrophic calcification or bone formation as a result of irritation of the periodontal/periosteal membrane 2. Fibrosis of the granulation tissue [3]. Hormonal influences may explain the high incidence of peripheral cemento ossifying fibroma in females. Peripheral cemento ossifying fibroma presents as a pedunculated nodular mass less than 2 cm in size and originating in the interdental papilla of the gingiva. Surgical excision forms the mainstay treatment of PCOF.

Report of a Case

A patient aged 4 years reported with a complaint of growth in the upper anterior region of the jaw with duration of 6 months (Figures 1 and 2). History revealed that the growth started following a flap surgery done in relation to unerupted tooth in the region. The growth was painless and patient had not undergone any treatment for the same.

On examination, a single ovoid growth was evident in maxillary anterior region displacing the tooth 51 and 61. The tooth 51 was protruding from the centre of the growth. A calcified bone-like structure was evident on the mesial aspect of 51. The surface of the growth was irregular and overlying mucosa was erythematous. No discharge was present.

On palpation, the growth was mildly tender and fixed to the underlying structure. It was hard in consistency. Bone like material was felt on the surface of the growth. Bleeding was evident on palpation.

Correlating the history of slowly enlarging painless growth and clinical finding of bony hard growth originating from the maxillary alveolar process causing displacement of 51 and 61 without any secondary changes a clinical diagnosis of benign tumor of bony origin was made.

Radiographs

The Intraoral peri apical view of the maxillary anterior region showed that the teeth present are 51, 52, 53 and 61. Permanent tooth buds present were 11, 12, 21 and 22. An irregular radiopaque structure was evident in between 52 and 61 surrounded by radiolucency and tooth-like structure evident inside the radiopaque structure. Suggestive of ossifying fibroma.

Computerized tomography of maxilla showed ill defined lytic lesion in the right side of the maxilla with surrounding areas of sclerosis and

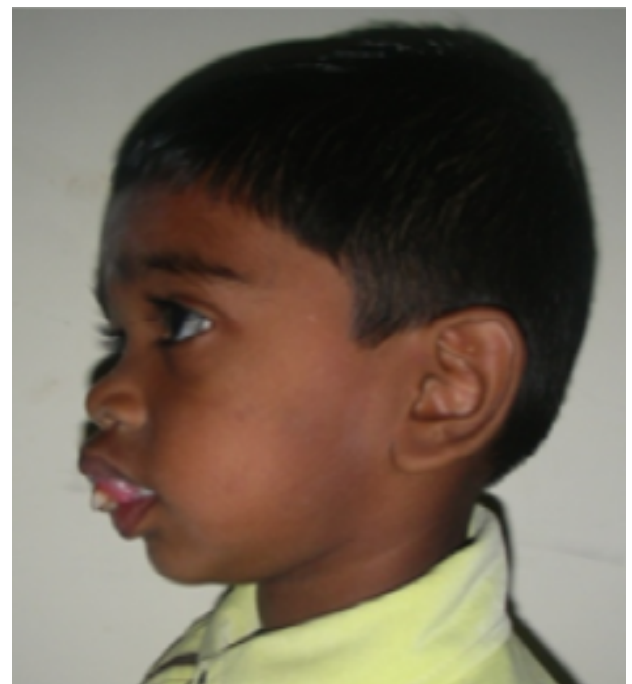

Figure 1: Pre operative lateral profile of the patient

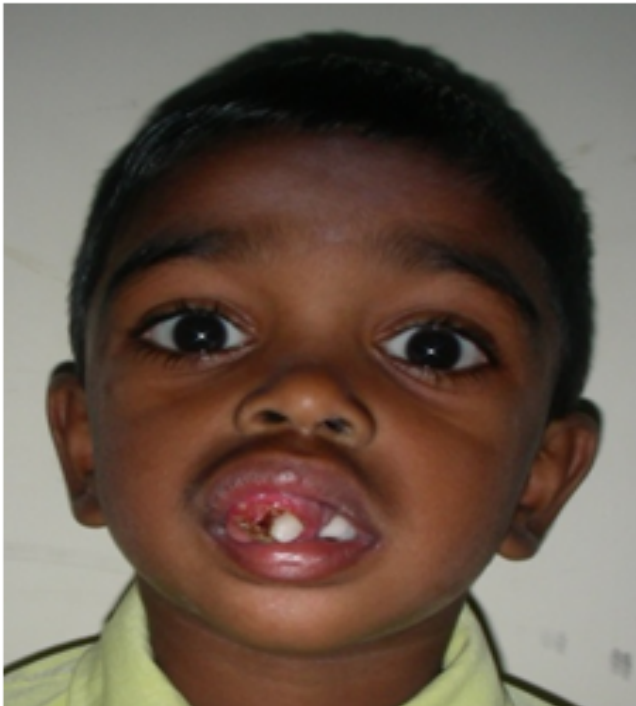

Figure 2: Pre operative picture showing lesion in the patient

bony erosion. Suggested clinical and histopathological correlation. An incisional bone biopsy was performed.

Histopathological report

Section showed peripheral stratified squamous epithelium. The underlying connective tissue showed interlacing trabeculae of bone with peripheral rimming of osteoblast. The deeper connective tissue showed ovoid to globular basophilic calcification interspersed in a richly cellular fibroblastic stroma. It was suggestive of Ossifying fibroma.

Management

An incision was given in the upper anterior region right side away from the lesion, proper dissection was carried out and the entire lesion was removed. An excisional biopsy was done and the specimen on histopathological examination showed rich cellular connective tissue stroma consisting of proliferative plump of fibroblast, along with collagen fibres (Figures 3 and 4). Round to oval areas of osteoid along with round with round basophilic cementum like material were seen interspersed in connective tissue stroma. Peripheral stratified squamous epithelium was also evident (Figure 5). It was suggestive of peripheral cemento-ossifying fibroma.

Discussion

Waldron classified fibro osseous lesions into three main categories namely- fibrous dysplasia, reactive lesions and fibro osseous lesions [1]. The 1992 WHO classification of groups under a single designation (cemento ossifying fibroma) two histologic types cementifying fibroma and ossifying fibroma that may be clinically and radiographically indistinguishable [5]. Gardner suggested that peripheral ossifying fibroma and peripheral odontogenic fibroma are two distinct entities. Peripheral ossifying fibroma is a reactive lesion and peripheral odontogenic fibroma is an extraosseous variant of central odontogenic fibroma. Peripheral cemento ossifying fibroma shows parakeratinised epithelium and well cellularised connective tissue containing mineralized components ranging

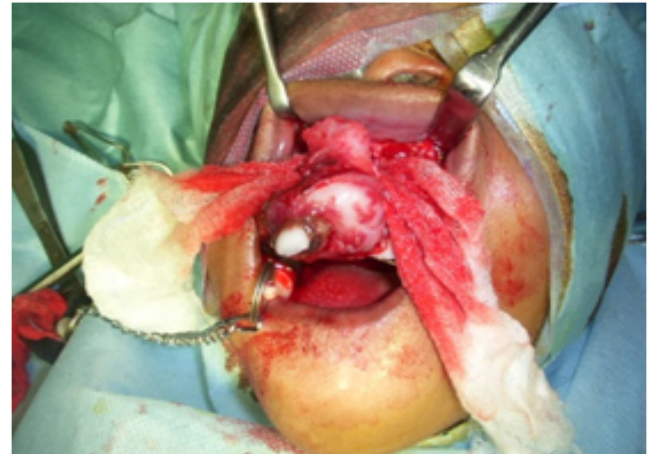

Figure 3: Intra operative picture of the patient

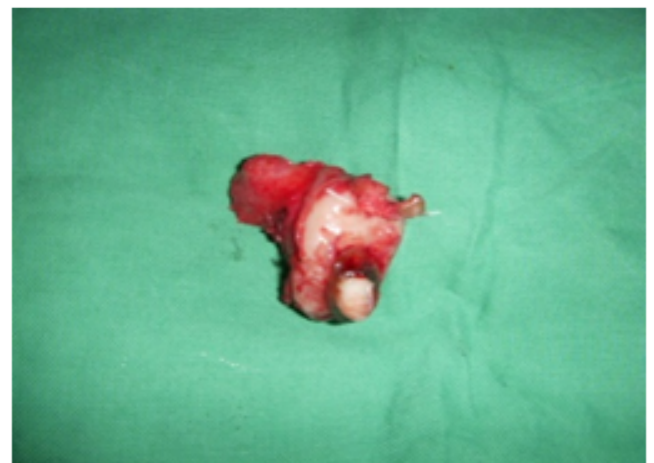

Figure 4: Excised lesion

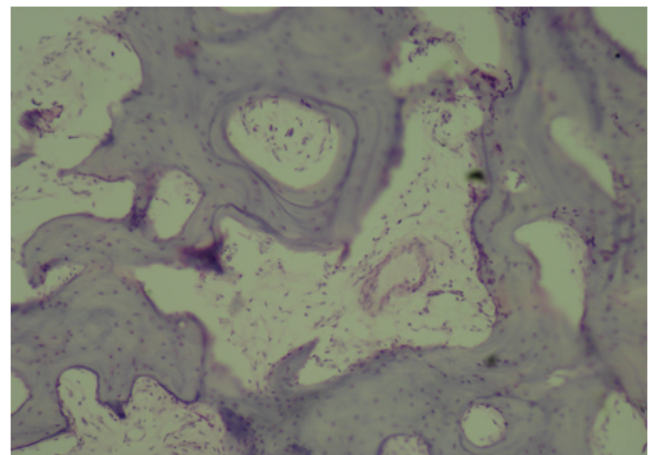


Figure 5: Histopathology of the lesion

from bone to cementum. Histopathology is important in confirming the diagnosis of peripheral cemento ossifying fibroma [6].

Histomorphologic spectrum of peripheral ossifying fibroma was studied by Buchner in a series of 207 cases both clinically and histologically. In 66 % cases the surface epithelium was ulcerated and

in the remainder it was intact. The ulcerated lesions were composed of highly cellular fibroblastic connective tissue and the non ulcerated part was more collagenized. Significant number of differences existed to differentiate peripheral ossifying fibroma from odontogenic fibroma [7].

Recurrence rate associated with PCOF is very high. Cundiff reported a recurrence rate of 15.9% [8]. Kennedy et al. showed a recurrence rate of 14.2% [9]. PCOF may present with unusual presentations. Hormonal influences may play a role in the high incidence of PCOF in females. Tooth migration has also been reported in some cases of PCOF. Surgical excision forms the mainstay of treatment of PCOF which includes the involved periodontal ligament and periosteum along with the removal of underlying etiology such as ill fitted dentures, calculus and rough restorations [10].

To the best of our knowledge PCOF occur in a patient with previous history of flap surgery has not been reported in the literature. Clinicians and oral and maxillofacial surgeons must be aware of such unusual presentations/etiologies of PCOF occurring in the maxilla and must consider it in the differential diagnosis of patients in the appropriate clinical setting.

References

1. Waldron CA (1993) Fibro-osseous lesions of the jaws. *J Oral Maxillofac Surg* 51: 828-835.
2. Delbum ACB, Cunha RF, Silva JZ, Pires AM (2008) Soubhiac Peripheral cemento-ossifying fibroma in child. A follow up of 4 years. Report of a case. *Eur J Dent* 2: 134-137.
3. Kendrick F, Waggoner WF (1996) Managing a peripheral ossifying fibroma ASDC. *J Dent Child* 63: 135-138.
4. Martin-Granzio R, Cuellar LAS, Fahlat F (2000) Cemento ossifying fibroma of the upper gingival. *Otolaryngology* 122 : 775
5. Gardner DG (1982) The peripheral odontogenic fibroma : An attempt to clarification. *Oral Surg Oral Med Oral Pathol* 54: 40-48.
6. Orkin DA, Amdas VD (1984) Ossifying fibrous epulis. *Oral Surg Oral Med Oral Pathol* 57: 147-148.
7. Buchner A, Hansen LS (1987) The histomorphologic spectrum of peripheral ossifying fibroma. *Oral Surg* 63: 452.
8. Cundiff EJ (1972) Peripheral ossifying fibroma : A review of 365 cases Thesis. Indiana university, 1972
9. Kenney JN, Kaugars GE, Abbey LM (1989) Comparison between peripheral ossifying fibroma and peripheral odontogenic fibroma. *J Oral Maxillofac Surg* 47: 378.
10. Poon CK, Kwan PC, Chao SY (1995) Giant peripheral ossifying of the maxilla: Report of a case. *J Oral Maxillofac Surg* 53: 695-698.