

Benign Cerebral Edema and Increased Intracranial Pressure (ICP) as Manifestations of COVID-19 Reinfection; A Case Report

Amir Hossein Heidary, Reza Elahi*, and Mahdis Nazari

School of Medicine, Zanjan University of Medical Sciences, Zanjan, Iran

*Corresponding author: Reza Elahi, School of Medicine, Zanjan University of Medical Sciences, Zanjan, Iran, E-mail: Rezaelahi96@zums.ac.ir

Received: 17 May, 2021 | Accepted: 09 Jul, 2021 | Published: 19 Jul, 2021

Citation: Heidary AH, Elahi R, Nazari M (2021) Benign Cerebral Edema and Increased Intracranial Pressure (ICP) as Manifestations of COVID-19 Reinfection; A Case Report. *J Clin Lab Med* 6(1): dx.doi.org/10.16966/2572-9578.138

Copyright: © 2021 Heidary AH, et al. This is an open-access article distributed under the terms of the Creative Commons Attribution License, which permits unrestricted use, distribution, and reproduction in any medium, provided the original author and source are credited.

Abstract

Reinfection with COVID-19 is of great importance since it can substantially affect the future of disease control and vaccine development. COVID-19 can present with diverse neurological, as well as respiratory and gastrointestinal symptoms. Here, we present a rare case of COVID-19 reinfection with neurological manifestations. The patient was a healthy 26-year-old male that had experienced first episode of COVID-19 infection with mild respiratory and gastrointestinal symptoms. In his second episode of infection, he presented to the emergency department with vertigo, vomiting, metamorphopsia, blurred vision, headache, and gait disturbance. Based on the clinical data and imaging studies, the patient was diagnosed with benign cerebral edema and intracranial hypertension. Then, he was treated using intravenous/intramuscular corticosteroids in addition to the supplementary therapies. His symptoms dramatically improved during the next 2 days. No important neurologic or systemic adverse events in response to the treatment were noted. This case reveals that infection with COVID-19, despite positive IgG, does not protect the patient from reinfection. Moreover, COVID-19 reinfection can present with benign cerebral edema and intracranial hypertension, in which case, inflammatory suppression therapy should be considered.

Keywords: COVID-19; Case report; Reinfection; Cerebral edema; Intracranial Pressure (ICP)

Introduction

Since December 2019, Coronavirus Disease 2019 (COVID-19), caused by Severe Acute Respiratory Syndrome Coronavirus-2 (SARS-CoV-2), has spread to most of the countries around the world [1-3]. COVID-19 can present with a wide range of symptoms, including mild respiratory symptoms requiring outpatient treatment, to severe respiratory disease requiring ventilator support in the Intensive Care Unit (ICU) [4,5]. COVID-19 can also present with neurological symptoms, such as headache, visual disturbances, confusion, altered mental status, cerebral edema, encephalitis, and stroke [6,7]. Moreover, multiple cases of COVID-19 reinfection have been reported. In most cases, reinfection with COVID-19 has been reported to present with asymptomatic/mild respiratory symptoms [8-10], however, in some cases, COVID-19 presents with more severe respiratory symptoms compared to the first episode [11]. Neurological symptoms have rarely been reported as symptoms of COVID-19 reinfection. Here, we present a case with benign cerebral edema and clinical symptoms of Increased Intracranial Pressure (ICP) as manifestations of COVID-19 reinfection.

Case Report

On November 12th, 2020, a 26-year-old male patient presented to the hospital. He was a medical doctor and was working as family therapist. His body mass index was 29.8 Kg/m². He had no past

medical or family history regarding any special disease. He presented with dizziness, headache (describing as fullness of head), diplopia, metamorphopsia, blurred vision, nausea, and vomiting. He noted the history of previous infection by COVID-19 on May 23rd. At a glance, first episode of infection presented with signs and symptoms of nausea, vertigo, fatigue, diarrhea, stomachache, and upper respiratory symptoms. RT-PCR test was conducted for SARS-CoV-2 and was resulted positive. According to his mild symptoms, the patient was quarantined and treated as outpatient with supportive therapy. During next two weeks, the patient's symptoms improved and had a qualitative-positive SARS-CoV-2 IgG and a negative RT-PCR at June 10th.

At the time he presented at the emergency department (ED), his arterial oxygen pressure was 88 mmHg, O₂ saturation was 95%, respiratory rate was 18, heart rate was 96 bpm and body temperature was 37.4°C. He was drowsy but aware of the time and place with gait imbalance and couldn't implement heel to knee maneuver. He stated that he couldn't see objects clearly, describing the straight lines on the wall as curved (metamorphopsia) and the room space as fuggy (blurred vision). He also reported lack of concentration presenting as tardive physical response compared to the past days.

The patient said he had resuscitated a traumatic case the past week with mouth-to-mouth breathing (due to lack of accessories), who subsequently turned out to be SARS-CoV-2 positive. 3 days after the

exposure (4 days prior to presenting to ED) his nausea was started. He reported no musculoskeletal and gastrointestinal symptoms. The patient reported that he had vertigo one day after nausea had been started. The night before admission, he had a sudden declined concentration and the feeling that he stated as “I was doing things slow-motion”. His symptoms gradually deteriorated during the night and experienced walking disability, visual defects, dizziness, vertigo, and 4 episodes of vomiting.

At the admission, the patient’s nasopharyngeal specimen was tested for SARS-CoV-2 RT-PCR which turned out to be positive. The patient’s serum ELISA test was positive for both COVID-19 IgG and IgM antibodies (Ab). On ocular examination, he could not see Snellen chart clearly because of diplopia and blurred vision. His Armsler grid test was abnormal. In the ophthalmoscopy assessment, prominent papillary edema with mild congestion of retinal veins was observed, without any extravasation.

A brain CT-scan without contrast was ordered which showed mild generalized cerebral cortex edema without any mass or hemorrhage. The CT images are shown in figure 1. Lumbar puncture was performed for CSF RT-PCR and pressure assessment which resulted in negative CSF RT-PCR and mildly increased ICP (ICP=28). Routine laboratory studies were requested, which revealed no specific findings except mild leukocytosis. Laboratory data and CSF analysis are shown in table 1.

After establishing the diagnosis of encephalitis and increased ICP, the patient was admitted at neurology ward and Intravenous (IV) infusion of 12 mg Dexamethasone, in 500 CC normal saline, was started. Then, 4 mg of IM dexamethasone was continued every 6 hours until day 3 and was tapered gradually over 3 days. The patient was suggested to sleep with tilted head at 45 degrees and supplemental therapy was prescribed, including 100 milligrams (mg) of vitamin E daily, 1000 units of vitamin D daily, 1000 mg of vitamin C effervescent tablets daily, and 10 mg Zinc daily. Patient’s symptoms mostly improved 5 hours after first infusion. All symptoms were alleviated by day 2 and no drug-specific complications were observed. Papillary edema resolved 5 days after first dose and normal vision of the right and left eyes were achieved at 4th and 14th days, respectively. The patient was discharged at day 14th.

After 14 days of first presentation to ED, the patient was reassessed. Ophthalmoscopy showed normal papilla and there was no obvious venous congestion. Armsler grid and Snellen tests showed normal vision. Deep tendon reflexes were normal. Patient could walk normally without any imbalance; however, he did not give consent to repeat the CSF and brain CT-scan. 30 days after first presentation, all assessments of the patient were normal and he did not report any problems. At day 30, ELISA test was positive for SARS-CoV-2 IgG and negative for IgM. Also RT-PCR test of nasopharyngeal swab was negative for SARS-CoV-2.

Discussion

Having a great impact on SARS-CoV-2 vaccination methods and dosing, COVID-19 reinfection is of significant importance. Multiple cases of reinfection have been reported since early 2020, including the Hong Kong [8], Israel [12], Pakistan [13], Ecuador [14], and Nevada [15] cases. Several theories could explain the reinfection, such as the inadequate Ab-mediated immune response to the virus, reinfection with a phylogenetically mutated virus, reactivation of the inactive virus, persistent viral infection with undetectable viral load, false-negative RT-PCR results, and a recent theory demonstrating the role of exosomes in the reinfection of COVID-19 [15-17].

Also, neurologic symptoms, including a broad spectrum from headache to fulminant encephalitis, acute stroke, consciousness impairment have been identified as symptoms of COVID-19 infection [18]. However, the exact pathologic mechanisms and symptoms of CNS involvement by COVID-19 have not been described clearly but they have proposed that these manifestations are more probable in elderly patients with prior history of neurological conditions [10]. Several explanations have been suggested for the involvement of CNS by SARS-CoV-2. Direct transmission of the virus into the CNS through the olfactory route of the nasal cavity [19-21] and hematogenous spread of the virus into the brain by attaching to ACE-2 receptors on the brain tissue are the most probable mechanisms [22,23]. In a study by Chen et al, SARS-CoV-2 RNA was detected in 2% of the neocortex of the infected individuals, showing the presence of the viral RNA particles in the brain tissue [24].

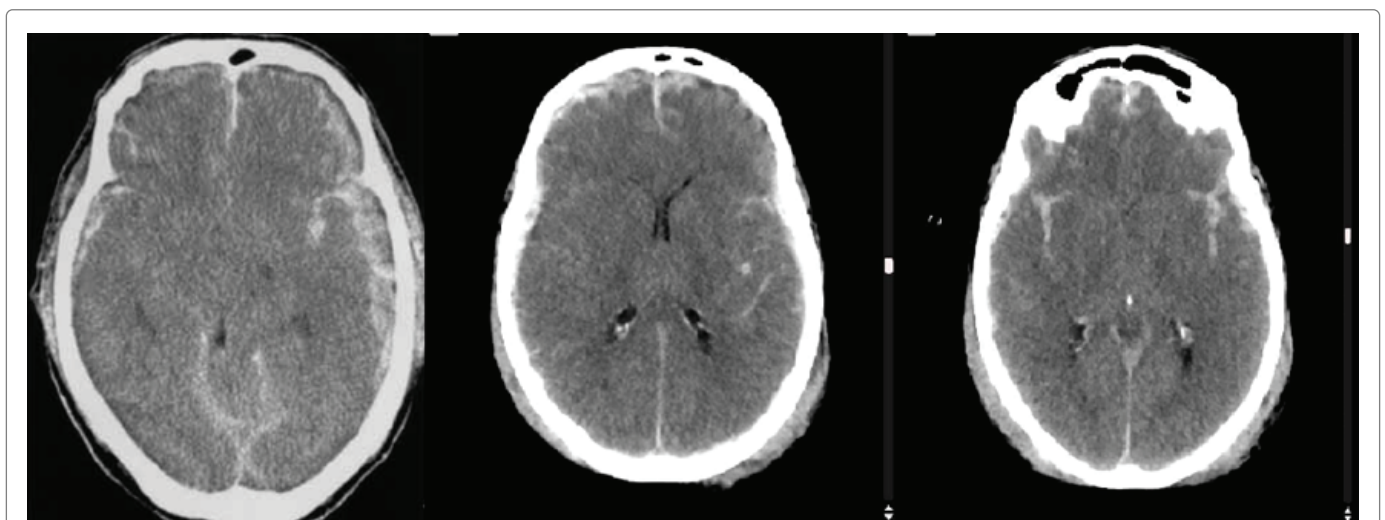


Figure 1: Cerebral CT scan demonstrating general cranial edema with blurring of the cortico-subcortical junction and shrinkage of the cerebral ventricles.

Table 1: Biochemical assessment of blood and CSF samples

	WBC	RBC	Hb	Hct	Plt	MCV	RDW	Eos	Neut	Lymph	Baso	AST	ALT	Alp	BS	BUN	Cr	CSF RT-PCR
At admission	11.8	4.2	15.2	35	213	86	12	2.3	65	32	0.07	30	42	150	145	19.6	0.9	-
Before discharge (day 14th)	8.1	4.4	15.1	36	259	85	12	0.9	71	28	0.06	32	40	159	126	20.8	1	

WBC: White Blood Cell; RBC: Red Blood Cell; Hb: Hemoglobin; Hct: Hematocrit; Plt: Platelet Count; Eos: Eosinophil; Lymph: Lymphocyte; Baso: Basophiles; AST: Aspartate Transaminase; ALT: Alanine Transaminase; Alp: Alkaline Phosphatase; Cr: Creatinine; MCV: Mean Corpuscular Volume; RDW: Red-Blood Cell Distribution Width; BS: Blood Sugar; BUN: Blood Urea Nitrogen; CSF: Cerebrospinal Fluid; RT-PCR: Reverse Transcriptase-Polymerase Chain Reaction

Multiple theories can explain the presence of neurologic manifestations as symptoms of reinfection in our patient. First is the potential role of viral mutations in the SARS-CoV-2 genome which have enabled the virus to invade the CNS. Since our patient was a medical doctor having great daily exposure to SARS-CoV-2, the second theory is the extreme cytokine release due to higher viral load which has increased the vascular permeability and lead to cerebral edema.

In a study of autopsied brain tissues of neurologic COVID-19 patients it has been reported that gross abnormalities were hemorrhagic conversion of middle cerebral artery stroke, petechial bleedings and punctate subarachnoid hemorrhages, subdural hematoma, acute and/or subacute infarcts, lacunar infarcts/microinfarcts and watershed infarcts, and severe edema. Microscopic abnormalities were acute hypoxic injury, infarcts/focal ischemic necrosis, microhemorrhage or hemorrhagic suffusion, intravascular microthrombi, neutrophilic plugs, Axonal damage, Acute disseminated encephalomyelitis, and acute and chronic inflammation in the olfactory epithelium [25]. Several theories are suggested for the neurological manifestations of COVID-19. Coronavirus exerts its effects by binding to ACE2 that regulates the blood pressure and has an anti-thrombotic role. Binding the SARS-CoV-2 to ACE2 in nervous system along with ACE2 systemic effects can cause blood brain barrier damage and systemic hypertension that leads to brain edema or even cerebral hemorrhage. Numbers of studies have shown that COVID-19 cytokine storm can cause a Secondary Hemophagocytic Lymphohistiocytosis (sHLH) which leads to multi organ failure including intracerebral hemorrhage [26-28]. There is another theory in which microthrombosis in the vascular structure of brain causes elevated cerebral blood pressure. The most common sites of post-COVID-19 thrombosis are the lower extremities (deep vein thrombosis) that can cause massive calf edema and Cerebral Venous System Thrombosis (CVST) which causes severe brain edema and increased ICP. If it is severe enough, the increased ICP can even lead to a fatal herniation that presents with coma/death [29,30].

Here, we report a case of COVID-19 reinfection presenting with signs and symptoms of increased ICP and benign cerebral edema in the CT scan that finally diagnosed to have COVID-19. Our case demonstrates that COVID-19 reinfection could present with different symptoms, including neurological symptoms, compared to the first episode. The differential diagnoses of our case include: cerebral edema (secondary to increased vascular permeability due to cytokine release), viral encephalitis, CNS vasculitis, and arterial/venous thrombosis. The CT findings showing blurring of the gray-white matter junction and shrinkage of the cerebral ventricles support the vasogenic cerebral edema secondary to the cytokine release as the most probable diagnosis of our patient. Also, according to the negative RT-PCR of the CSF, viral

encephalitis is less probable. However, the lack of histopathological records and absence of genetic data of the virus are the factors that complicate the definite diagnosis of the patient.

Conclusion

Neurologic symptoms can present as manifestations of COVID-19 reinfection. Although our patient presented with only mild manifestations of cerebral edema and hypertension, it could present more severe and even lethal in others. Also, since our patient's IgG was positive at the time of reinfection, it should be noted that positive IgG cannot prevent the reinfection of COVID-19. Therefore, positive IgG must not be considered as protective immunity after reinfection or vaccination and multiple injections of vaccine could help to achieve adequate immunity. Another important lesson is that in every patient presenting with altered mental status and cerebral hypertension, COVID-19 should be considered as one of the main differential diagnoses and SARS-CoV-2 testing should be ordered in addition to the brain CT imaging. Since our patient dramatically responded to anti-inflammatory treatment with IV/IM corticosteroids, anti-inflammatory treatment should be considered in the same patients with COVID-19-associated encephalitis.

Financial Support

Financial support data are not applicable.

Conflict of Interests

The authors declare no conflict of interests.

References

1. Esmailzadeh A, Elahi R (2020) Immunobiology and immunotherapy of COVID-19: A clinically updated overview. *J Cell Physiol* 236: 2519-2543.
2. Esmailzadeh A, Jafari D, Tahmasebi S, Elahi R, Khosh E (2021) Immune-Based Therapy for COVID-19. *Adv Exp Med Biol* 1318: 449-468.
3. Ghaebi M, Tahmasebi S, Jozghorbani M, Sadeghi A, Thangavelu L, et al. (2021) Risk factors for adverse outcomes of COVID-19 patients: Possible basis for diverse responses to the novel coronavirus SARS-CoV-2. *Life Sci* 277: 119503.
4. Valizadeh H, Abdolmohammadi-Vahid S, Danshina S, Ziya Gencer M, Ammari A, et al. (2020) Nano-curcumin therapy, a promising method in modulating inflammatory cytokines in COVID-19 patients. *Int Immunopharmacol* 89: 107088.
5. CDC COVID-19 Response Team (2020) Severe Outcomes Among Patients with Coronavirus Disease 2019 (COVID-19) -United States, February 12-March 16, 2020. *MMWR Morb Mortal Wkly Rep* 69: 343-346.

6. Wang H-Y, Li X-L, Yan Z-R, Sun X-P, Han J, et al. (2020) Potential neurological symptoms of COVID-19. *Ther Adv Neurol Disord* 13: 1-2.
7. Bongiovanni M (2021) COVID-19 re-infection presenting as acute ischemic stroke. *Clin Res Trials* 7: 1-2.
8. Parry J (2020) Covid-19: Hong Kong scientists report first confirmed case of reinfection. *BMJ*.
9. Bonifácio LP, Pereira APS, Araújo DCAE, Balbão VDMP, Fonseca BALD, et al. (2020) Are SARS-CoV-2 reinfection and Covid-19 recurrence possible? a case report from Brazil. *Rev Soc Bras Med Trop* 53: e20200619.
10. Wijeratne T, Gillard Crewther S, Sales C, Karimi L (2021) COVID-19 pathophysiology predicts that ischemic stroke occurrence is an expectation, not an exception-A systematic review. *Front Neurol* 11: 607221.
11. Heidi L (2020) COVID-19 reinfection: three questions scientists are asking. *Nature* 585: 168-169.
12. Nachmias V, Fusman R, Mann S, Koren G (2020) The first case of documented Covid-19 reinfection in Israel. *IDCases* 22: e00970.
13. Hanif M, Haider MA, Ali MJ, Naz S, Sundas FNU (2020) Reinfection of COVID-19 in Pakistan: A First Case Report. *Cureus* 12: e11176.
14. Prado-Vivar B, Becerra-Wong M, Guadalupe JJ, Márquez S, Gutierrez B, et al. (2020) A case of SARS-CoV-2 reinfection in Ecuador. *Lancet Infect Dis* 21: e142.
15. Tillett RL, Sevinsky JR, Hartley PD, Kerwin H, Crawford N, et al. (2020) Genomic evidence for reinfection with SARS-CoV-2: a case study. *Lancet Infect Dis* 21: 52-58.
16. Elrashdy F, Aljaddawi AA, Redwan EM, Uversky VN (2020) On the potential role of exosomes in the COVID-19 reinfection/reactivation opportunity. *J Biomol Struct Dyn*: 1-12.
17. To KK, Hung IF, Ip JD, Chu AW, Chan WM, et al. (2020) COVID-19 re-infection by a phylogenetically distinct SARS-coronavirus-2 strain confirmed by whole genome sequencing. *Clin Infect Dis*: ciaa1275.
18. Filatov A, Sharma P, Hindi F, Espinosa PS (2020) Neurological complications of coronavirus disease (COVID-19): encephalopathy. *Cureus* 12: e7352.
19. Butowt R, Bilinska K (2020) SARS-CoV-2: Olfaction, Brain Infection, and the Urgent Need for Clinical Samples Allowing Earlier Virus Detection. *ACS Chem Neurosci* 11: 1200-1203.
20. Pougá L (2021) Encephalitic syndrome and anosmia in COVID-19: Do these clinical presentations really reflect SARS-CoV-2 neurotropism? A theory based on the review of 25 COVID-19 cases. *J Med Virol* 93: 550-558.
21. Lima M, Siokas V, Aloizou A-M, Liampas I, Mentis A-FA, et al. (2020) Unraveling the Possible Routes of SARS-COV-2 Invasion into the Central Nervous System. *Curr Treat Options Neurol* 22: 1-15.
22. Hikmet F, Méar L, Edvinsson Å, Micke P, Uhlén M, et al. (2020) The protein expression profile of ACE2 in human tissues. *Mol Syst Biol* 16: e9610.
23. Wang Y, Wang Y, Luo W, Huang L, Xiao J, et al. (2020) A comprehensive investigation of the mRNA and protein level of ACE2, the putative receptor of SARS-CoV-2, in human tissues and blood cells. *Int J Med Sci* 17: 1522-1531.
24. Chen R, Wang K, Yu J, Howard D, French L, et al. (2020) The spatial and cell-type distribution of SARS-CoV-2 receptor ACE2 in human and mouse brain. *Front Neurol* 11: 573095.
25. Mukerji SS, Solomon IH (2021) what can we learn from brain autopsies in COVID-19? *Neurosci Lett* 742: 135528.
26. Mehta P, McAuley DF, Brown M, Sanchez E, Tattersall RS, et al. (2020) COVID-19: consider cytokine storm syndromes and immunosuppression. *Lancet* 395: 1033-1034.
27. Moriguchi T, Harii N, Goto J, Harada D, Sugawara H, et al. (2020) A first case of meningitis/encephalitis associated with SARS-Coronavirus-2. *Int J Infect Dis* 94: 55-58.
28. Kim JM, Chung YS, Jo HJ, Lee NJ, Kim MS, et al. (2020) Identification of Coronavirus Isolated from a Patient in Korea with COVID-19. *Osong Public Health Res Perspect* 11: 3-7.
29. Nuzzo D, Vasto S, Scalisi L, Cottone S, Cambula G, et al. (2021) Post-acute COVID-19 neurological syndrome: A new medical challenge. *J Clin Med* 10: 1947.
30. Chen X, Laurent S, Onur OA, Kleineberg NN, Fink GR, et al. (2020) A systematic review of neurological symptoms and complications of COVID-19. *J Neurol* 268: 1-11.