

# Severe Acne in Female Patients Treated with Isotretinoin is associated with Dysbiosis and its Consequences

Donatini Bruno\* and Le Blaye Isabelle

Medicine Information Formation, Cormontreuil, France

\*Corresponding author: Donatini Bruno, Medicine Information Formation, Cormontreuil, France, E-mail: [donatini@orange.fr](mailto:donatini@orange.fr)

Received: 30 May, 2018 | Accepted: 27 Jun, 2018 | Published: 04 Jul, 2018

**Citation:** Bruno D, Isabelle LB (2018) Severe Acne in Female Patients Treated with Isotretinoin is Associated with Dysbiosis and its Consequences. J Clin Cosmet Dermatol 2(3): [dx.doi.org/10.16966/2576-2826.131](http://dx.doi.org/10.16966/2576-2826.131)

**Copyright:** © 2018 Bruno D, et al. This is an open-access article distributed under the terms of the Creative Commons Attribution License, which permits unrestricted use, distribution, and reproduction in any medium, provided the original author and source are credited.

## Abstract

Severe acne is mainly caused by *Propionibacterium acnes* (PA) and is sometime treated with isotretinoin. Propionibacterium species may alter intestinal mucosa and isotretinoin may induce mucosal side-effects. We investigated whether severe acne (treated or not with isotretinoin) is associated with dysbiosis and its consequences.

**Methods:** All female patients consulting for the first time the same gastroenterologist were included into a retrospective observational cohort with a large control group in order to evaluate the incidence of adverse events in gastroenterological consultations. Those with a medical history of severe acne -treated with isotretinoin or antibiotic therapy-were compared to a control group. The study stopped when 1,000 patients were included into the control group. Age, Body weight, Body Mass Index, exhaled hydrogen or methylacetate after fasting (a marker of dysbiosis and malabsorption), medical history of allergy or auto-immune disease, oral herpes simplex 1/2 replication (confirmed by qPCR) were collected. Anxiety and depression scores were calculated.

**Results:** 1,054 patients were enrolled: 1,000 control patients; 28 with severe acne not treated with isotretinoin (group 1) and 26 with isotretinoin (group 2).

Group 2 (isotretinoin) has a lower body weight ( $56.9 \pm 9.9$  versus  $61.1 \pm 15$  kg;  $p < 0.05$ ) and Body Mass Index ( $20.84 \pm 3.8$  versus  $22.85 \pm 5.2$ ;  $p < 0.05$ ) than the control group (despite being younger ( $40 \pm 10$  years versus  $50 \pm 16$ ;  $p < 0.05$ ).

Group 2 (isotretinoin) presents with dysbiosis: higher levels of H<sub>2</sub> ( $7.3$  ppm  $\pm 7$  versus  $4.6 \pm 6.9$ ;  $p < 0.05$ ) and methylacetate ( $5.4 \pm 2.6$  versus  $3.9 \pm 4.4$ ;  $p < 0.05$ ). It also presents more frequently with oral herpes simplex ( $30.4\%$  versus  $21.4\%$ ;  $p < 0.05$ ) or allergy ( $34.6\%$  versus  $15.7\%$ ) which suggests dysimmunity.

Group 1 (without isotretinoin) does not experience dysbiosis.

Anxiety and depression scores were higher in patients with acne (treated or not with isotretinoin).

The incidence of isotretinoin-associated events is equal to 2.6% of gastroenterological consultations.

**Conclusion:** In female patients, isotretinoin is associated with dysbiosis, malabsorption and dysimmunity.

**Keywords:** Malabsorption; Isotretinoin; Breath test; Stem cells; Apoptosis

**Abbreviations:** BMI: Body Mass Index; kPa: Kilopascals; MA: Methylacetate; PA: *Propionibacterium acnes*; Ppm: Particles per million; qPCR: quantitative Polymerase Chain Reaction; SIBO: Small Intestinal Bowel Overgrowth.

## Introduction

Small Intestinal Bowel Overgrowth (SIBO) is due to bacterial proliferation in the jejunum. These bacteria are consuming unabsorbed disaccharides because of mucosal enzymatic deficiencies or excessive intakes of sweetened food. Drug-induced mucosal atrophy belongs to

the long list of possible etiologies. SIBO is associated with non-severe complains like diarrhoea or constipation, bloating, abdominal pain and sometimes with severe malabsorption and its consequences (e.g. anaemia, Vitamin D or unsaturated lipid acids deficiency, fatigue, decreased immunity) [1-3].

In clinical practice, the diagnosis of SIBO mainly relies on breath tests with hydrogen, methane or volatile organic compounds measurements (which include methylacetate) [3-5]. The probability to find volatile organic compounds in exhaled air increases when SIBO is severe and prolonged. In such instances, the incidence of associated pathologies increases: like depression [6-10], overweight [11] and liver steatosis [12], type 2 diabetes mellitus [13], cancers [14], or chronic HPV infections [15].

Human enterotypes have been classified into three groups [16,17]. The group associated with acne-and which includes PA-is the enterotype called Prevotella. It includes bacteria involved in dental caries, chronic rhinosinusitis or periodontitis [18-24]. PA and *Acinetobacter baumannii* are frequently concomitantly detected in the aggressive periodontal microbiome [20]. *Acinetobacter baumannii* favours apoptosis of epithelial cells and therefore mucosal atrophy [25-27].

*Propionibacterium acnes* (PA) is frequently involved in acne and can be detected by PCR in 82.8% of lesions [28-30]. *Propionibacterium* species may adhere to intestinal mucosa [31]. They secrete hyaluronidase and can alter intestinal mucosa [32-34]. Microbiomes may associate several aggressive bacteria such as PA or *Acinetobacter* species and lead to synergic destructive and atrophic effect on mucosa.

Patients with acne may receive isotretinoin which mucosal side-effects profile is well documented [35]. This mucosal toxicity is also illustrated by the possible occurrence of ulcerative colitis [36-39]. Isotretinoin affects also stem-cells renewal [35,40-43]. May an isotretinoin-induced mucosal atrophy occur, a long-term or even a permanent effect could be expected; leading to severe consequences, repeated consultations and explorations in gastroenterology, and therefore to health expenditures. As a matter of fact, Irritable Bowel Syndrome is known to induce important health costs [44-46].

Since isotretinoin remains a frequent treatment of acne, its safety profile should be further investigated. We therefore decided to perform a retrospective cohort to investigate whether severe acne treated with isotretinoin or severe acne treated with antibiotic therapy alone is associated with dysbiosis and its consequences. We enrolled a large number of patients in order to get the incidence of isotretinoin-associated malabsorption observed by a gastroenterologist. The inclusion stops as soon as the number of patients enrolled into the control group reaches one thousand.

The incidence of the event should be put into perspective with the one of other drug-induced malabsorption such as olmesartan-related celiac-like disease [47].

## Materials and Methods

### Study design: A retrospective cohort study

The objective of the study was to compare the occurrence and the severity of intestinal dysbiosis and its consequences (e.g. malabsorption with deficiencies, weight loss, abdominal pain due to bloating, fatigue, anxiety, chronic inflammation) in female patients without a medical history of severe acne *versus* those with severe acne treated either with antibiotic therapy or with isotretinoin.

Severe acne was defined as an acne resistant to local treatments and which required either antibiotic therapy or isotretinoin for at least 3 months.

Patients were recruited during a consultation in a gastroenterological ward. They were split into three groups: one group with severe acne treated with oral antibiotic therapy more than three months (group 1), one group with severe acne treated with oral isotretinoin (group 2) and one control group.

The study should stop either after one year on recruitment or when 1,000 female patients were included into the control group. This design enables to calculate the incidence of intestinal dysbiosis associated with severe acne treated or not with isotretinoin, in gastroenterological consultations (Table 1).

### Patients

**Inclusion criteria:** All female patients consulting for the first time the same gastroenterologist were included into a prospective observational study.

All patients signed a written consent before the consultation which includes breath test, ultrasound, elastometry and viral detection in saliva.

**Exclusion criteria:** Male patients were not included because gender may influence small gut absorption, dysbiosis, tobacco and alcohol abuse, immunity and Body Mass Index. Lack of signed consent or missing medical or biological data was an exclusion criteria.

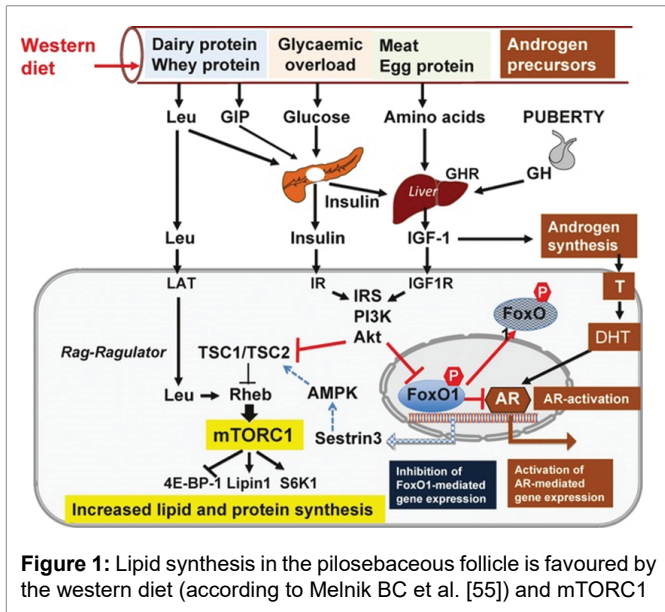
### Data collected

Age, Body weight, Body Mass Index, exhaled hydrogen or methylacetate after fasting (measured by the MX6 of Gazdetect France), medical history of allergy or auto-immune disease, oral herpes simplex 1/2 replication (medical history confirmed by qPCR run into a central laboratory; material: Amplix® from Alldiag®; reagents: Bioneer®) were collected.

The elasticity of the liver was evaluated with a Fibroscan® (elastometry). The anxiety and the depression scores were calculated

**Table 1:** Design of the retrospective cohort study

Inclusion criteria		
- Female patients consulting for digestive symptoms (gastroenterological consultations)		
Severe acne group		Control group
- Medical history of severe acne		
Antibiotic group	Isotretinoin group	- No acne or mild to moderate acne treated with neither antibiotic therapy nor isotretinoin
- Antibiotic therapy > 3 months	- isotretinoin treatment > 3 months	
- Local treatment		
- No isotretinoin		
28 patients	26 patients	1000 patients



from the Hamilton Anxiety Depression scale. Normal level of faecal elastase excluded exocrine pancreatic insufficiency.

### Statistics

Comparisons of means were performed using independent samples T tests. Comparisons of percentage used two-sample t-tests.

### Results

1,054 patients were enrolled: 1,000 control, 28 patients with severe acne not treated with isotretinoin (group 1) and 26 patients treated with isotretinoin (group 2). Isotretinoin was given for 6 to 12 months at the usual recommended dose: 0.5 to 1 mg/kg. None reported severe induced-isotretinoin toxicity which required discontinuation. 70% reported skin or mucosal dryness during or after isotretinoin therapy. The delay between the start of the intake of isotretinoin and the diagnosis of dysbiosis/malabsorption ranges between 18 to 25 years with a median period equal to 22 years.

Group 2 has a lower body weight ( $56.9 \pm 9.9$  versus  $61.1 \pm 15$  kg;  $p < 0.05$ ) and Body Mass Index ( $20.84 \pm 3.8$  versus  $22.85 \pm 5.2$ ;  $p < 0.05$ ) than the control group (despite being younger ( $40 \pm 10$  years versus  $50 \pm 16$ ;  $p < 0.001$ ). Group 1 presents also with lower body weight than the control group. There was no difference with group 2 as far as body weight and age are concerned.

Group 2 presents with dysbiosis: higher levels of  $H_2$  ( $7.3$  ppm  $\pm 7$  versus  $4.6 \pm 6.9$ ;  $p < 0.05$ ) and methylacetate ( $5.4 \pm 2.6$  versus  $3.9 \pm 4.4$ ;  $p < 0.05$ ) than in the control group. The difference was also significant between group 1 and group 2:  $7.3$  ppm  $\pm 7$  versus  $4.3 \pm 4.7$  ( $p < 0.05$ ) for  $H_2$  and  $5.4 \pm 2.6$  versus  $3.9 \pm 2.4$  ( $p < 0.05$ ) for methylacetate. Group 2 also presents more frequently with oral herpes simplex ( $30.4\%$  versus  $21.4\%$ ;  $p < 0.05$ ) or allergy ( $34.6\%$  versus  $15.7\%$ ) than the control group; which suggests dysimmunity.

Group 2 has lower Fibroscan® score ( $4.7 \pm 1.6$  versus  $5.4 \pm 2.2$ ;  $p < 0.05$ ) and higher anxiety rate ( $9.1 \pm 4.1$  versus  $10.9 \pm 3.5$ ;  $p < 0.05$ ) than the control group. Lack of power precludes any conclusions regarding autoimmunity ( $p < 0.05$ ).

Group 1 presents neither with dysbiosis, nor with increased rate of oral herpes simplex or allergy. There was no difference between

the control group and group 2 as far as depression was concerned. However, when patients with severe acne were pooled (54 patients treated or not with isotretinoin) the depression score was higher in patients with severe acne ( $5.2 \pm 3.6$  versus  $6.6 \pm 4.0$ ;  $p > 0.05$ ) (Table 2).

The incidence of isotretinoin-associated dysbiosis is equal to 2.6%.

### Discussion

*Propionibacterium acnes* (PA) is frequently involved in acne [28-30].

Human enterotypes have been classified into three groups [16-17]. PA belongs to the Prevotella-enterotype [20].

PA secretes hyaluronidase and can alter intestinal mucosa [32-34]. However, PA has not been associated with dysbiosis, malabsorption, or colitis.

The Prevotella-enterotype also includes *Helicobacter pylori* and *Desulfovibrio* species [17] as well as *Acinetobacter* species [20].

HP favours gastric mucosal atrophy [48] without any jejunal involvement [49]. *Desulfovibrio* favours ulcerative colitis [50-53]. However, there is no argument in favour of any *Desulfovibrio*-induced mucosa alteration of the small gut. *Acinetobacter* favours mucosal atrophy [25-27]. Therefore, although PA cannot directly favour colitis, other associated bacteria belonging to the Prevotella-enterotype may induce mucosal inflammation. However, there is no argument for any jejunal adverse effect of PA or of any associated bacteria from the Prevotella-enterotype.

On the contrary, mucosal side-effects are well known side-effects of isotretinoin [35] and ulcerative colitis have been reported with this medication [36-39]. However, jejunal involvement or severe malabsorption has not yet been reported.

According to Melnik BC [35], the unifying mechanism of all isotretinoin-induced adverse effects is the apoptosis of stem cells which involves neural crest cells (explaining teratogenicity), hippocampal neurones (depression), epidermal keratinocytes and mucosa cells (muco-cutaneous side-effects), hair follicle cells (telegenic effluvium), intestinal epithelial cells (inflammatory bowel disease), skeletal muscle cells (myalgia and release of creatine kinase) or hepatocytes (release of transaminases and very low-density lipoproteins).

Isotretinoin down regulate mTORC1 expression in sebocytes [40,41]. In acne (so called "metabolic syndrome of the pilosebaceous follicle") mTORC1 signalling is promoted by Western diet [40,54,55] (Figure 1). mTORC1 regulates stem-cell self-renewal [56,57]. Its blockade hinders epithelial renewal of the jejunum, [42] especially after jejunal injury [43].

In addition, isotretinoin normalizes [58,59] exaggerated TLR2-mediated responses in acne patients [60,61]. Since TLR2 plays many positive physiological roles, deleterious consequences of its blockade are expected. TLR2 regulates the production of neurotrophic factors in intestinal smooth muscle cells and promotes survival of enteric neurons and glial cells [62,63]. TLR2 controls mucosal renewal. Cells kinetics of villous columnar epithelial cells are modulated by TLR2 and controls the proliferation of indigenous bacteria [64-66]. TLR2 enables local tolerance via *Bacteroides fragilis*. It discriminates between pathogens and symbiotic bacterial molecules in a process that engenders commensal beneficial colonization [67,68]. TLR2 controls indigenous bacteria proliferation in the upper alimentary tract. Lack of TLR-2 contribute to the settlement of undesirable bacteria, especially Gram-positive, or candida [69,66,70,4].

**Table 2:** Data collected for the three groups of patients (all females) who consulted in a gastroenterological ward. Retrospective cohort study

	Control group 1,000	Severe acne No isotretinoin: 28	Isotretinoin : 26
Age (years)*	50 ± 16	44 ± 15	40 ± 10
Body weight (kg)*	61.1 ± 15	56.8 ± 13.8	56.9 ± 9.9
Height (cm) [NS]	163.1 ± 9.5	165.8 ± 5.6	165.4 ± 7.3
Body Mass Index*	22.85 ± 5.2	20.6 ± 4.4	20.84 ± 3.8
H <sub>2</sub> (ppm) §	4.6 ± 6.9	4.3 ± 4.7	7.3 ± 7
Methylacetate (ppm) §	3.9 ± 4.4	3.9 ± 2.4	5.4 ± 2.6
Oral herpes simplex!	21.4%	21.4%	30.4%
Autoimmunity (trend)	15.4%	17.9%	19.0%
Allergy!	15.7%	28.6%	34.6%
Elastometry (kPa)!	5.4 ± 2.2	5.0 ± 2.1	4.7 ± 1.6
Anxiety score!	9.1 ± 4.1	10.5 ± 4.5	10.9 ± 3.3
Depression score**	5.2 ± 3.6	6.5 ± 4.2	6.7 ± 3.7

\*P<0.05 between control and acne or between control and isotretinoin, but not between acne and isotretinoin

§ P<0.05 between acne and isotretinoin or between control and isotretinoin; not between control and acne

!P<0.05 between control and isotretinoin only; not between acne and isotretinoin

\*\*p>0.05 between control and pooled data from the 54 patients with acne treated or not with isotretinoin

Duodenal villous atrophy has been associated with drugs such as Olmesartan [3] or mefenamic acid, [71] and mimics celiac disease with weight and fat loss. The involvement of stem cells apoptosis and mTORC1 blockade has never been reported with any drugs; except isotretinoin. The maximum reported range of incidence of Olmesartan-associated celiac-like disease is 22 cases/10<sup>4</sup> exposed patients [47]. The estimated incidence of isotretinoin-induced celiac-like disease is 10 times higher.

Dysbiosis is easily detected by breath tests. The fermentation of sugars produces soluble gas which circulate to the lungs where they are exhaled [72,73]. Methylacetate, which belongs to the group of Volatile Organic Compounds, is particularly valuable to distinguish between various types of dysbiosis including small gut inflammation [74].

The increase in exhaled methylacetate is suggestive of dysbiosis associated with the PA-associated enterotype [74].

Acne is associated with mood disturbances, especially anxiety [75] and its treatment alleviates symptoms [76,77]. Isotretinoin has previously been implicated in the worsening of depression [78,79].

New data do not confirm such a role or even conclude to a positive psychological effect after acne alleviation [80-85]. According to our results, acne it-self (and therefore PA and the associated enterotype) could explain the difference observed between HAD scores in the control group and in patients with severe acne.

The study only included females. Male patients were excluded. They present with different clinical pictures and deserve a specific publication. The conclusion of this study is therefore limited to female patients.

## Conclusions

The study included only female patients. The conclusions are therefore only relevant for females. Isotretinoin is associated with dysbiosis, malabsorption (with visceral fat decrease) and signs of dysimmunity. Symptoms develop more than 20 years after the intake

of the medication taken at usual range and duration. A facilitating role of *Propionibacterium acnes* cannot be excluded. Isotretinoin is known to impair stem cells renewal and TLR2 expression in the mucosa of the small gut. These pharmacological effects, explaining the efficacy of the medication on acne (“the metabolic syndrome of the pilosebaceous gland”) may induce the progressive atrophy of the jejunal mucosa and its long-lasting consequences. No therapy is available yet. Patients, prescribers and authorities should be aware of this adverse event which incidence is high (2.6% of outward gastroenterological consultations) especially when multi-annual surveillance for several years are expected.

## References

1. Gasbarrini A, Lauritano EC, Gabrielli M, Scarpellini E, Lupascu A, et al. (2007) Small intestinal bacterial overgrowth: Diagnosis and treatment. *Dig Dis* 25: 237-240.
2. Ki ELL, Roduit J, Delarive J, Guyot J, Michetti P, et al. (2010) Pullulation bactérienne de l'intestin grêle. *Rev Med Suisse* 6: 186-191.
3. Donatini B (2015) Pullulation bactérienne du grêle. Intérêt des nouvelles technologies ambulatoires: test respiratoire couplé à l'élastométrie hépatique, à la recherche des herpès virus dans la salive ou de l'échographie gastro-intestinale. *Principes thérapeutiques. Revue Inist Hegel* 5: 92-99.
4. Eisenmann A, Amann A, Said M, Datta B, Ledochowski M (2008) Implementation and interpretation of hydrogen breath tests. *J Breath Res* 2: 046002.
5. Simrén M, Stotzer PO (2006) Use and abuse of hydrogen breath tests. *Gut* 55: 297-303.
6. Braden B (2009) Methods and functions: Breath tests. *Best Pract Res Clin Gastroenterol* 23: 337-352.
7. Bures J, Cyrany J, Kohoutova D, Förstl M, Rejchrt S, et al. (2010) Small intestinal bacterial overgrowth syndrome. *World J Gastroenterol* 16: 2978-2990.

8. Ledochowski M, Widner B, Sperner-Unterweger B, Propst T, Vogel W, et al. (2000) Carbohydrate malabsorption syndromes and early signs of mental depression in females. *Dig Dis Sci* 45: 1255-1259.
9. Ledochowski M, Sperner-Unterweger B, Widner B, Fuchs D (1998) Fructose malabsorption is associated with early signs of mental depression. *Eur J Med Res* 3: 295-298.
10. Pimentel M, Kong Y, Park S (2004) IBS subjects with methane on lactulose breath test have lower postprandial serotonin levels than subjects with hydrogen. *Dig Dis Sci* 49: 84-87.
11. Sabaté JM, Jouët P, Harnois F, Mechler C, Msika S, et al. (2008) High prevalence of small intestinal bacterial overgrowth in patients with morbid obesity: a contributor to severe hepatic steatosis. *Obes Surg* 18: 371-377.
12. Wigg AJ, Roberts-Thomson IC, Dymock RB, McCarthy PJ, Grose RH, et al. (2001) The role of small intestinal bacterial overgrowth, intestinal permeability, endotoxaemia, and tumour necrosis factor alpha in the pathogenesis of non-alcoholic steatohepatitis. *Gut* 48: 206-211.
13. Cuoco L, Montalto M, Jorizzo RA, Santarelli L, Arancio F, et al. (2002) Eradication of small intestinal bacterial overgrowth and oro-cecal transit in diabetics. *Hepatogastroenterology* 49: 1582-1586.
14. Haines A, Metz G, Dilawari J, Blendis L, Wiggins H (1977) Breath-methane in patients with cancer of the large bowel. *Lancet* 2: 481-483.
15. Donatini B, Le Blaye I (2015) Methylacetate increase after a lactulose breath test may help to detect active EBV and/or HPV infection. 26<sup>th</sup> International Congress on Anti-Cancer Treatment (ICACT), Paris.
16. de Moraes AC, Fernandes GR, da Silva IT, Almeida-Pititto B, Gomes EP, et al. (2017) Enterotype May Drive the Dietary-Associated Cardiometabolic Risk Factors. *Front Cell Infect Microbiol* 23: 47.
17. Arumugam M, Raes J, Pelletier E, Le Paslier D, Yamada T, et al. (2011) Enterotypes of the human gut microbiome. *Nature* 473: 174-180.
18. Mussano F, Ferrocino I, Gavrilova N, Genova T, Dell'Acqua A, et al. (2018) Apical periodontitis: preliminary assessment of microbiota by 16S rRNA high throughput amplicon target sequencing. *BMC Oral Health* 18: 55.
19. Cleland EJ, Bassiouni A, Vreugde S, Wormald PJ (2016) The bacterial microbiome in chronic rhinosinusitis: Richness, diversity, postoperative changes, and patient outcomes. *Am J Rhinol Allergy* 30: 37-43.
20. Silva-Boghossian CM, Neves AB, Resende FA, Colombo AP (2013) Suppuration-associated bacteria in patients with chronic and aggressive periodontitis. *J Periodontol* 84: e9-e16.
21. Zakaria MN, Takeshita T, Shibata Y, Maeda H, Wada N, et al. (2015) Microbial community in persistent apical periodontitis: a 16S rRNA gene clone library analysis. *Int Endod J* 48: 717-728.
22. Rôças IN, Alves FR, Santos AL, Rosado AS, Siqueira JF Jr (2010) Apical root canal microbiota as determined by reverse-capture checkerboard analysis of cryogenically ground root samples from teeth with apical periodontitis. *J Endod* 3: 1617-1621.
23. Colombo AP, Boches SK, Cotton SL, Goodson JM, Kent R, et al. (2009) Comparisons of subgingival microbial profiles of refractory periodontitis, severe periodontitis, and periodontal health using the human oral microbe identification microarray. *J Periodontol* 80: 1421-1432.
24. Fujii R, Saito Y, Tokura Y, Nakagawa KI, Okuda K, et al. (2009) Characterization of bacterial flora in persistent apical periodontitis lesions. *Oral Microbiol Immunol* 24: 502-505.
25. Naito T, Mulet C, De Castro C, Molinaro A, Saffarian A, et al. (2017) Lipopolysaccharide from Crypt-Specific Core Microbiota Modulates the Colonic Epithelial Proliferation-to-Differentiation Balance. *MBio* 8: e01680-e01717.
26. Gaddy JA, Actis LA (2009) Regulation of *Acinetobacter baumannii* biofilm formation. *Future Microbiol* 4: 273-278.
27. Gaddy JA, Tomaras AP, Actis LA (2009) The *Acinetobacter baumannii* 19606 OmpA protein plays a role in biofilm formation on abiotic surfaces and in the interaction of this pathogen with eukaryotic cells. *Infect Immun* 77: 3150-3160.
28. Naghdi N, Ghane M (2017) A comparison of culture and PCR methods for identifying *Propionibacterium acnes* in lesions isolated from patients with acne. *Turk J Med Sci* 47: 967-972.
29. Liu PF, Hsieh YD, Lin YC, Two A, Shu CW, et al. (2015) *Propionibacterium acnes* in the pathogenesis and immunotherapy of acne vulgaris. *Curr Drug Metab* 16: 245-254.
30. Jahns AC, Lundskog B, Ganceviciene R, Palmer RH, Golovleva I, et al. (2012) An increased incidence of *Propionibacterium acnes* biofilms in acne vulgaris: a case-control study. *Br J Dermatol* 167: 50-58.
31. Zárate G, Morata de Ambrosini VI, Chaia AP, González SN (2002) Adhesion of dairy propionibacteria to intestinal epithelial tissue *in vitro* and *in vivo*. *J Food Prot* 65: 534-539.
32. Tyner H, Patel R (2015) Hyaluronidase in Clinical Isolates of *Propionibacterium acnes*. *Int J Bacteriol* 2015: 218918.
33. Mak TN, Schmid M, Brzuszkiewicz E, Zeng G, Meyer R, et al. (2013) Comparative genomics reveals distinct host-interacting traits of three major human-associated propionibacteria. *BMC Genomics* 22: 640.
34. Morishita M, Aoki Y, Sakagami M, Nagai T, Takayama K (2004) *In situ* ileal absorption of insulin in rats: effects of hyaluronidase pretreatment diminishing the mucous/glycocalyx layers. *Pharm Res* 21: 309-316.
35. Melnik BC (2017) Apoptosis May Explain the Pharmacological Mode of Action and Adverse Effects of Isotretinoin, Including Teratogenicity. *Acta DermVenereo* 9: 173-181.
36. Papaconstantinou I, Stefanopoulos A, Papailia A, Zeglinas C, Georgopoulos I, et al. (2014) Isotretinoin and ulcerative colitis: A case report and review of the literature. *World J Gastrointest Surg* 6: 142-145.
37. Crockett SD, Porter CQ, Martin CF, Sandler RS, Kappelman MD (2010) Isotretinoin use and the risk of inflammatory bowel disease: a case-control study. *Am J Gastroenterol* 105: 1986-1993.
38. Reniers DE, Howard JM (2001) Isotretinoin-induced inflammatory bowel disease in an adolescent. *Ann Pharmacother* 35: 1214-1216.
39. Martin P, Manley PN, Depew WT, Blakeman JM (1987) Isotretinoin-associated proctosigmoiditis. *Gastroenterology* 93: 606-609.
40. Melnik B (2012) Dietary intervention in acne: Attenuation of increased mTORC1 signaling promoted by Western diet. *Dermatoendocrinol* 4: 20-32.
41. Melnik BC (2010) The role of transcription factor FoxO1 in the pathogenesis of acne vulgaris and the mode of isotretinoin action. *G Ital Dermatol Venereo* 145: 559-571.
42. Barron L, Sun RC, Aladegbami B, Erwin CR, Warner BW, et al. (2016) Intestinal Epithelial-Specific mTORC1 Activation Enhances Intestinal Adaptation After Small Bowel Resection. *Cell Mol Gastroenterol Hepatol* 3: 231-244.

43. Sampson LL, Davis AK, Grogg MW, Zheng Y (2016) mTOR disruption causes intestinal epithelial cell defects and intestinal atrophy postinjury in mice. *FASEB J* 30: 1263-1275.
44. Soubieres A, Wilson P, Poullis A, Wilkins J, Rance M (2015) Burden of irritable bowel syndrome in an increasingly cost-aware National Health Service. *Frontline Gastroenterol* 6: 246-251.
45. Maxion-Bergemann S, Thielecke F, Abel F, Bergemann R (2006) Costs of irritable bowel syndrome in the UK and US. *Pharmacoeconomics* 24: 21-37.
46. Hulisz D (2004) The burden of illness of irritable bowel syndrome: current challenges and hope for the future. *J Manag Care Pharm* 10: 299-309.
47. Esteve M, Temiño R, Carrasco A, Batista L, Del Val A, et al. (2016) Potential coeliac disease markers and autoimmunity in olmesartan induced enteropathy: A population-based study. *Dig Liver Dis* 48: 154-161.
48. Kong YJ, Yi HG, Dai JC, Wei MX (2014) Histological changes of gastric mucosa after *Helicobacter pylori* eradication: a systematic review and meta-analysis. *World J Gastroenterol* 20: 5903-5911.
49. Moran AP (2010) The role of endotoxin in infection: *Helicobacter pylori* and *Campylobacter jejuni*. *Subcell Biochem* 53: 209-240.
50. Hirano A, Umeno J, Okamoto Y, Shibata H, Ogura Y, et al. (2018) Comparison of the microbial community structure between inflamed and non-inflamed sites in patients with ulcerative colitis. *J Gastroenterol Hepatol*.
51. Figliuolo VR, Dos Santos LM, Abalo A, Nanini H, Santos A, et al. (2017) Sulfate-reducing bacteria stimulate gut immune responses and contribute to inflammation in experimental colitis. *Life Sci* 189: 29-38.
52. Lennon G, Balfe Á, Bambury N, Lavelle A, Maguire A, et al. (2014) Correlations between colonic crypt mucin chemotype, inflammatory grade and *Desulfovibrio* species in ulcerative colitis. *Colorectal Dis* 16: O161-O169.
53. Rowan F, Docherty NG, Murphy M, Murphy B, Calvin Coffey J, et al. (2010) *Desulfovibrio* bacterial species are increased in ulcerative colitis. *Dis Colon Rectum* 53: 1530-1536.
54. Melnik BC (2018) Acne vulgaris: The metabolic syndrome of the pilosebaceous follicle. *Clin Dermatol* 36: 29-40.
55. Melnik BC, Zouboulis CC (2013) Potential role of FoxO1 and mTORC1 in the pathogenesis of Western diet-induced acne. *Exp Dermatol* 22: 311-315.
56. Yilmaz ÖH, Katajisto P, Lamming DW, Gültekin Y, Bauer-Rowe KE, et al. (2012) mTORC1 in the Paneth cell niche couples intestinal stem-cell function to calorie intake. *Nature* 486: 490-495.
57. Zhou Y, Rychahou P, Wang Q, Weiss HL, Evers BM (2015) TSC2/mTORC1 signaling controls Paneth and goblet cell differentiation in the intestinal epithelium. *Cell Death Dis* 6: e1631.
58. Grasa L, Abecia L, Forcén R, Castro M, de Jalón JA, et al. (2015) Antibiotic-Induced Depletion of Murine Microbiota Induces Mild Inflammation and Changes in Toll-Like Receptor Patterns and Intestinal Motility. *Microb Ecol* 70: 835-848.
59. Dispenza MC, Wolpert EB, Gilliland KL, Dai JP, Cong Z, et al. (2012) Systemic isotretinoin therapy normalizes exaggerated TLR-2-mediated innate immune responses in acne patients. *J Invest Dermatol* 132: 2198-2205.
60. Fathy A, Mohamed RW, Ismael NA, El-Akhras MA (2009) Expression of toll-like receptor 2 on peripheral blood monocytes of patients with inflammatory and noninflammatory acne vulgaris. *Egypt J Immunol* 16: 127-134.
61. Bergler-Czop B, Brzezińska-Wcisło L (2014) Pro-inflammatory cytokines in patients with various kinds of acne treated with isotretinoin. *Postepy Dermatol Alergol* 31: 21-28.
62. Brun P, Gobbo S, Caputi V, Spagnol L, Schirato G, et al. (2015) Toll like receptor-2 regulates production of glial-derived neurotrophic factors in murine intestinal smooth muscle cells. *Mol Cell Neurosci* 68: 24-35.
63. Kamada N, Kao JY (2013) The tuning of the gut nervous system by commensal microbiota. *Gastroenterology* 145: 1193-1196.
64. Qi WM, Yamamoto K, Yokoo Y, Miyata H, Inamoto T, et al. (2009) Histoplanimetric study on the relationship between the cell kinetics of villous columnar epithelial cells and the proliferation of indigenous bacteria in rat small intestine. *J Vet Med Sci* 71: 463-470.
65. Mantani Y, Takahara E, Takeuchi T, Kawano J, Yokoyama T, et al. (2013) Histoplanimetric study on the relationship between invasion of indigenous bacteria into intestinal crypts and proliferation of epithelial cells in rat ascending colon. *J Vet Med Sci* 75: 939-947.
66. Yuasa H, Mantani Y, Masuda N, Nishida M, Kawano J, et al. (2017) Differential expression of Toll-like receptor-2, -4 and -9 in follicle-associated epithelium from epithelia of both follicle-associated intestinal villi and ordinary intestinal villi in rat Peyer's patches. *J Vet Med Sci* 78: 1797-1804.
67. Round JL, Lee SM, Li J, Tran G, Jabri B, et al. (2011) The Toll-like receptor 2 pathway establishes colonization by a commensal of the human microbiota. *Science* 332: 974-977.
68. Hörmann N, Brandão I, Jäckel S, Ens N, Lillich M, et al. (2014) Gut microbial colonization orchestrates TLR2 expression, signaling and epithelial proliferation in the small intestinal mucosa. *PLoS One* 9: e113080.
69. Prieto D, Carpena N, Maneu V, Gil ML, Pla J, et al. (2016) TLR2 modulates gut colonization and dissemination of *Candida albicans* in a murine model. *Microbes Infect* 18: 656-660.
70. Mantani Y, Kamezaki A, Udayanga KG, Takahara EI, Qi WM, et al. (2011) Site differences of Toll-like receptor expression in the mucous epithelium of rat small intestine. *Histol Histopathol* 26: 1295-1303.
71. Mantani Y, Yokoo Y, Kamezaki A, Udayanga KG, Takahara E, et al. (2012) Immunohistochemical detection of toll-like receptor-2, -4 and -9 in exocrine glands associated with rat alimentary tract. *J Vet Med Sci* 74: 1429-1438.
72. Ianiro G, Bibbò S, Montalto M, Ricci R, Gasbarrini A, et al. (2014) Systematic review: Sprue-like enteropathy associated with olmesartan. *Aliment Pharmacol Ther* 40: 16-23.
73. Kaosombatwattana U, Limsrivilai J, Pongpaibul A, Maneerattanaporn M, Charatcharoenwitthaya P (2017) Severe enteropathy with villous atrophy in prolonged mefenamic acid users - a currently under-recognized in previously well-recognized complication: Case report and review of literature. *Medicine (Baltimore)* 96: e8445.
74. Donatini B, Le Blaye I (2015) *Mycobacterium avium* paratuberculosis (MAP) and Cytomegalovirus (CMV) are frequently detected in the saliva of patients recently diagnosed with Crohn Disease (CD) whereas oral *Propionibacterium acnes* (PA) or methylacetate (MA) in their breath is rare. *J Biosciences Med* 3: 13-18.

75. Golchai J, Khani SH, Heidarzadeh A, Eshkevari SS, Alizade N, et al. (2010) Comparison of anxiety and depression in patients with acne vulgaris and healthy individuals. *Indian J Dermatol* 55: 352-354.
76. Behnam B, Taheri R, Ghorbani R, Allameh P (2013) Psychological impairments in the patients with acne. *Indian J Dermatol* 58: 26-29.
77. Marron SE, Tomas-Aragones L, Boira S (2013) Anxiety, depression, quality of life and patient satisfaction in acne patients treated with oral isotretinoin. *Acta Derm Venereol* 93: 701-706.
78. Fakour Y, Noormohammadpour P, Ameri H, Ehsani AH, Mokhtari L, et al. (2014) The effect of isotretinoin (roaccutane) therapy on depression and quality of life of patients with severe acne. *Iran J Psychiatry* 9: 237-240.
79. Azoulay L, Blais L, Koren G, LeLorier J, Bérard A (2008) Isotretinoin and the risk of depression in patients with acne vulgaris: a case-crossover study. *J Clin Psychiatry* 69: 526-532.
80. Šimić D, Penavić JZ, Babić D, Gunarić A (2017) Psychological Status and Quality of Life in Acne Patients Treated with Oral Isotretinoin. *Psychiatr Danub* 29: 104-110.
81. Huang YC, Cheng YC (2017) Isotretinoin treatment for acne and risk of depression: A systematic review and meta-analysis. *J Am Acad Dermatol* 76: 1068-1076.
82. Suarez B, Serrano A, Cova Y, Baptista T (2016) Isotretinoin was not associated with depression or anxiety: A twelve-week study. *World J Psychiatry* 6: 136-142.
83. Gnanaraj P, Karthikeyan S, Narasimhan M, Rajagopalan V (2015) Decrease in "Hamilton Rating Scale for Depression" Following Isotretinoin Therapy in Acne: An Open-Label Prospective Study. *Indian J Dermatol* 60: 461-464.
84. Bozdağ KE, Gülseren S, Güven F, Cam B (2009) Evaluation of depressive symptoms in acne patients treated with isotretinoin. *J Dermatolog Treat* 20: 293-296.
85. Kaymak Y, Taner E, Taner Y (2009) Comparison of depression, anxiety and life quality in acne vulgaris patients who were treated with either isotretinoin or topical agents. *Int J Dermatol* 48: 41-46.