

Atypical fibroxanthoma of the medial canthus treated by Mohs Micrographic Surgery

Prativa SA Jayasekera^{1*}, Stuart A Osborne² and James AA Langtry³

¹Royal Victoria Infirmary, Newcastle upon Tyne BM Medicine MRCP DERM, England, UK

²Sunderland Eye Infirmary, Queen Alexandra Road, Sunderland, SR2 9HP, UK

³Royal Victoria Infirmary, Newcastle upon Tyne MBCHB Medicine, England, UK

*Corresponding author: Prativa SA Jayasekera, Royal Victoria Infirmary, Newcastle upon Tyne BM Medicine MRCP DERM, England, UK, Tel: 0191 233 6161; E-mail: prativaj@googlemail.com

Received date: 11 Apr 2017; Accepted date: 08 Jun 2017; Published date: 14 Jun 2017.

Citation: Jayasekera PSA, Osborne SA, Langtry JAA (2017) Atypical fibroxanthoma of the medial canthus treated by Mohs Micrographic Surgery. *J Clin Cosmet Dermatol* 1(3): doi <http://dx.doi.org/10.16966/2576-2826.115>

Copyright: © 2017 Jayasekera PSA, et al. This is an open-access article distributed under the terms of the Creative Commons Attribution License, which permits unrestricted use, distribution, and reproduction in any medium, provided the original author and source are credited.

Abstract

Atypical fibroxanthoma (AFX) is the most common of the rare cutaneous malignancies. AFX usually involves sites of high cumulative ultraviolet exposure and is rarely located in the periocular region. We are aware of 7 case reports in the literature, of periocular AFX, one of which was treated with Mohs Micrographic Surgery (MMS). We report our experience of a patient with AFX of the left medial canthus treated by MMS and review the literature of this rare tumour in the periocular region.

Keywords: Atypical fibroxanthoma; Micrographic Surgery

History

A 55 year old woman with skin type II/III presented with a 10 month history of an enlarging, tender nodule affecting the left medial canthus. Her past medical history included asthma, hypothyroidism and atrial fibrillation and medications included levothyroxine. She had no past history of skin cancer. She went on sunny holidays as a child but rarely as an adult and had used sunbeds approximately 100 occasions in her lifetime. An incisional biopsy of the left medial canthal nodule confirmed AFX with immune histochemistry demonstrating CD10 positivity and cytokeratin negativity, figures 1, 2 and 3. Figure 4 shows a pre operative photograph. The tumour measured 13 × 13 mm and was excised by MMS. The tumour was cleared in one stage and two blocks (Figure 5). The final defect size was 23 × 19 mm and this was repaired by a myocutaneous cheek advancement flap. Two years post operatively she has had no sign of recurrence.

Discussion

AFX is a fibrohistiocytic tumour which commonly occurs on sun exposed skin. It was first described in 1951 by Helwig. AFX commonly presents as a rapidly growing, solitary nodule, which may ulcerate, be sessile or pedunculated. AFX commonly occurs on the head and neck region, but can occur on the trunk and limbs [1].

The clinical differential diagnoses include squamous cell carcinoma, amelanotic melanoma, pyogenic granuloma and cutaneous lymphoma.

Histologically, AFX is characterized by dermal proliferation of atypical spindle cells which are arranged in a haphazard or disordered pattern. The histological variants of AFX include granular cell, clear cell, desmoplastic, haemosiderotic, osteoclast-like giant cells, pigmented form and giant cell AFX [1,2].

It is important to distinguish AFX and pleomorphic dermal sarcoma (PDS), as the metastatic rate for PDS is in excess of 20% and rare for AFX.

AFX and PDS are histologically indistinguishable from each other. PDS is diagnosed when the tumour extends beyond the dermis and represents

a deeper variant of AFX. Therefore a superficial biopsy may lead to an incorrect diagnosis of AFX. AFX and PDS may both demonstrate positive immune histochemistry for vimentin, alpha anti-trypsin, CD68, CD99 and smooth muscle actin [2].

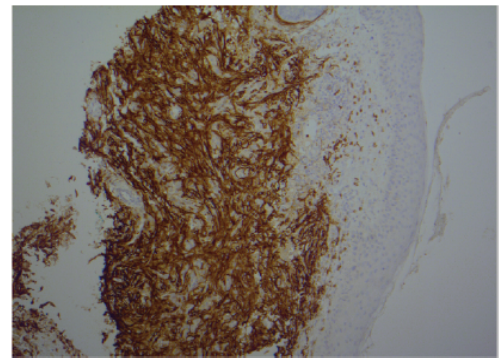


Figure 1: A figure confirming CD 10 positivity

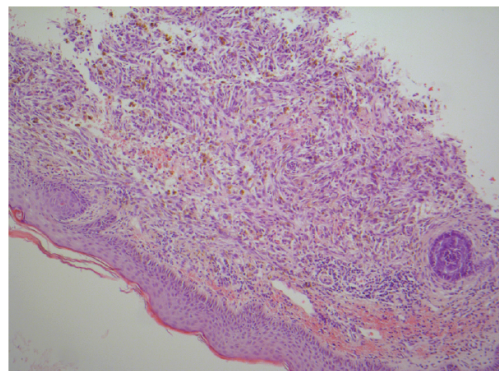


Figure 2: An H and E figure demonstrating marked cellularity and pleomorphism

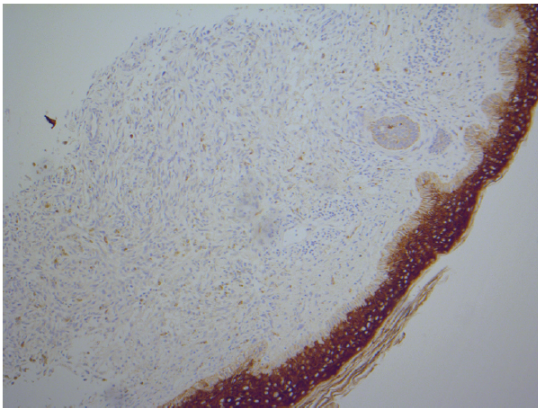


Figure 3: A figure showing negative cyokeratin.

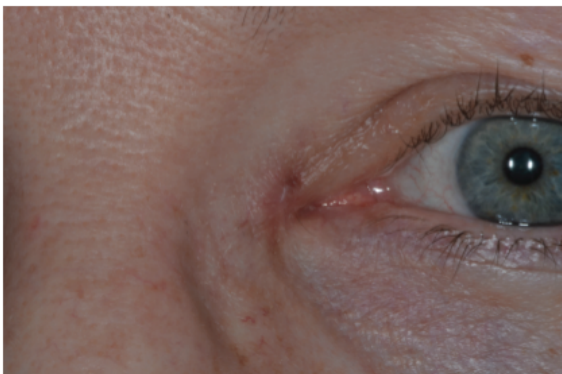


Figure 4: A medical photograph of a medical canthal nodule biopsied to be AFX

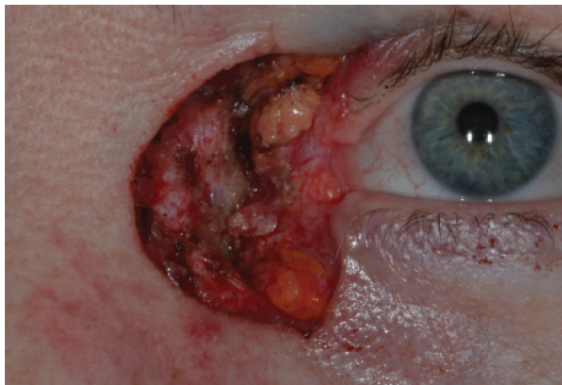

Figure 5: A photograph after tumour clearance with mohs micrographic surgery

Risk factors for AFX include actinic damage secondary to ultraviolet radiation, immunosuppression, X-ray radiation, skin trauma and xeroderma pigmentosa [1-3].

Surgical excision is recommended for AFX, however there is no consensus on the surgical margin required. AFX rarely metastasises but local recurrence is not uncommon. Local recurrence after excision has been estimated to be between 2 and 20% [3]. Seavolt and McCall [4] described MMS for AFX in thirteen patients (ear n=3, scalp n=2, chest n=1, temple n=1, cheek n=2, leg n=1, upper lip n=1, jawline n=1, neck=1, eyebrow n=1) and at 2 years follow-up data was available for 6 patients, with no recurrence found.

In a retrospective study of 45 patients, 19 patients were treated with MMS and 26 patients were treated with wide local excision (WLE). MMS resulted in a lower recurrence rate of AFX compared to WLE. In patients treated with MMS there were no recurrences with a mean follow-up of 30 months and three recurrences in patients treated with WLE with a mean follow-up of 74 months. The margin of excision was documented in 16 out of 26 patients treated with WLE, ranging from 3 to 26 mm (mean 7 mm) [5].

One large study looking at AFX treated by MMS or WLE included 91 patients with 93 tumours. The most common location was the ear followed by the scalp. Information was available for 88 out of 93 tumours, of which 59 had MMS, 23 had WLE and 6 patients had other methods of excision (electro dissection, curettage and shave excision). 36 patients who had MMS required 1 stage to clear the tumour, 19 patients required two stages and 4 patients required more than two stages. The median margin required to clear the tumour with MMS was 4mm. There were no recurrences at follow-up (median 4.5 years) following MMS and there were two recurrences following WLE [6]. The current reported recurrence with MMS is between 0-6% and with wide local excision (WLE) 16% [6].

Periocular AFX is rare with seven cases reported in the literature, involving the medial canthus (n=1) [7] lower eyelid (n=4) [3,8-10], upper eyelid (n=1) [11] and lower eyelid and cheek (n=1) [12].

Table 1 presents all published cases of periocular AFX. The majority of the patients were male, with an average age of 63 years. The size of the tumour ranged from 6 × 6.5 mm to 60 × 60 mm (Table 1). Five patients underwent excision, one had MMS and the method of the tumour removal was not documented for one patient. There were no documented recurrences, at follow-up ranging from 6 months to 1 year.

Paramanathan et al. [9] reported a patient with recurrent AFX of the lower eyelid. The tumour was first removed with clear excision margins. Two months later it recurred within the scar site. The patient then underwent a second excision with a 5 mm margin, without recurrence at 12 months.

Rice et al. [12] reported a patient with a 30 mm diameter AFX, of the right lower eyelid and cheek treated by MMS. Tumour negative margins resulted in a defect size of 60 × 60 mm and there was no recurrence at 1 year follow-up.

Table 1: A table summarising published case reports of periocular AFX

Author, Year of publication	Gender	Age	Location of tumour	Size in mm	Duration of tumour in weeks	Type of tumour removal	Recurrence	Follow-up in months
Haye C, 1981	Female	31	Upper eyelid	5 x 6	104	Excision	Not documented	Not documented
J Boynton, 1989	Female	58	Lower eyelid	6 x 6.5	6	Excision	Not documented	Not documented
C Rice, 1991	Male	82	Lower eyelid and cheek	60 x 0 6	Not documented	MMS	No	12
N Paramanathan, 2008	Male	61	Lower eyelid	5	8	Excision	No	12
A Kilic, 2008	Female	12	Lower eyelid	10 x 5	Several months	Excision	No	5
U Kim, 2009	Male	78	Lower eyelid	60 x 50	156	Excision	No	6
D Rahore, 2013	Female	90	Medial canthus	15 x 15	Not documented	Excision	No	12

Conclusion

Our case highlights the use of MMS for periocular AFX. MMS tumour clear margins allows a high level of certainty of tumour clearance with likely higher cure rate and tissue sparing which are critical in the surgical oncology of the periocular skin.

We advocate the use of MMS for AFX of the periocular skin in order to achieve tumour clear histological margins and the potential for tissue sparing.

References

1. Clover AJP, Athanassopoulos A, Hafeez A, Chakrobarty R, Budny PG (2008) Atypical fibroxanthoma: 10-year experience from a single unit. *Eur J Plast Surg* 31: 51-54.
2. Fretzin DF, Helwig EB (1973) Atypical fibroxanthoma of the skin. A clinicopathologic study of 140 cases. *Cancer* 31: 1541-1552.
3. Boynton JR, Markowitch W Jr, Searl SS (1989) Atypical fibroxanthoma of the eyelid. *Ophthalmology* 96: 1480-1484.
4. Seavolt M, McCall M (2006) Atypical fibroxanthoma: review of the literature and summary of 13 patients treated with mohs micrographic surgery. *Dermatol Surg* 32: 435-441.
5. Davis JL, Randle HW, Zalla MJ, Roenigk RK, Brodland DG (1997) A comparison of Mohs micrographic surgery and wide excision for the treatment of atypical fibroxanthoma. *Dermatol Surg* 23: 105-110.
6. Ang GC, Roenigk RK, Otley CC, Kim Phillips P, Weaver AL (2009) More than 2 decades of treating atypical fibroxanthoma at mayo clinic: what have we learned from 91 patients? *Dermatol Surg* 35: 765-772.
7. Rathore D, Mohyudin MN, Mehta P, Ahluwalia HS (2013) Atypical fibroxanthoma of the medial canthus: a rare presentation. *Orbit* 32: 194-196.
8. Paramanathan N, Gal A, Bengner R (2009) Paraffin histology sections and delayed repair in recurrent atypical fibroxanthoma of the eyelid. *Orbit* 28: 380-382.
9. Kilic A, Kosem M, Cinal A, Yaşar T, Demirok A (2008) Atypical fibroxanthoma of the eyelid. *Eur J Gen Med* 5: 45-47.
10. Kim UR, Arora V, Shanti R, Shah AD (2009) Neglected giant atypical fibroxanthoma of the eyelid. *Ophthal Plast Reconstr Surg* 25: 408-409.
11. Haye C, Niessen F, Dhermy P (1981) Atypical fibroxanthoma of the eyelid. Apropos of a case. *Bull Soc Ophtalmol Fr* 81: 415-417.
12. Rice CD, Gross DJ, Dinehart SM, Brown HH (1991) Atypical fibroxanthoma of the eyelid and cheek. *Arch Ophthalmol* 109: 922-923.