

The Treatment of Café Au Lait spot, Partial Unilateral Lentiginosis and Becker's Nevus Using a High Fluence 1064-nm Q-Switched Nd: YAG Laser

Hoon Hur*, Yu Ri Kim, and Duck Taik Shim

Choice Dermatology Clinic, Pyeongchon, Korea

*Corresponding author: Hoon Hur, Choice Dermatology Clinic, 1045, Hogyedong, Dongan-gu, Anyang-si, Gyeonggi-do, Pyeongchon, Korea, E-mail: dermahur@naver.com

Received date: 30 Jan 2017; Accepted date: 10 Mar 2017; Published date: 16 Mar 2017.

Citation: Hur H, Kim YR, Shim DT (2017) The Treatment of Café Au Lait spot, Partial Unilateral Lentiginosis and Becker's Nevus Using a High Fluence 1064-Nm Q-Switched Nd: Yag Laser. J Clin Cosmet Dermatol 1(2): doi <http://dx.doi.org/10.16966/2576-2826.111>

Copyright: © 2017 Hur H, et al. This is an open-access article distributed under the terms of the Creative Commons Attribution License, which permits unrestricted use, distribution, and reproduction in any medium, provided the original author and source are credited.

Abstract

Café au lait spot (CALs), partial unilateral lentiginosis (PUL) and Becker's nevus (BN) are recalcitrant pigmentary skin diseases. Histopathologically, since nevus cell does not exist in CALs, PUL and BN, and these lesions of CALs, PUL and BN are not changed into malignant lesion, therefore CALs, PUL and BN are the benign pigmentary skin diseases. That said, treatment is not necessary for CALs, PUL and BN except cosmetic concerns. However, treatment for CALs, PUL and BN without side effects such as postinflammatory hyperpigmentation (PIH), scars and recurrences cannot be found in any literature yet. Therefore, the authors introduce the treatment of CALs, PUL and BN using a high fluence 1064-nm Q-switched Nd: YAG laser without the side effects or recurrences.

Keywords: Café au lait spot; Partial unilateral lentiginosis; Becker's nevus; High fluence; 1064-nm Q-switched Nd: YAG laser; No side effects; No recurrences

Introduction

In general, CALs, PUL and BN are the developmental pigmentary skin disorders without malignant potential because histopathologically, the nevus cell does not exist in CALs, PUL and BN [1-4]. The treatment is not necessary for CALs, PUL and BN except cosmetic concerns [1-4].

But the treatments for CALs, PUL and BN without side effects such as post inflammatory hyperpigmentation (PIH), scars and recurrences are extremely difficult. Therefore, the authors introduce the treatment of CALs, PUL and BN using a high fluence 1064-nm Q-switched Nd: YAG laser without the side effects or recurrences [5-8].

Report of Cases

One Korean patient with CALs (a 15 year-old girl), two Korean patients with PUL (a 22 year-old lady and a 24 year-old lady) and one Korean patient with BN (a 40 year-old man) participated in this study. All of 4 patients were clinically diagnosed. Otherwise, the patients had no significant medical or familial history. After obtaining written informed consent, all of the 4 patients were subjected to 50 treatment sessions of a 1064-nm Q-switched Nd: YAG laser (Spectra Laser, Lutronic, South Korea) at a one-week interval with a spot size of 7 mm, a fluence of 2.4 J/cm² and a pulse rate of 10 Hz with slowly one pass by sliding-stacking technique to the pigmentary lesion. Ice packs were immediately applied to the entire face after laser treatment sessions, and patients were instructed to use a broad-spectrum sunscreen daily. Patient photos were obtained on the day of treatment and 4 weeks after the final session. The evaluation was performed by standardized digital photography using a Canon Camera G11 (Japan). Patients were asked to report any side effects, pain or discomfort during the treatment. All patients were satisfied with the results, and no any significant side effects, including purpura, post inflammatory hyperpigmentation and scarring except slight pain during the laser treatment.

Discussion

Café au lait spot (CALs), partial unilateral lentiginosis (PUL) and Becker's nevus (BN) are recalcitrant pigmentary skin diseases without malignant potential [1-4].

In solitary CALs, PUL and BN, the expression of endothelin-1 is increased in the keratinocytes and the expression of stem cell factor (SCF) is increased in the fibroblasts compared to those of normal skins. The increased expression of endothelin-1 and SCF activates the melanocytes and increases melanin synthesis in the melanosomes, therefore causing solitary CALs, PUL and BN [9-12]. However, basic fibroblast growth factor (bFGF) that may provoke melasma and PIH [9-12]. Given that bFGF in the keratinocytes of CALs, PUL and BN is not increased, bFGF may not cause CALs, PUL and BN [9-12].

For a lot of years electromagnetic radiation (EMR) from lasers, flesh lamps and other EMR sources has been used to treat the pigmentary skin diseases such as CALs, PUL and BN. EMR, targeting the melanin chromophore well described the theory of selective photothermolysis (SPTL) [6]. The treatments with many lasers or intense pulse light (IPL) were performed but the traditional laser treatments were unsatisfactory for CALs, PUL and BN. Because the common side effects such as PIH, scars and recurrences occurred after traditional laser treatment [6-8].

There are possible four reasons of failure when treating CALs, PUL and BN with traditional laser treatment. First, 532-nm of Q-Switched Nd: YAG laser, 694-nm of Ruby laser, 755-nm of alexandrite, and 515-755 nm of IPL absorb much more melanin compared to 1064-nm of Q-Switched Nd: YAG laser. Thus, fluence that destroys epidermal melanocytes injures the surrounding keratinocytes, and the damaged keratinocytes secrete endothelin-1, α MSH, ACTH, prostaglandin (PGE₂, PGF₂ α) and nitric oxide. These cytokines activate melanocytes and increase melanin synthesis in the melanosomes, therefore causing PIH and worsening CALs, PUL and BN [9-12].

Second, the keratinocytes secrete urokinase type plasminogen activator (U-type PA) that converts plasminogen into plasmin. This plasmin stimulates the keratinocytes, which secrete bFGF that activates the melanocytes and increase melanin synthesis in the melanosomes, therefore causing PIH and worsening CALS, PUL and BN. The authors believe that bFGF, a major cytokine, causes PIH and melasma because tranexamic acid (500 mg/day for 90 days), which suppresses U-type PA and plasmin, improves melasma and PIH [9-12].

Third, as the traditional laser treatment causes petechiae and crusts, irradiated fluence may damage fibroblasts, mast cells, lymphocytes, macrophages, and vascular endotheliums. Then, fibroblasts mainly secrete SCF and mast cells, in which the activation of arachidonic metabolites occurs, secrete histamine. The arachidonic metabolites and histamine cause inflammatory reaction that activates melanocytes and increases melanin synthesis in the melanosomes, eventually causing PIH and worsening CALS, PUL and BN [9-12].

Lastly, free radical oxygen and peroxide from the keratinocytes also activates melanocytes and increase melanin synthesis in the melanosomes, eventually causing PIH and worsening CALS, PUL and BN [9-12]. To solve the side effects such as PIH and worsening CALS, PUL and BN of the traditional laser treatment, the authors devised the treatment using a high fluence 1064-nm Q-switched Nd: YAG laser [5]. The authors would like to name this therapy "Golden Parameter Therapy" because the authors believe that it can improve various skin diseases (Table 1) [5]. The Golden Parameter with a 1064 nm Q-switched Nd: YAG laser may destroy melanocytes without keratinocyte damage, and the products of damaged melanocytes will be removed through transepidermal elimination [5,10-12]. Then, basement membrane breaks down and epidermal melanocytes secrete melanin into the upper dermis. Thus, after phagocytizing this melanin, dermal melanophage is eliminated through dermal lymphatics. By apoptotic melanocytic cell death and homeostasis, normal melanocytes in outer root sheath of hair migrate to basal layer and abnormal melanocytes are displaced into normal melanocytes in the basal layer [5,10-12]. It is the authors' theory that this laser treatment can be performed complete clearance of the CALS PUL and BN without side effects or recurrences [5].

A high fluence 1064-nm Q-switched Nd: YAG laser Treatment can be summarized as follows

First, the mechanism of a high fluence 1064-nm Q-switched Nd: YAG laser treatment is to minimize the epidermal damage and destroy melanosomes in the epidermal melanocytes, which are changed into

Cafe au lait spot
Agminated lentiginosis (Partial unilateral lentiginosis)
Becker's nevus
Nevus spilus
Linear and whorled nevoid hypermelanosis
Incontinentia pigmenti
Acquired bilateral nevus of Ota-like macules (ABNOM)
Melasma
PIH
Erythema dyschroicum perstans
Pityriasis rotunda
pigmented contact dermatitis (Riehl's melanosis)
Dowling-Degos disease
Onychomycosis
Verruca plana
Removal of vellus hair

Table 1: Indication of a high fluence 1064-nm Q-switched Nd: YAG laser treatment

ghost cells due to the loss of function. Then, weekly a high fluence 1064 nm Q-switched Nd:YAG laser treatment destroys melanocytes completely, accelerates apoptotic melanocyte cell death, thus removing abnormal epidermal melanocytes [5,10-12]. Eventually, abnormal melanocytes are displaced into normal melanocytes which migrate from outer root sheath of hair [5,10-12]. In conclusion, complete clearance of CALS, PUL and BN without side effects and recurrences can be achieved.

Second, patients with CALS or PUL or BN are treated with 30-50 sessions of a 1064 nm Q-switched Nd: YAG laser (Spectra Laser, Lutronic, South Korea) at a one-week interval with a spot size of 7 mm, a fluence of 2.4 J/cm² and a pulse rate of 10 Hz with slow one pass by sliding-stacking technique to the CALS or PUL or BN. One pass of fluence by sliding-stacking technique is very important to minimize the epidermal damage [5]. If two passes of fluence by sliding-stacking technique were performed, the epidermal damages might have occurred and the damaged keratinocytes might have secreted cytokines such as endothelin-1, α-MSH, ACTH, bFGF, prostaglandin(PGE2, PGF2α) and nitric oxide which could cause PIH and worsen CALS, PUL and BN [5,10-12].

Third, in case of CALS or PUL or BN on face, 30 treatment sessions are performed once a week. Small lesion with a diameter of less than 2 cm requires 30 treatment sessions on a weekly basis. And large lesion with a diameter of larger than 3 cm needs 50 treatment sessions once a week. In case of CALS or PUL or BN on other parts of body (arms, legs, and torso), more than 50 treatment sessions should be performed once a week regardless of the size of lesion. The advantage of a high fluence 1064 nm Q-switched Nd: YAG laser treatment is that it minimizes the epidermal damage without petachiae and crusts so this therapy does not cause PIH. But a high fluence 1064 nm Q-switched Nd: YAG laser treatment requires a long-term treatment for one year. In this study, one patient with a solitary CALS (Figure 1), two patients with PUL and one patient with BN were treated with a high fluence 1064-nm Q-switched Nd: YAG laser. One patient with a solitary CALS, two patients with PUL and one patient with BN were achieved complete clearance of the lesions (Figures 2-9). There are no recurrences at 18 months follow-up (Figure 3).

Conclusion

The parameter for each a high fluence 1064 nm Q-switched Nd: YAG laser treatment was a spot size of 7 mm, a fluence of 2.4 J/cm² with one pass and a pulse rate of 10 Hz. This parameter does not provoke side

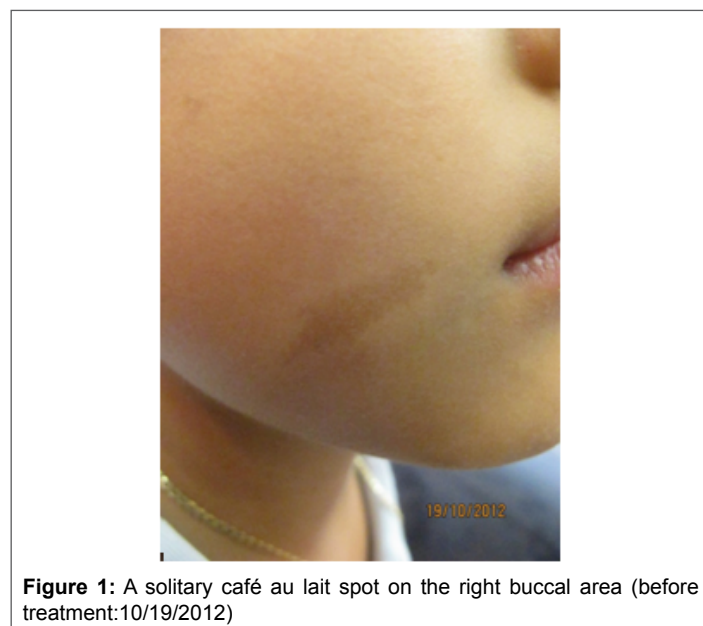


Figure 1: A solitary café au lait spot on the right buccal area (before treatment:10/19/2012)

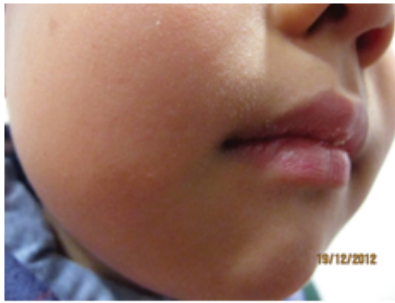

Figure 2: A complete clearance of café au lait spot (after treatment:12/19/2012)

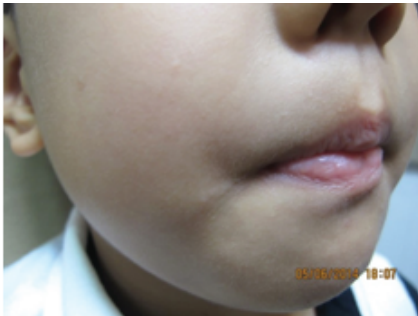

Figure 3: There is no recurrence at 18 months follow-up (6/5/2014).

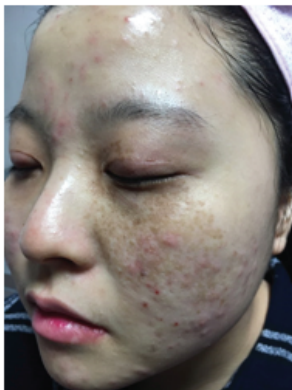

Figure 4: Partial unilateral lentiginosis on the left periorbital area and left maxillary area (before treatment)

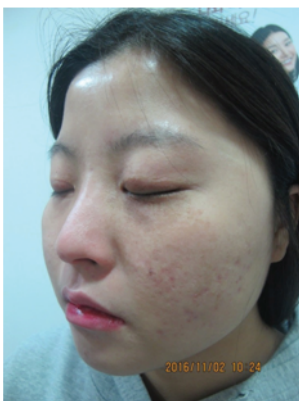

Figure 5: A complete clearance of partial unilateral lentiginosis (after treatment)

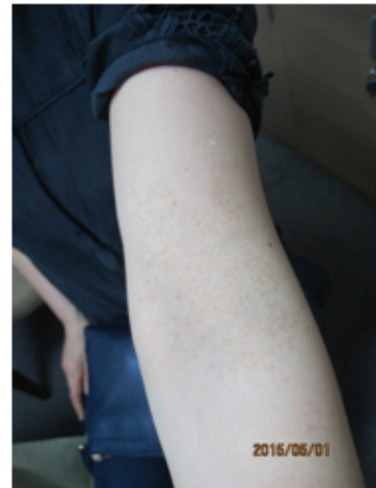

Figure 6: Partial unilateral lentiginosis on the left antecubital area (before treatment)

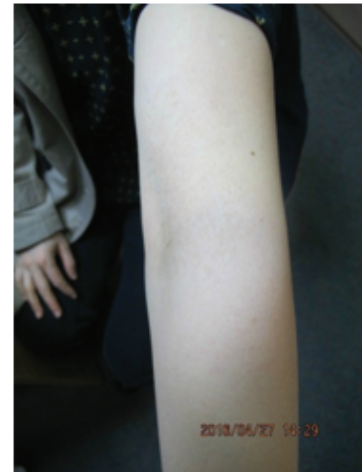

Figure 7: A complete clearance of partial unilateral lentiginosis on the left antecubital area (after treatment)

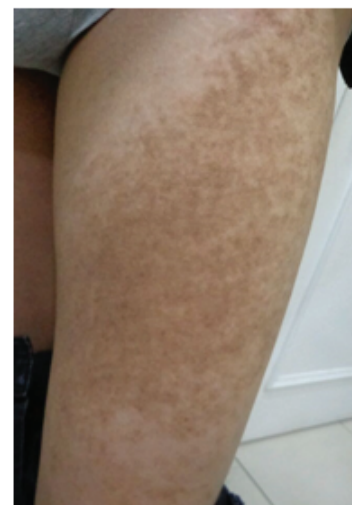

Figure 8: Becker's nevus on the left thigh (before treatment)

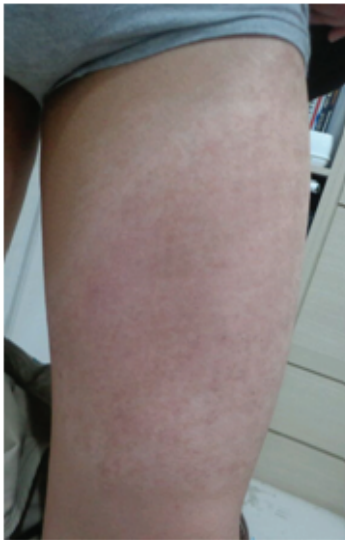

Figure 9: A complete clearance of Becker's nevus (after treatment)

effects such as petechiae, crusts, pain, and PIH during the laser treatment. Therefore, the authors suggest a high fluence 1064 nm Q-switched Nd: YAG laser treatment achieves complete clearance of CALS, PUL and BN with a very safe and effective profile.

References

1. Nguyen JT, Yan AC, James WD (2004) Large solitary cafe au lait spots: A report of 5 cases and review of the literature. *Cutis* 73: 311-314, 316.
2. Landau M, Krafchik BR (1999) The diagnostic value of café-au-lait macules. *J Am Acad Dermatol* 40: 877-890.
3. Pique E, Aguilar A, Farina MC, Gallego MA, Escalonilla P, et al. (1995) Partial unilateral lentiginosis: report of seven cases and review of the literature. *Clin Exp Dermatol* 20: 319-322.
4. Grande SH, Harris R, Hansen CD, Duffin KPC, Florell SR, et al. (2008) Androgen receptor expression patterns in Becker's nevi: An immunohistochemical study. *J Am Acad of Dermatol* 59: 834-838.
5. Hur H (2016) The treatment of café au lait spot using Dr. Hoon Hur's Golden Parameter Therapy. *J Dermatol Ther* 1: 1-4.
6. Anderson RR, Margolis RJ, Watanabe S, Flotte T, Hruza GJ, et al. (1989) Selective photothermolysis of cutaneous pigmentation by Q-switched Nd: YAG laser pulses at 1064, 532 and 355 nm. *J Invest Dermatol* 93: 28-32.
7. Geronemus RG (1992) Q-switched ruby laser therapy of nevus of Ota. *Arch Dermatol* 128: 16118-622.
8. Mihara M (2013) Eczematous dermatitis occurring on cafe au-lait spot after laser radiation. *Case Rep Dermatol* 5: 133-137.
9. Schepper SD, Boucneau J, Haeghen YV, Messiaen L, Naeyaert JM, et al. (2006) Café-au-lait spots in neurofibromatosis type 1 and in healthy control individuals: hyperpigmentation of a different kind? *Arch Dermatol Res* 297: 439-449.
10. Hattori H, Kawashima M, Ichikawa Y, Imokawa G (2004) The epidermal stem cell factor is over-expressed in lentigo senilis: Implication for the mechanism of hyperpigmentation. *J Invest Dermatol* 122: 1256-1265.
11. Okazaki M, Yoshimura K, Suzuki Y, Uchida G, Kitano Y, et al. (2003) The mechanism of epidermal hyperpigmentation in café-au-lait macules of neurofibromatosis type 1 (von Recklinghausen's disease) may be associated with dermal fibroblast-derived stem cell factor and hepatocyte growth factor. *Br J Dermatol* 148: 689-697.
12. Okazaki M, Yoshimura K, Uchida G, Suzuki Y, Kitano Y, et al. (2005) Epidermal hyperpigmentation in non-syndromic solitary café-au-lait macules may be associated with increased secretion of endothelin-1 by lesional keratinocytes. *Scand J Plast Reconstr Surg Hand Surg* 39: 213-217.