

# Allergic Contact Dermatitis to Artificial Fingernails

László Képiró<sup>1\*</sup>, Ágnes Kinyó<sup>1,2</sup>, Anita Altmayer<sup>1</sup>, Lajos Kemény<sup>1</sup> and Zsuzsanna Bata-Csörgő<sup>1</sup>

<sup>1</sup>Department of Dermatology and Allergology, University of Szeged, Hungary

<sup>2</sup>Department of Dermatology, Venereology and Oncodermatology, University of Pécs, Hungary

\*Corresponding author: László Képiró, Department of Dermatology and Allergology, University of Szeged, Hungary, Tel: 36-62-545259; Fax: 36-62-545954; E-mail: kepirolaszlo@med.u-szeged.hu

Patients treated for chronic hand eczema more frequently have allergic contact dermatitis to artificial nails. The most common allergens are the acrylates, which were first reported as the cause of allergic contact dermatitis in 1941 [1]. Acrylates can cause both occupational and non-occupational allergic contact dermatitis [2].

## Case Report

A 43-year-old female patient is presented, who was admitted to our department with perioral erythema and lump in her throat (Figure 1). She had artificial fingernails with erythema, edema and dyshidrosiform eczema on her fingers and hands (Figure 2). On history taking the patient admitted nail biting.

The patient had been wearing artificial fingernails for more than ten years. Five years earlier she was seen at our department with nail fold dermatitis. One month prior her admission, she was seen again at our department because of vesicles on her fingers and hands. Allergic contact dermatitis to artificial fingernails was suspected, the artificial fingernails were removed and the symptoms healed again with topical steroid therapy. The patient had no symptoms for two weeks, when she had artificial fingernails put on again. Immediately after the procedure erythema, dyshidrosiform vesicles and dermatitis appeared on her fingers and hands. A few days later she felt lump in her throat and perioral erythema developed.

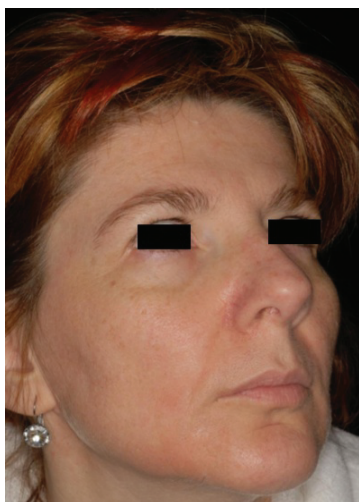

Figure 1: Perioral erythema on the patient's face

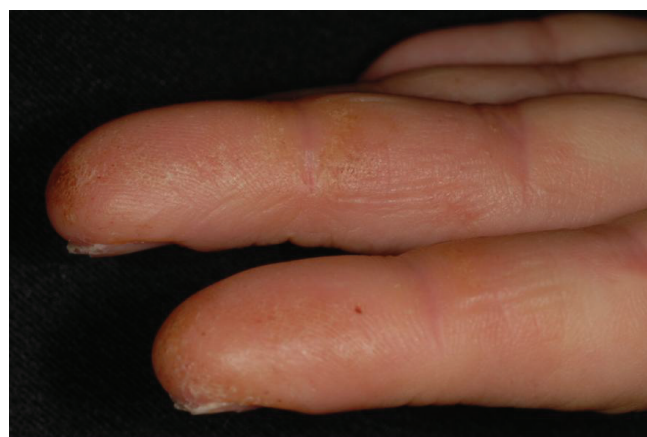

Figure 2: Dyshidrosiform dermatitis on the fingers

Received date: 09 Feb 2016; Accepted date: 07 May 2016; Published date: 11 May 2016.

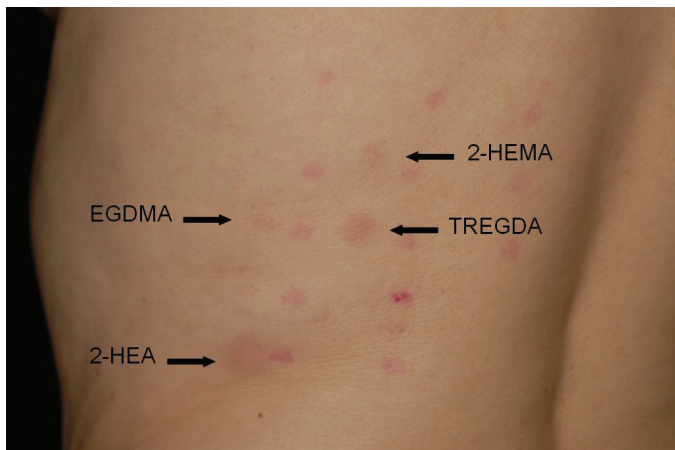
Citation: Képiró L, Kinyó A, Altmayer A, Kemény L, Bata-Csörgő Z (2016) Allergic Contact Dermatitis to Artificial Fingernails. J Clin Case Stu 1(3): doi <http://dx.doi.org/10.16966/2471-4925.115>

Copyright: © 2016 Képiró L, et al. This is an open-access article distributed under the terms of the Creative Commons Attribution License, which permits unrestricted use, distribution, and reproduction in any medium, provided the original author and source are credited.

Epicutaneous patch tests for artificial fingernail were occluded on her upper back (BRIAL Allergen GmbH, Germany). Positive reactions (+ and ++) were seen in cases of 2-hydroxy ethyl acrylate (2-HEA), triethylene glycol diacrylate (TREGDA), 2-hydroxy ethyl methacrylate (2-HEMA) and ethylene glycol dimethacrylate (EGDMA) (Figure 3). The patient was advised to remove her artificial fingernails and during the procedure she wore a surgical face mask. This way she was protected from the polymethacrylate dust getting into the air while her artificial fingernails were scraped off, and her perioral erythema did not increase nor did she feel lump in her throat again. Her symptoms healed rapidly following the topical steroid and oral antihistamine therapies.

## Discussion

There are three distinct types of artificial acrylate nails: glued nails, acrylic sculptured nails and photo-bonded sculptured nails [3]. The main component of the glue is cyanoacrylate, a well-known cause of irritant contact dermatitis besides allergic contact dermatitis [4]. Methylmethacrylate was first reported in 1941 as a cause of allergic contact dermatitis beside irritant contact dermatitis [1]. Since then, occupational contact allergies to acrylates in plastic industry, printing industry, dentistry, orthopedic surgery and beauty industry have been reported where erythema on the patient's face, lips, eyelids and feeling lump in the throat develops due to organic vapors and acrylate polymer dusts exposure [5]. The acute signs of allergic contact dermatitis to artificial nails are erythema, edema and dyshidrosiform vesicles of the fingers, hands and forearms. Chronic signs include lichenification on the finger and hand, paronychia and permanent nail dystrophies [6]. Sometimes the signs are



**Figure 3:** Positive patch tests at 72-hour reading  
EGDMA: Ethylene Glycol Dimethacrylate; 2-HEA: 2-Hydroxy Ethyl Acrylate;  
2-HEMA: 2-Hydroxy Ethyl Methacrylate; TREGDA: Triethylene Glycol Diacrylate

accompanied with sharp pain and peripheral paresthesias [7]. Erythema of the face, lips and eyelids are seen on patients with non-occupational allergic contact dermatitis touching their faces with artificial nails [8]. The medical history, the improving symptoms after artificial nail removal and the positive artificial nail patch test help to set up the diagnosis. Beside topical steroid treatment, removal of the artificial nails or change for acrylate free ones are essential for patient recovery [3].

Our case illustrates how much patients can be committed to wearing their artificial fingernails. The patient accepted the diagnosis and the role of the artificial nails in her disease only after the positive artificial nail patch tests. The perioral erythema and lump in her throat were typical signs of non-occupational allergic contact dermatitis to artificial nails, her nail biting contributed significantly to the development of these symptoms.

## References

1. Stevenson WJ (1941) Methyl methacrylate dermatitis. *Contact Point* 18:171.
2. Farli M, Gasperini M, Francalanci S, Gola M, Sertoli A (1990) Occupational contact dermatitis in 2 dental technicians. *Contact Dermatitis* 22: 282-287.
3. Constandt L, Hecke EV, Naeyaert JM, Goossens A (2005) Screening for contact allergy to artificial nails. *Contact Dermatitis* 52: 73-77.
4. Baran R (2002) Nail cosmetics: allergies and irritations. *Am J Clin Dermatol* 3: 547-555.
5. Drucker AM, Pratt MD (2011) Acrylate contact allergy: patient characteristics and evaluation of screening allergens. *Dermatitis* 22: 98-101.
6. Maio P, Carvalho R, Amaro C, Santos R, Cardoso J (2012) Letter: Allergic contact dermatitis from sculptured acrylic nails: special presentation with a possible airborne pattern. *Dermatol Online J* 18: 13.
7. Fisher AA (1990) Adverse nail reactions and paresthesia from "photobonded acrylate 'sculptured' nails". *Cutis* 45: 293-294.
8. Lazarov A (2007) Sensitization to acrylates is a common adverse reaction to artificial fingernails. *J Eur Acad Dermatol Venereol* 21: 169-174.