

Lethal Co-infection with *Coccidioides immitis/posadasii*, MAI, and *Pneumocystis jirovecii* as a First Presentation of HIV

Jennifer Townsend^{1*} and Tobias Pusch²

¹Johns Hopkins Bayview Medical Center, Baltimore, MD, USA

²Providence Infectious Diseases Consultants-West, Providence, Portland OR, USA

*Corresponding author: Jennifer Townsend, Johns Hopkins Bayview Medical Center, Baltimore, MD, USA, Tel: 410-404-4732; E-mail: holmseyj@gmail.com

Received date: 01 Dec 2015; Accepted date: 07 Mar 2016; Published date: 14 Mar 2016.

Citation: Townsend J, Pusch T (2016) Lethal Co-infection with *Coccidioides immitis/posadasii*, MAI, and *Pneumocystis jirovecii* as a First Presentation of HIV. J Clin Cas Stu 1(2): doi <http://dx.doi.org/10.16966/2471-4925.108>

Copyright: © 2016 Townsend J, et al. This is an open-access article distributed under the terms of the Creative Commons Attribution License, which permits unrestricted use, distribution, and reproduction in any medium, provided the original author and source are credited.

Abstract

A 39-year old Mexican male with no past medical history presented to a teaching hospital in Dallas, Texas with dyspnea on exertion, cough, and fever. Clinical exam revealed crackles and wheezing in both lung bases. Laboratory studies revealed a positive rapid test for human immunodeficiency virus (HIV), but negative sputum cultures. His chest radiograph showed right paratracheal opacity and interstitial infiltrates. He developed worsening respiratory distress and required intubation, which was complicated by bilateral pneumothoraces and eventual death. He was diagnosed quickly with *Pneumocystis jirovecii*, but it took 13 days to grow *Coccidioides immitis* from his blood, and 22 days to grow *Mycobacterium avium* from his sputum, which was too late to alter his course. Given the frequency with which HIV patients acquire multiple opportunistic infections, rapid diagnostics are necessary in improving outcomes in these patients.

In the era of highly effective antiretroviral therapy, fewer patients with human immunodeficiency virus are dying of opportunistic infections (OIs). However, patients who go undiagnosed until late in the disease course may present with multiple OI's at once, creating diagnostic and therapeutic challenges. This report describes a patient who presented with two classic OIs in addition to disseminated coccidiomycosis. His case took nearly 2 weeks to diagnose and had a fatal outcome. Rapid diagnostics are important and can be life-saving to initiate effective therapy, and may have been useful in this case. Mechanisms of immune suppression and interaction between OIs are discussed.

Case Report

The patient is a 39 year-old male from the northwestern Mexican state of Sonora, with no known past medical history who presented to the emergency room complaining of increasing dyspnea on exertion and cough for three weeks. He was active and feeling well around one month prior when he started getting progressively weak and short of breath to the point that he was no longer able to perform his job as a construction worker. Over the preceding two weeks he had developed high fevers and drenching sweats at home. He denied any rash, diarrhea, abdominal pain, or weight loss. He denied any sick contacts prior to his illness, though he reported multiple male and female sexual partners over the past year. He had been a resident of Dallas, Texas for three years and had not returned to Mexico since that time.

In the emergency department, he was noted to be febrile to 38.6°Celsius, hypoxic to 88% on room air, and tachypneic. His exam revealed a well-developed male in moderate respiratory distress with wheezing and crackles in the bases of both lungs. His labs were unremarkable apart from a positive rapid HIV screen. His chest radiograph showed right paratracheal opacity and interstitial infiltrates. He was admitted for evaluation, started on ceftriaxone and azithromycin, and the Infectious Diseases service was consulted. He was initiated on intravenous trimethoprim-sulfamethoxazole and solumedrol for suspected *Pneumocystis jirovecii* pneumonia. Initial evaluation revealed a CD4 count of 18 cells/μL (365-1437), a lactate dehydrogenase (LDH) level of 447, a (1-3)-β-D-Glucan (BDG) level >500 pg/ml (normal <60 pg/mL), and a ferritin of 9,074 ng/mL (normal <150 ng/mL). Initial bacterial sputum cultures were negative, and two sputum specimens for *Pneumocystis jirovecii* were positive (given below). He continued to spike fever to 39°C daily despite antibiotic therapy, and his oxygen requirements increased. On hospital

day (HD) #5, a chest computed tomography (CT) was performed which revealed mosaic pulmonary attenuation, innumerable pulmonary nodules with both a random and centrilobular distribution (Figure 1), as well as enlarged mediastinal and paratracheal lymph nodes up to two cm. On HD#6 he was transferred to the intensive care unit (ICU) on 100% oxygen and was started on broad spectrum antibacterial therapy, antituberculous therapy (RIPE), and antifungal therapy with liposomal amphotericin B at 5 mg/kg IV q 24 hours.

Initially his fever and hypoxia improved, but by HD#12 he suffered respiratory distress and progressive sepsis requiring intubation with

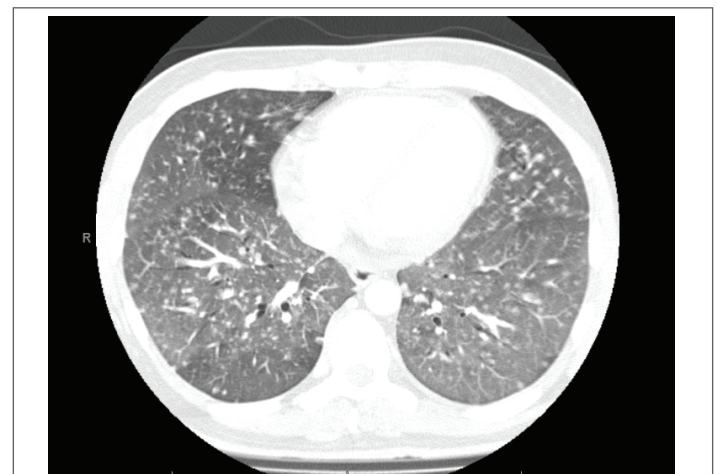

Figure 1: Chest tomography demonstrating ground glass opacities, small centrilobular nodules, and randomly distributed nodules.

paralytically, followed by shock requiring vasopressors. Over the next several days in the ICU he developed recurrent fever as well as a rash characterized by scaly plaques on his bilateral buttocks, medial thighs, and scattered papules over his chest and arms. He was noted to have thickened toenails with a blackened area of paronychia on the right foot with subungual debris, which was sent for culture. The patient unfortunately developed sequential bilateral pneumothoraces on the ventilator and refractory respiratory acidosis despite chest tube placement and maximal ventilator support. He expired on HD #27.

An extensive microbiologic workup was undertaken during his hospital stay. Routine bacterial blood cultures were submitted on admission and again on HD# 9. The latter were reported as positive for yeast after 4 days of growth. The interpretation of the gram stain was modified to fungus after further examination. These were posthumously identified as *Coccidioides immitis/posadasii*. Biopsies were taken of the left arm which revealed endovascular spherules and endospores (Figure 2). Eventually, *Coccidioides* was isolated from multiple blood and fungal cultures including blood cultures from HD#4, 12, 13,16, 20, and 24; sputum cultures, tissue culture from his left arm, a skin swab of his groin, and clippings from his toenail. A gram stain of the blood culture bottle is shown in Figure 3.

A blood interferon assay for tuberculosis (T-spot™) was negative. Four sputum specimens were submitted for AFB smears which were negative. On HD#22, two of his AFB sputum cultures turned positive, which were posthumously identified as *Mycobacterium avium-intracellulare* (MAI).

Identification of *Mycobacterium avium complex*

Sputum specimens were submitted and decontaminated for mycobacterial identification per CDC protocol [1]. The resulting sediment was inoculated onto two Löwenstein-Jensen (Gruft modification) and one Middlebrook 7H10 slants (both Remel™; Lenexa, Kansas, USA) and incubated at 37°C in ambient air. An aliquot was pipetted into a mycobacterium growth indicator tube (MGIT™ Becton Dickinson BBL™, Sparks, Maryland, USA) containing modified 7H9 broth base, OADC growth supplement and 0.8 ml of reconstituted, lyophilized PANTA. The tube was incubated in 37°C in ambient air in an automated BD Bactec MGIT Instrument. The instrument identified the tube as positive on HD #22 which was confirmed by Ziehl-Neelsen staining and again subcultured to slants as stated above. The acid-fast positive MGIT broth or solid culture colonies respectively were then tested using nucleic acid hybridization probes for *M. tuberculosis* and *M. avium complex*, utilizing

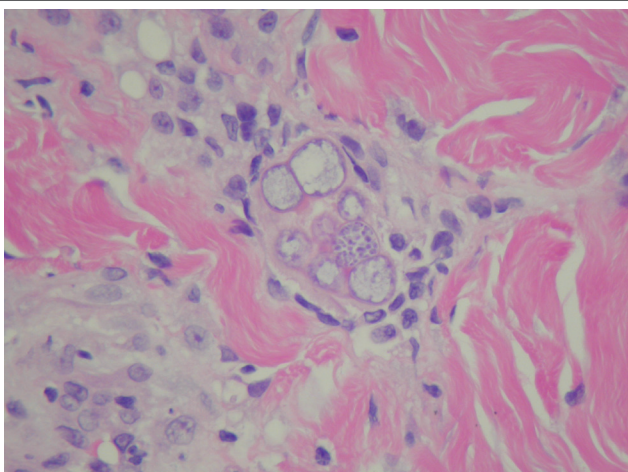


Figure 2: Skin biopsy showing endospherules of *Coccidioides* in the dermis. H and E,40x

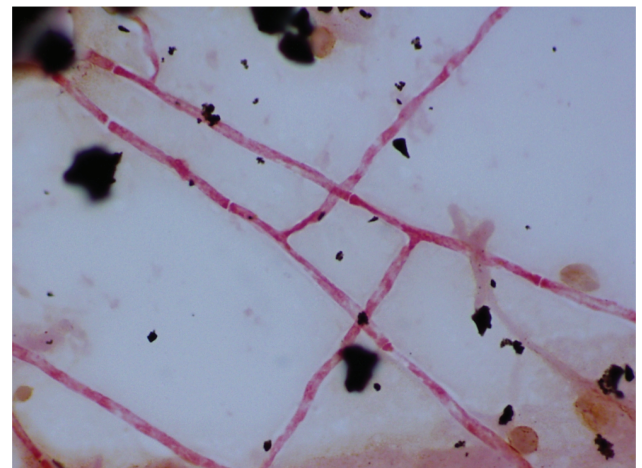


Figure 3: Gram stain of a blood culture bottle showing hyphae of *Coccidioides immitis/posadasii*. 100x, oil immersion.

the Leader 450i luminometer system (Gen-Probe Inc., San Diego, CA, USA), irrespective of colony morphology due to the high incidence of both mycobacteria at Parkland Memorial Hospital.

The isolate was identified as *M. avium complex* after generating a relative light unit (RLU) value greater than the pre-specified cut-off. No phenotypic identifications were performed.

Pneumocystis jirovecii

Respiratory specimens of induced sputum were transferred to a sterile container and sent out to Parkland's reference laboratory, ARUP (Associate Regional and University Pathologists; Salt Lake City, Utah), for *Pneumocystis* Direct Fluorescent Antibody Staining.

Coccidioides immitis/posadasii

Blood for fungal cultures were collected in Isolator tubes (Wampole Isolator 10™ Microbial Tubes, Cranbury, NJ, USA), and processed according to manufacturer recommendations under the biosafety cabinet. Blood and skin tissue culture specimens were inoculated onto potato dextrose agar (PDA), Brain-Heart infusion (BHI) agar with blood and Sabhi slants (all Remel™; Lenexa, Kansas, USA). The PDA and Sabhi slants were incubated at room temperature. The BHI with blood slant was incubated at 37°C with untightened cap to allow oxygenation. Non-sterile specimens (sputum and toenail) were inoculated onto Sabouraud-dextrose with chloramphenicol/gentamicin agar, Inhibitory Mould with gentamicin agar (IMA) and a BHI with blood/chloramphenicol agar plate (all Remel™; Lenexa, Kansas, USA). The former were incubated at room temperature in ambient air, the latter at 37°C. All culture plates were shrink-sealed.

The cultures were examined weekly for growth for six weeks. Upon noting colony growth of gray, moist colonies, a lacto-phenol cotton blue tape preparation was performed. If no conidia are seen and no mould identification is possible, a colony is sub-cultured from the primary slant onto a PDA agar plate and slide cultures are prepared. In the case of this patient, the identification of *Coccidioides* species was made based on microscopic and colony morphology. This was resulted as '*Coccidioides immitis/posadasii*' as no differentiation can be made between the two species on phenotypic basis alone.

Discussion

To our knowledge this is the first report of a triple coinfection

with *Coccidioides immitis/posadasii*, MAI, and *Pneumocystis jirovecii* pneumonia (PJP). The patient had clinical and radiographic evidence of all three pathogens. He had ground glass opacities, pneumothoraces, and a partial response to trimethoprim-sulfamethoxazole, which may represent features of *Pneumocystis* [2,3]. His clinical syndrome also met criteria for nontuberculous mycobacterium infection, including a nodular infiltrate, mediastinal adenopathy, and two positive sputum cultures for *Mycobacterium avium intracellulare* [4]. However, *Coccidioides* was the dominant and disseminated pathogen which most likely led to his demise.

With improvements in diagnosis, the frequency of polymicrobial infections in HIV patients is increasing. Previous cases reported in immunocompromised patients have noted dual infections of *Pneumocystis* with either fungi or mycobacterium, but not all three together. *Pneumocystis* has been seen as a frequent co-pathogen with other fungi including *Cryptococcus*, *Histoplasmosis* and *Aspergillus*, but not with *Coccidioides* as of this report [3,5-11].

Pneumocystis has also been reported as an agent of coinfection or colonization in patients with *Mycobacterium tuberculosis* [12], and also rarely with *Mycobacterium avium intracellulare* in one unusual case causing a coinfection of the choroid [13]. Given the near complete overlap in risk factors for PJP and MAI, coinfection is theoretically expected to be frequent. *Coccidioides* and *Mycobacterium tuberculosis* (MTB) share numerous risk factors and are frequently seen together, especially with HIV infection and imprisonment in endemic areas [14], however *Coccidioides* and MAI coinfections have not been reported.

MAI

Mycobacterium avium complex (MAC) is composed of two closely related species that are difficult to differentiate, *Mycobacterium avium*, and *Mycobacterium intracellulare*, denoted together as *Mycobacterium avium-intracellulare* (MAI). MAC is composed of several serovars and strains of variable pathogenicity in humans [15]. Differentiation is based on serovar-specific glycopeptidolipids (ssGPLs), which are thought to contribute to virulence [16]. *Mycobacterium avium* serovars 1, 2, 4 and 8 are responsible for 95% of AIDS-related infections. These mycobacteria are ubiquitous soil derived organisms distributed worldwide, and may impact up to 20-40% of HIV patients with a CD4 <50 in the absence of prophylaxis [17]. MAC tends to flourish in areas where *M. tuberculosis* has been controlled [18]. In AIDS, MAC presents as a disseminated infection, especially the lungs (cavities and nodules), gastrointestinal tract (GI), bone marrow, and lymph nodes [19-24]. Diagnosis of MAC is made by specimen culture in solid or liquid media as described above, followed by biochemical identification or molecular methods. Disseminated MAC is diagnosed by a positive culture from blood or bone marrow culture with the yield of each around 30% [25]. Isolation from blood or bone marrow requires the use of acid-fast bacilli-isolator blood-culture tubes with lysis-centrifugation and subsequent culture [18].

DNA probes for MAC targeting the mycobacterial ribosomal 16S RNA have become available for clinical use in the last decade and allow the identification of MAC from a positive culture in a few hours. Rapid culture methods (BACTEC[™] MGIT[™] and MB/bacT), in combination with DNA probes accelerates the diagnosis of mycobacterial disease (Accu Probe) [26]. PCR amplification directly from specimens may further accelerate diagnosis, but is not widely available [27]. Matrix-assisted Laser Desorption Ionization-Time of Flight Mass spectrometry (MALDI-TOF MS) is increasingly used for NTM identification from culture, but not from clinical isolates [28]. Treatment for proven disease includes clarithromycin or azithromycin in addition to ethambutol, continued for at least 12 months if macrolide sensitivity is confirmed. In cases of high bacterial burden, absence of HAART, or CD4<50, rifabutin is recommended as a third agent [17].

Coccidioides immitis and *posadasii* are the two species in the genus *Coccidioides* and are the causal agents of “Valley Fever”. They are dimorphic molds found in the soil in a narrow geographic range, including the desert regions of the American Southwest and a majority of Mexico. Infection occurs through inhalation of arthroconidia into the lungs followed by hematogenous dissemination to multiple organ systems. A majority of infections (60%) are asymptomatic. Others are self limited respiratory infections, but 5-10% result in chronic pulmonary sequelae including ongoing cough, sweats, weight loss, cavitation, and mass-like consolidation which can invade surrounding tissue planes. Rash is a common finding in extrapulmonary disease and can present in a wide variety of ways, including a papular rash in acute illness, verrucae, acne (as in our patient), ulcerated plaques, abscesses, and fistulae [29,30]. Complications in disseminated disease include miliary lung disease, meningitis, osteomyelitis, or multiorgan involvement [29,31,32]. HIV patients with a CD4 count <250/uL are at disproportionate high risk for dissemination, which occurs in 30-50% of cases. Genetic studies of patients with disseminated *Coccidioides* without known immune deficits have identified mutations in the IFN- γ and IL-12 receptors as predisposing factors confirming the importance of this axis in fungal control [31-35].

Timely diagnosis of *Coccidioides* requires a high suspicion and aggressive pursuit of specimens for tissue pathology and culture. While serologies are useful for immunocompetent persons, false negative rates are high in AIDS patients given a lack of robust humoral response [33]. Direct tests for fungal antigens including galactomannan can be useful early in infection during the endospore producing phase [33,34,35,36], but require the use of a reference lab, which can delay diagnosis for 5-7 days. The gold standard for diagnosis is histology demonstrating the pathognomonic spherules [36], which was obtained in our patient immediately upon appearance of the skin rash, with results taking 48-72 hours. PCR of clinical specimens is highly sensitive and specific in experimental studies and clinical studies, but has not been widely validated [37,38].

Recommended treatment of serious *Coccidioides* infections begins with amphotericin B (vertebral osteomyelitis, rapidly progressive pneumonia) or high dose fluconazole up to 2000 mg daily (meningitis) for several weeks until improvement is seen followed by oral fluconazole for at least one year or lifelong in the case of meningitis [36]. Surgical debridement may be required for local control of cavities and abscesses. HIV patients should remain on secondary fluconazole prophylaxis until the CD4 count rises >250 cells/ μ L.

Pneumocystis jirovecii, the agent of *Pneumocystis* pneumonia (PCP), has a convoluted microbiological history. Since originally classified as a form of *T. cruzi* by Carlos Chagas in 1909, it was thought to be a protozoan until reclassified as a fungus by rRNA sequence homology in 1989 [39]. Studies of epidemiology, transmission, and pathophysiology have been limited by the nonexistence of a viable culture technique. Serologic studies indicate that a majority of persons are exposed at a young age, while others suggest that person to person transmission and *de novo* infection play a role in at risk hosts [40]. Colonization is a frequent event in a wide range of hosts including persons on chronic steroid therapy (44%), and persons with HIV (40-69%) [40] PCP presents with subacute dry cough, dyspnea, and fever. Chest radiograph findings include bilateral reticular or nodular infiltrates extending out from the hilum, ground glass opacities, parenchymal cysts, or rarely focal consolidation [40]. PCP does not usually cause adenopathy or pleural effusions. Diagnosis currently involves direct visualization of the organism in BAL fluid, induced sputum, or lung tissue using a variety of techniques (methenamine silver, Giemsa, toluidine blue, Diff-Quick, or immunofluorescence). The sensitivity of these assays is highly variable

depending on organism load and lab experience, and may be as low as 50%, mandating the submission of multiple specimens or BAL for diagnosis.

BAL or lung biopsy is preferred, given the higher sensitivity of 90-100% in these specimens [17]. Similar to other infections, PCR has demonstrated high sensitivity and specificity in PCP, up to 98% and 96% respectively when using RT-PCR at the heat shock protein 70 gene in BAL fluid [40]. A PCR assay targeting the *cdc2* gene is also highly sensitive and specific and is available in reference laboratories [41].

Interactions of infections

The tendency of one infection to lead to another is an unfortunate observation that has fueled extensive immunological investigation. HIV patients commonly have polymicrobial pulmonary infections (7-14% in pneumonia, and up to 85% in cavitary disease) [42-44]. While the pathways of synergistic disease progression have been extensively studied for the most common HIV copathogens (MTB and Hepatitis C) less work has been done to uncover the interactions in polymicrobial respiratory infections.

A case is mounting for the immunomodulatory role of MAI as a gateway to other pulmonary infections. Cell mediated immunity, in particular the Th17 response, is central to the body's defense against MAI, PJP, and *Coccidioides* [40,45]. *In vitro* studies have demonstrated that MAI manipulates the immune response so as to upregulate IL-17 expression early in infection leading to chemotaxis of abundant immune effectors (MAI infection targets) and subsequently suppress the downstream immune response. The bacterium downregulates NFκB within 1 hour of infection and controls the host's ability to trigger phagolysosome fusion. MAI thus rescues itself from intracellular killing to persist within macrophages. MAI also triggers anti-inflammatory cytokines (IL-10 and TGF-β), which downregulate macrophage killing and may allow it to survive within fused phagolysosomes [16,45]. Moreover, MAI reduces macrophage responsiveness to IFN-γ and suppresses STAT-1 phosphorylation. These changes reduce macrophage TNF-α production, which is central to mycobacterial killing. Thus, patients with persistent MAI infections have incapacitated macrophages and a dampened IFNγ response, making them vulnerable to multiple other pulmonary pathogens normally cleared by this pathway.

Conclusion

In retrospect, each of the diagnoses eventually made in our patient were associated with significant delay which may have negatively impacted his outcome. The care of immunocompromised patients with polymicrobial infections would be greatly enhanced by the development of rapid multiplex assays, such as the one recently reported by Gago et al. [46] in April 2014 [16,46]. Rapid and complete microbiologic diagnosis could assist clinicians in the initiation of effective treatment and cessation of antibiotics with overlapping toxicities.

While Hickam's dictum ("patients can have as many disease as they damn well please") has been the ruling paradigm in HIV medicine for several decades: clinicians remain ill equipped to rapidly diagnose, prioritize, and treat numerous simultaneous pathogens. Hopefully in the future, rapid and accurate diagnostics will become available to assist in the rational and timely care of these patients.

Acknowledgement

The authors acknowledge Stacy Beal, MD for providing the microbiology slides for this case.

Conflict of Interest

None

Funding Sources

The University of Texas Southwestern Infectious Disease Division provided time for this research project.

References

- Sassaman MJV (1995) Mycobacterium tuberculosis: Assessing your laboratory. The association of state and territorial public health laboratory directors and US Department of health & human services. Atlanta, Georgia 30333.
- Kanne JP, Yandow DR, Meyer CA (2012) Pneumocystis jirovecii pneumonia: high-resolution CT findings in patients with and without HIV infection. *AJR Am J Roentgenol* 198: 555-561.
- Le Gal S, Damiani C, Virmaux M, Schmit JL, Totet A (2013) Photo quiz: A 39-year-old man with human immunodeficiency virus infection presenting with an alveolo-interstitial pulmonary syndrome. *J Clin Microbiol* 51: 2809.
- Griffith DE, Aksamit T, Brown-Elliott BA, Catanzaro A, Daley C, et al. (2007) An official ATS/IDSA statement: diagnosis, treatment, and prevention of nontuberculous mycobacterial diseases. *Am J Respir Crit Care Med* 175: 367-416.
- Baumann S, Reinwald M, Haghi D, Hofmann WK, Buchheidt D (2013) Coinfection of *Pneumocystis jirovecii* and invasive pulmonary aspergillosis in an immunocompromised patient: a diagnostic challenge. *Onkologie* 36: 582-584.
- González-González AE, Aliouat-Denis CM, Ramírez-Bárceñas JA, Demanche C, Pottier M, et al. (2014) *Histoplasma capsulatum* and *Pneumocystis* spp. co-infection in wild bats from Argentina, French Guyana, and Mexico. *BMC Microbiol* 14: 23.
- Kaira K, Shinomiya Y, Takahashi Y, Iida T, Yanagitani N, et al. (2007) Coinfection of invasive pulmonary aspergillosis and pneumocystis jirovecii pneumonia in a non-HIV patient. *Acta Med Okayama* 61: 235-238.
- Javier B, Susana L, Santiago G, Alcides T (2012) Pulmonary coinfection by *Pneumocystis jirovecii* and *Cryptococcus neoformans*. *Asian Pac J Trop Biomed* 2: 80-82.
- Mariñosa M, Soler A, Nogués X, Pedro-Botet J (2004) Pulmonary coinfection by *Pneumocystis carinii* and *Aspergillus fumigatus* in a seronegative arthritis patient treated with low-dose methotrexate. *Clin Rheumatol* 23: 555-556.
- Mihon C, Alexandre T, Pereira A (2013) Clinical experience in invasive fungal infections: multiple fungal infection as the first presentation of HIV. *Clin Drug Investig* 33: 37-40.
- Peña ZG, Byers HR, Lehmer LM, Smith CA, Ragsdale BD (2013) Mixed *Pneumocystis* and *Cryptococcus cutaneous* infection histologically mimicking xanthoma. *Am J Dermatopathol* 35: 6-10.
- Yamao S, Jint T, Nishimura N, Fujiwara M, Suzuki K (2011) [Coinfection with *Pneumocystis jirovecii* and *Mycobacterium tuberculosis* in a patient with AIDS: a first report in Japan]. *Nihon Kokyuki Gakkai Zasshi*. 49: 192-196.
- Whitcup SM, Fenton RM, Pluda JM, De Smet MD, Nussenblatt RB (1992) *Pneumocystis carinii* and *Mycobacterium avium-intracellulare* infection of the choroid. *Retina* 12: 331-335.
- Cadena J, Hartzler A, Hsue G, Longfield RN (2009) *Coccidioidomycosis* and tuberculosis coinfection at a tuberculosis hospital: clinical features and literature review. *Medicine (Baltimore)* 88: 66-76.
- Chatterjee D, Khoo KH (2001) The surface glycopeptidolipids of mycobacteria: structures and biological properties. *Cell Mol Life Sci* 58: 2018-2042.
- Rocco JM, Irani VR (2011) *Mycobacterium avium* and modulation of the host macrophage immune mechanisms. *Int J Tuberc Lung Dis* 15: 447-452.

17. Kaplan JE, Benson C, Holmes KK, Brooks JT, Pau A, et al. (2014) Guidelines for Prevention and Treatment of Opportunistic Infections in HIV-Infected Adults and Adolescents. Panel on Opportunistic Infections in HIV-Infected Adults and Adolescents. Guidelines for the prevention and treatment of opportunistic infections in HIV-infected adults and adolescents: recommendations from the Centers for Disease Control and Prevention, the National Institutes of Health, and the HIV Medicine Association of the Infectious Diseases Society of America. *MMWR Recomm Rep* 58: 1-207.
18. Corti M, Palmero D (2008) Mycobacterium avium complex infection in HIV/AIDS patients. *Expert Rev Anti Infect Ther* 6: 351-363.
19. Benson CA (1994a) Disease due to the Mycobacterium avium complex in patients with AIDS: epidemiology and clinical syndrome. *Clin Infect Dis* 18: 218-222.
20. Benson CA (1994b) Treatment of disseminated disease due to the Mycobacterium avium complex in patients with AIDS. *Clin Infect Dis* 18: 237-242.
21. Benson CA, Ellner JJ (1993) Mycobacterium avium complex infection and AIDS: advances in theory and practice. *Clin Infect Dis* 17: 7-20.
22. Gordin FM, Cohn DL, Sullam PM, Schoenfelder JR, Wynne BA, et al. (1997) Early manifestations of disseminated Mycobacterium avium complex disease: a prospective evaluation. *J Infect Dis* 176: 126-132.
23. Havlik JA Jr, Horsburgh CR Jr, Metchock B, Williams PP, Fann SA (1992) Disseminated Mycobacterium avium complex infection: clinical identification and epidemiologic trends. *J Infect Dis* 165: 577-580.
24. Kemper CA, Havlir D, Bartok AE, Kane C, Camp B (1994) Transient bacteremia due to Mycobacterium avium complex in patients with AIDS. *J Infect Dis* 170: 488-493.
25. Kilby JM, Marques MB, Jaye DL, Tabereaux PB, Reddy VB, et al. (1998) The yield of bone marrow biopsy and culture compared with blood culture in the evaluation of HIV-infected patients for mycobacterial and fungal infections. *Am J Med* 104: 123-128.
26. Soini H, Pan X, Teeter L, Musser JM, Graviss EA (2001) Transmission dynamics and molecular characterization of Mycobacterium tuberculosis isolates with low copy numbers of IS6110. *J Clin Microbiol* 39: 217-221.
27. Gürtler V, Harford C, Bywater J, Mayall BC (2006) Direct identification of slowly growing Mycobacterium species by analysis of the intergenic 16S-23S rDNA spacer region (ISR) using a GelCompar II database containing sequence based optimization for restriction fragment site polymorphisms (RFLPs) for 12 enzymes. *J Microbiol Methods* 64: 185-199.
28. Saleeb PG, Drake SK, Murray PR, Zelazny AM (2011) Identification of mycobacteria in solid-culture media by matrix-assisted laser desorption ionization-time of flight mass spectrometry. *J Clin Microbiol* 49: 1790-1794.
29. Welsh O, Vera-Cabrera L, Rendon A, Gonzalez G, Bonifaz A (2012) Coccidioidomycosis. *Clin Dermatol* 30: 573-591.
30. Kerrick SS, Lundergan LL, Galgiani JN (1985) Coccidioidomycosis at a university health service. *Am Rev Respir Dis* 131: 100-102.
31. Nguyen C, Barker BM, Hoover S, Nix DE, Ampel NM, et al. (2013) Recent advances in our understanding of the environmental, epidemiological, immunological, and clinical dimensions of coccidioidomycosis. *Clin Microbiol Rev* 26: 505-525.
32. Rempe S, Sachdev MS, Bhakta R, Pineda-Roman M, Vaz A, et al. (2007) Coccidioides immitis fungemia: clinical features and survival in 33 adult patients. *Heart Lung* 36: 64-71.
33. Ampel NM (2005) Coccidioidomycosis in persons infected with HIV type 1. *Clin Infect Dis* 41: 1174-1178.
34. Durkin M, Connolly P, Kuberski T, Myers R, Kubak BM, et al. (2008) Diagnosis of coccidioidomycosis with use of the Coccidioides antigen enzyme immunoassay. *Clin Infect Dis* 47: e69-73.
35. Galgiani JN, Dugger KO, Ito JI, Wieden MA (1984) Antigenemia in primary coccidioidomycosis. *Am J Trop Med Hyg* 33: 645-649.
36. Galgiani JN, Ampel NM, Blair JE, Catanzaro A, Johnson RH, et al. (2005). Coccidioidomycosis. *Clin Infect Dis* 41: 1217-1223.
37. Binnicker MJ, Buckwalter SP, Eisberner JJ, Stewart RA, McCullough AE, et al. (2007) Detection of Coccidioides species in clinical specimens by real-time PCR. *J Clin Microbiol* 45: 173-178.
38. Johnson SM, Simmons KA, Pappagianis D (2004) Amplification of coccidioid DNA in clinical specimens by PCR. *J Clin Microbiol* 42: 1982-1985.
39. Stringer SL, Stringer JR, Blase MA, Walzer PD, Cushion MT (1989) Pneumocystis carinii: sequence from ribosomal RNA implies a close relationship with fungi. *Exp Parasitol* 68: 450-461.
40. Morris A, Norris KA (2012) Colonization by Pneumocystis jirovecii and its role in disease. *Clin Microbiol Rev* 25: 297-317.
41. Arcenas RC, Uhl JR, Buckwalter SP, Limper AH, Crino D (2006) A real-time polymerase chain reaction assay for detection of Pneumocystis from bronchoalveolar lavage fluid. *Diagn Microbiol Infect Dis* 54: 169-175.
42. Aviram G, Fishman JE, Sagar M (2001) Cavitary lung disease in AIDS: etiologies and correlation with immune status. *AIDS Patient Care STDS* 15: 353-361.
43. Benito N, Moreno A, Miro JM, Torres A (2012) Pulmonary infections in HIV-infected patients: an update in the 21st century. *Eur Respir J* 39: 730-745.
44. Benito N, Rañó A, Moreno A, González J, Luna M, et al. (2001) Pulmonary infiltrates in HIV-infected patients in the highly active antiretroviral therapy era in Spain. *J Acquir Immune Defic Syndr* 27: 35-43.
45. Vázquez N, Rekka S, Gliozzi M, Feng CG, Amarnath S, et al. (2012) Modulation of innate host factors by Mycobacterium avium complex in human macrophages includes interleukin 17. *J Infect Dis* 206: 1206-1217.
46. Gago S, Buitrago MJ, Clemons KV, Cuenca-Estrella M, Mirels LF, et al. (2014) Development and validation of a quantitative real-time PCR assay for the early diagnosis of coccidioidomycosis. *Diagn Microbiol Infect Dis* 79: 214-221.