

# Autoimmune and Infectious Diseases: Open Access

Case Report

Volume: 2.1

Open Access

## Immune Reconstitution Inflammatory Syndrome in a Child with Disseminated Tuberculosis

Ba ID\*, Thiongane A, Ba A, Faye PM, Sow A, Deme Ly I and Ba M

Pediatric Pulmonology, Albert Royer Children's Hospital, University Cheikh Anta Diop of Dakar, Senegal

\*Corresponding author: Idrissa Demba BA, Pediatric Pulmonology, Albert Royer Children's Hospital, University Cheikh Anta Diop of Dakar, BP 16109 Dakar-Fann, Senegal, Tel: (+221) 777647125; E-mail: [docteuridy@hotmail.com](mailto:docteuridy@hotmail.com)

Received date: 09 Sep 2015; Accepted date: 05 Dec 2015; Published date: 13 Dec 2015.

Citation: Ba ID, Thiongane A, Ba A, Faye PM, Sow A, et al. (2015) Immune Reconstitution Inflammatory Syndrome in a Child with Disseminated Tuberculosis. *Autoimmun Infect Dis* 2(1):doi <http://dx.doi.org/10.16966/2470-1025.110>

Copyright: © 2015 Ba ID, et al. This is an open-access article distributed under the terms of the Creative Commons Attribution License, which permits unrestricted use, distribution, and reproduction in any medium, provided the original author and source are credited.

### Abstract

IRIS is a paradoxical reaction occurring in HIV-infected patient after initiation of highly active antiretroviral therapy (HAART). Incidence is estimated 12 to 19% of child starting HAART. IRIS with tuberculosis in non-HIV patients has not been reported in the literature. We report the case of an HIV negative 8 years-old girl who did develop IRIS and dilated cardiomyopathy during her treatment for severe disseminated TB (lungs, mediastinal lymph nodes, spleen, liver and kidneys). An appropriate antibiotic treatment was begun against the multiple sensitive mycobacterium tuberculosis strain retrieved: RHZE for 2 months followed by RH 10 months. The child appeared stable the 2 first weeks on treatment but not afebrile. She remained in the hospital for 6 months and experienced daily recurrent fever 39-40°C with rigors, diffuse bone pains, elevated transaminases and deterioration of chest infiltrates. Sequential abdominal CT and Gallium scans demonstrated a progressive involvement of liver, spleen, kidneys, medullar bones and abdomen lymph nodes for 2 weeks to 5 months. Then she gradually improved. Her complete immunological work-up at that point was considered normal.

We concluded from an extensive review of the literature that this case highlights a paradoxical immune mediated reaction to *Mycobacterium tuberculosis* during an appropriate anti-TB treatment. IRIS results in clinical deterioration but is not a failure to treatment. Early recognition of IRIS could prevent unnecessary changes in anti-TB regimen.

**Keywords:** Immune Reconstitution Syndrome (IRIS); Tuberculosis (TB); HIV; Highly Active Antiretroviral Therapy (HAART)

### Introduction

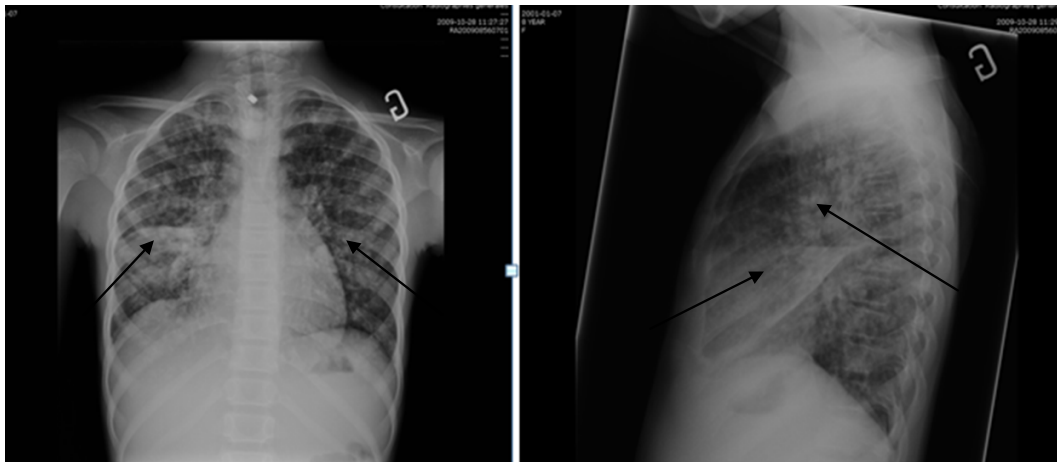
Immune reconstitution inflammatory syndrome (IRIS) is a paradoxical reaction initially described in HIV-infected patient after the initiation of an antiretroviral therapy (ART). IRIS is mostly seen in HIV-infected patients [1]. The incidence is estimated between 12 to 19% in children starting ART [2-4]. TB associated IRIS is characterized by a clinical worsening after the start of ART in patients receiving Tb treatment. It can also be diagnosed as a new presentation of TB that is «unmasked» in the weeks following the initiation of ART and the exclusion of other causes that could explain a deterioration (such as antimicrobial drug resistance, drug hypersensitivity reaction, or another opportunistic infection) [5]. IRIS in association with tuberculosis in non-HIV patients has not been reported in the literature. We reported the case of IRIS in child-disseminated tuberculosis.

### Case Report

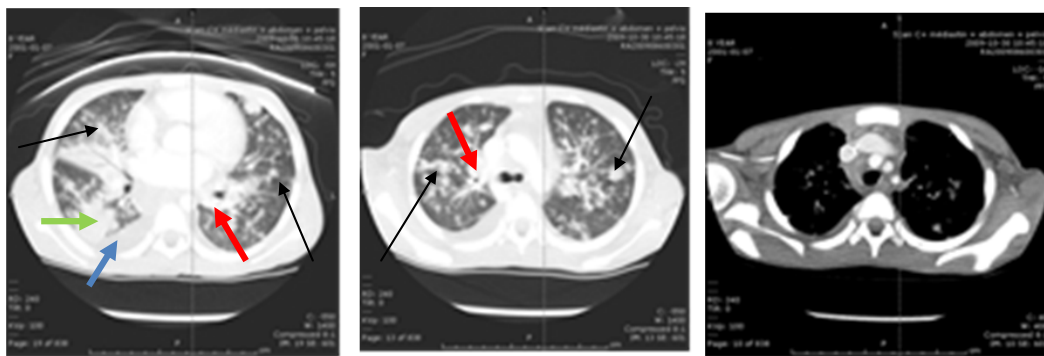
An 8-year-old girl was referred to our hospital for fever and abnormal CXR, no medical investigation upon her arrival in Canada 3 years ago, unknown immunization status and no pets. Medical history noticed right thigh pain, weight loss over 2 months with sleepiness, fatigue and lack of energy. She coughed for 3 weeks presenting dyspnea on exertion. She suffered neither from any sputum, hemoptysis, and thoracic pain nor wheezed any gastrointestinal symptoms. When arrived, the temperature was 39.1 degree centigrade, the weight below 3<sup>rd</sup> percentile and the height on the 10<sup>th</sup> percentile. Normal blood pressure and SpO<sub>2</sub> 98% on air room. On examination, she was cachectic, pale conjunctivae, no clubbing and peripheral oedema. The respiratory system exam found normal thorax, tachypnea (respiratory rate = 28/min), no in drawing, no grunting or stridor diffusing crackles lung bases (right > left). Cardio-vascular

system objected tachycardia (heart rate=172/min) and well perfused. Her abdomen was soft without any hepato-splenomegaly. She hadn't any lymphadenopathy and neurological signs. The hemogram showed hypochromic microcytic anemia (Hb= 59 g/L), leukocyte count of 5430/μl with polymorphonuclear predominance and platelet count normal. Serum electrolytes and creatinine were normal. C-reactive protein (CRP) was 60 mg/l; Liver transaminases were mildly elevated (ALT: 42 and AST: 78 IU/L, respectively); normal capillary gas. Mantoux test was non-reactive. The chest radiograph showed small foci of alveolar consolidation distributed in lungs predominant in middle lobe, no pleural effusion or cavitation (Figure 1), right femur and pelvic x ray normal. The chest computed tomographic (CT) (Figure 2) showed diffuse bilateral nodular lesions in the lung parenchyma, predominant in middle lobe associated with multiple mediastinum lymphadenomegaly, right lower lobe atelectasis, slight right and left pleural effusion. Abdomen and pelvis CT scan findings were heterogeneous spleen with multiple hypodensities, homogenous liver and pancreas, Homogenous kidneys, Ascites in mild to moderate. She still complained both persistent right thigh pain and diffuse bone one. So Technitium and Gallium bone scan (Figure 3) performed showed mild diffuse enhancement of long bones, pelvis, skull and increasing activity in lungs, kidneys, liver, evidence medullar expansion. Gastric aspirate and sputum induction were positive for acid fast bacilli (AFB). PCR for *Mycoplasma pneumonia* and *Chlamydia* one were negative, blood culture isolator, Viral IF, *Legionella* antigen were also negative (urine). Eye exam was normal.

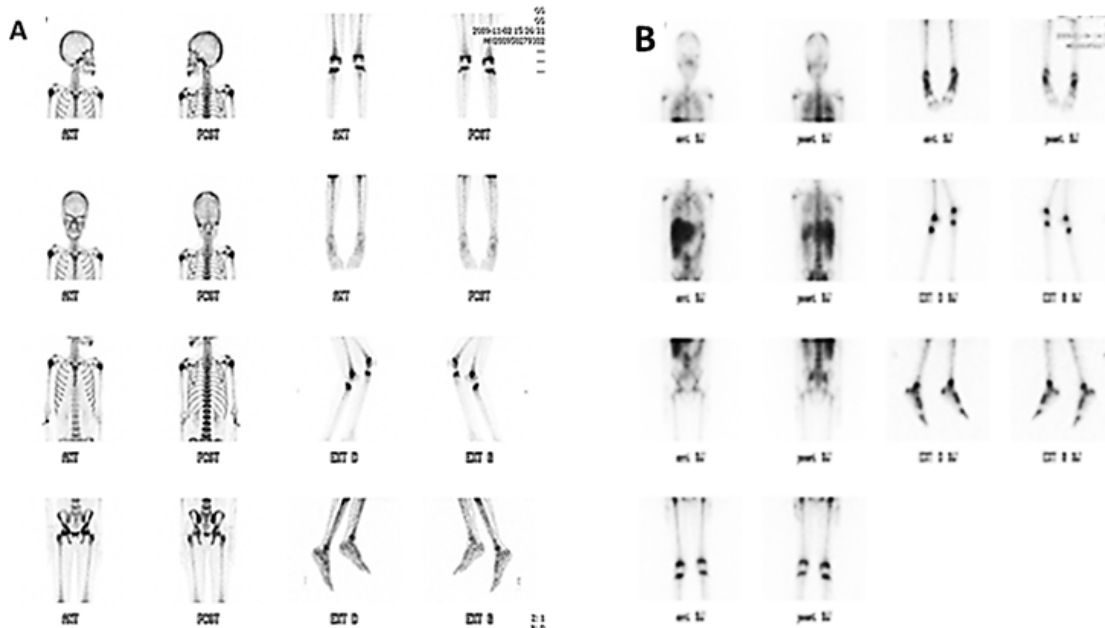
So, our diagnosis was disseminated TB (Pulmonary, lymph nodes, liver, spleen, kidney localizations) with possible bone marrow involvement. Co morbidities were severe malnutrition (BMI=14 kg/cm<sup>2</sup>) and severe



**Figure 1 :** Initial chest x Ray of the of an HIV negative 8 years-old girl who did develop immune reconstitution inflammatory syndrome during her treatment for disseminated Tb, showed small bilateral foci of alveolar consolidation distributed in both lungs (black arrows), no pleural effusion and no cavitation.



**Figure 2 :** CT scan of our 8-old-year patient showed diffuse bilateral nodular lesions in both lungs parenchyma (black arrows), associated with multiple mediastinum lymphadenomegaly (blue arrows), right lower lobe atelectasis (green arrow), slight right pleural effusion (maroon arrows).



**Figure 3 :** Technicium bone scan (A) and Gallium bone scan (B) of an HIV negative 8 years-old girl who did develop immune reconstitution inflammatory syndrome during her treatment for disseminated Tb, showed mild diffuse enhancement of bones and increasing activities in both lungs, kidneys, liver, evidence of medullar expansion.

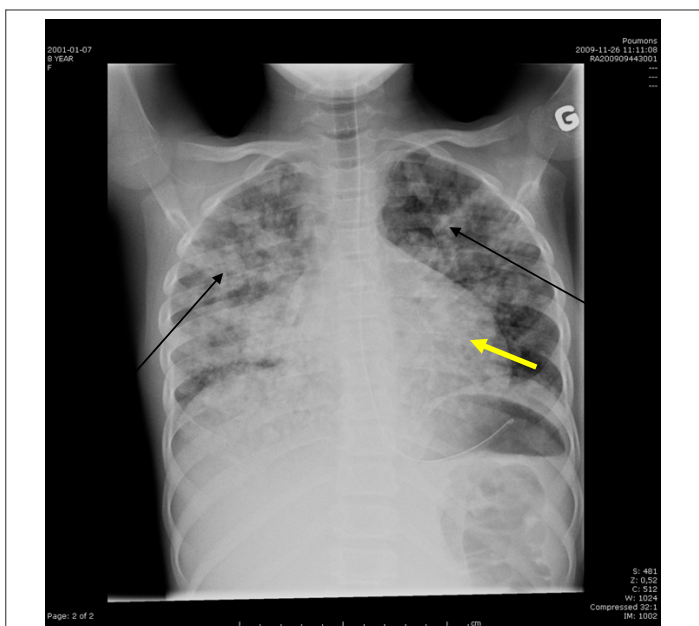
anemia. HIV serologies were negative twice. An anti-TB treatment was initiated (RHZE 2 months; RH 10 months), adjuvant therapy (oral Pyridoxine) and nocturnal gavage (a total of 74 days), psychosocial and multidisciplinary follow-up. She appeared stable the first week on anti-TB treatment, but not afebrile (38°-39°C), tachycardia, dyspnea at rest, gallop was noticed. Echo-cardiography showed left ventricular dilatation with diffuse ventricular hypokinesia and severe diastolic dysfunction; EKG found signs of left ventricular dilatation. We conclude associated dilated myocardioathy probably multifactorial etiologies (tuberculosis, anemia and severe malnutrition). She benefited digoxin, diuretics, captopril, Steroids (Prednisone (1 mg/Kg/jour) and blood transfusion. Despite the start of the anti-TB treatment, she continued to have persistent fever (peak fever 40°C), both diffuse bone pains persisted and liver transaminases increased. Chest x ray (day 28 anti-TB) (Figure 4) showed no improvement, and with increasing infiltration. Abdominal ultrasound (repeated) Liver enlarged (9.2 cm) and scattered by multiple nodules, Spleen stuffed micronodules, innumerable abdominal lymph nodes and Kidney lesions. Differential diagnosis on day was: multiple resistant TB, neoplasia (lymphoma), related anti-TB drug (drug toxicity), connective tissue diseases or other immune diseases. Performed bronchoscopy and bronchoalveolar lavage (BAL) found enlarged carina with a 20% reduction in calibrum of the main right bronchus and inflammatory mucosae; Culture isolated *Hemophilus*, *klebsiella*, *Streptococcal* species in BAL specimen and no *Mycobacterium*, *Legionella* or *Pneumocystis*. We did further investigations including immunology and hematology assessment (both normal exhaustive immunologic work-up and normal bone marrow biopsy) and comprehensive assessment: infectious work-up (viral, parasites and fungi) negative, spleen biopsy (auramine negative), liver biopsy x 2 (auramine doubtful) and normal lumbar function. At the end of the first month of the anti-TB treatment, we decided to modify the anti-TB regimen by introducing second-line anti-TB drugs (IV Amikacin, Levaquin and Ethionamide, and Ethambutol discontinued). And steroid doses (Prednisone) increased up to 2 mg/Kg/day. Finally we got a strain susceptibility and the strain *Mycobacterium tuberculosis* was very sensitive to R, I, Z, and E and the treatment was continued by RH for 10 months.

Our final diagnosis was immune reconstitution inflammatory syndrome (IRIS) in a negative HIV-patient. It took many weeks before IRIS manifestations decreased despite a good gain weight, resolution of CX ray abnormalities and recovery of cardiac function. She was discharged after five months of hospitalization. Chest X ray on 6 month-anti-TB (Figure 5).

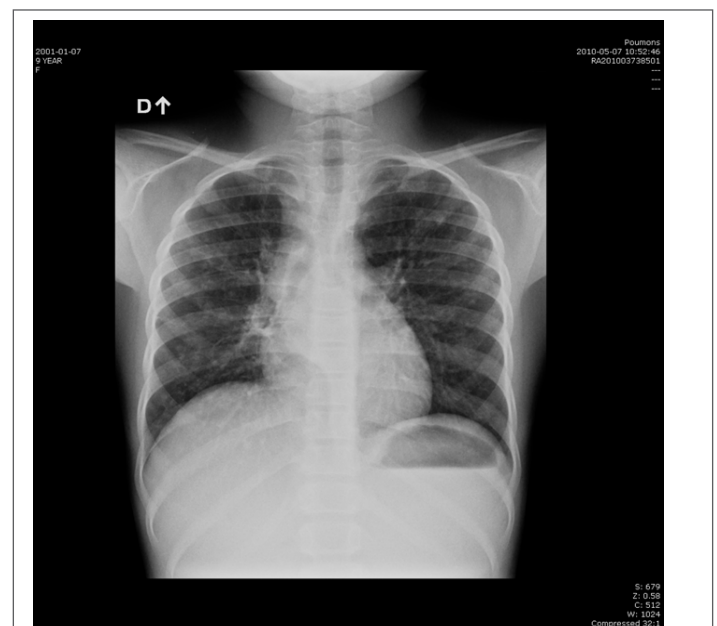## Discussion

IRIS is a phenomenon observed in patients recovering from immunodeficiency. Generally, two clinical scenarios commonly occurred: an unmasking IRIS underlying unrecognized infection flares after starting ART; and paradoxical IRIS, resulting as the exacerbation of an often past known treated infection [5]. Pathogenesis of IRIS involves a combination of underlying antigenic burden, the degree of immune restoration following HAART, and host genetic susceptibility. These pathogenic mechanisms may interact and likely depend on the underlying burden of infectious or noninfectious agent [5-7].

In children, IRIS incidence is estimated between 12 and 19% of all children who initiate antiretroviral therapy [2-4] with a higher incidence in patients who have been diagnosed with an active opportunistic infection at the time of ART initiation [8,9]. Most data concerning IRIS originated from limited resources settings. Risk factors for the development of IRIS include a high baseline HIV viral load before the initiation of ART, rapid decline in HIV viral load after initiation of ART, a lower baseline CD4 count before ART initiation, a high antigenic burden and disseminated opportunistic infection, initiation of ART concomitant with or soon after the initiation of the treatment of an acute infection, and lack of exposure to ART before initiating the current regimen [7]. IRIS causes in HIV-infected patients include infectious etiologies and non infectious causes [6]. Recent report also documented IRIS due to *Mycobacterium bovis* BCG in HIV-infected children in whom ART was initiated [10,11]. TB associated IRIS is characterized by a clinical worsening after the start of ART in patients receiving Tb treatment. It can also be diagnosed as a new presentation of TB that is «unmasked» in the weeks following



**Figure 4 :** Chest x ray (28 days on anti-Tb treatment) an HIV negative 8 years-old girl who did develop immune reconstitution inflammatory syndrome during her treatment for disseminated Tb, showed no improvement with bilateral diffuse lungs infiltrations (black arrows) and cardiomegaly (yellow arrow).



**Figure 5 :** Chest X ray (6 months on anti-TB) an HIV negative 8 years-old girl who did develop immune reconstitution inflammatory syndrome during her treatment for disseminated Tb, showed improvement with disappearance of radiological infiltrates.

the initiation of ART and the exclusion of other causes that could explain deterioration [5].

TB is among the most frequent reported pathogen associated with IRIS. TB-IRIS can have a variety of clinical manifestations: fever, pulmonary disease, disseminated TB, systemic reaction inflammatory syndromes, acute renal failure [12]. Transient worsening of patient has been reported after the initiation of ART in severely immune compromised patients [13,14] and paradoxical CNS TB reactions are well described in both children and adult HIV-negative patients [15,16]. No treatment has been prospectively studied in IRIS patients. Non-steroidal anti inflammatory drugs (NSAIDS) or corticosteroids are commonly used to decrease inflammation in patients with severe IRIS [7,17].

Indeed, IRIS is not previously described in literature in negative HIV patients. We think that severe malnutrition is the main clinical risk causing immune impairment by developing IRIS in negative HIV patients. The mechanism is similar unlike in positive HIV by the restoration of the immune system. Genetic host susceptibility may certainly play a role in the development of this syndrome.

We concluded from an extensive review of the literature that this case highlights a paradoxical immune mediated reaction similar to the previously described IRIS in infected HIV patients but this time to *Mycobacterium tuberculosis* during an appropriate antibiotic treatment. Such an IRIS resulted in an apparent clinical deterioration but turned out not being a failure to treatment. In the future, early recognition of an IRIS in tuberculosis might prevent unnecessary changes in anti-TB regimen.

### Acknowledgments

We thank the Ste-Justine University Hospital Center, particularly the Pediatric Pulmonology staff and Infectious diseases staff, Dr. Guy Lapiere, Dr. Jacques-Edouard Marcotte, Dr. Denis Bérubé, Dr. Chantal Buteau, Dr. Sheila Jacob and Professor Mamadou Ba (Albert Royer National Hospital Children's Center, Dakar (Senegal), my mentor for all support during our Pediatric training at Dakar and fellowship at Montreal.

**Conflict of Interest:** None

### References

- Shelburne SA, Hamill RJ, Rodríguez-Barradas MC, Greenberg SB, Atmar RL, et al. (2002) Immune reconstitution inflammatory syndrome: emergence of a unique syndrome during highly active antiretroviral therapy. *Medicine (Baltimore)* 81: 213-227.
- Smith K, Kuhn L, Coovadia A, Meyers T, Hu C, et al. (2009) Immune reconstitution inflammatory syndrome among HIV-infected South Africans initiating antiretroviral therapy. *AIDS* 23: 1097-1107
- Thanyawee P, Peninnah O, Nuthapong U, Noppadon A, Suchart P, et al. (2006) Immune reconstitution syndrome from nontuberculous mycobacterial infection after initiation of antiretroviral therapy in children with HIV infection. *Pediatr Infect Dis J* 25(7): 645-648.
- Wang M E., Castillo ME, Montano S M, Zunt J R (2009) Immune Reconstitution Inflammatory Syndrome in Human Immunodeficiency Virus-Infected Children in Peru. *Pediatr Infect Dis J* 28(10): 900-903.
- French MA (2009) HIV/AIDS: immune reconstitution inflammatory syndrome : a reappraisal. *Clin Infect Dis* 48(1): 101-7.
- Murdoch M D, Venter DW, Van Rie A a, Feldman C (2007) Immune reconstitution inflammatory syndrome (IRIS). Review of common infectious manifestations and treatment options. *AIDS Research and Therapy* 4: 9.
- Beatty GW (2010) Immune reconstitution inflammatory syndrome. *Emerg Med Clin N Am* 28: (2): 393-407.
- Ratnam I, Chiu C, Kandala NB, Easterbrook PJ (2006) Incidence and risk factors for immune reconstitution inflammatory syndrome in an ethnically diverse HIV type 1-infected cohort. *Clin Infect Dis* 42(3): 418-27.
- Shelburne SA, Montes M, Hamill RJ (2006) Immune reconstitution inflammatory syndrome: more answers, more questions. *J Antimicrob Chemother* 57(2): 167-70.
- Hesseling AC, Rabie H, Marais BJ, M. Manders, M. Lips et al. ( 2006) Bacille Calmette-Gue'rin (BCG) vaccine-induced complications and HIV-infected and HIV- uninfected in children. *Clin Infect Dis* 42: 548-58.
- Hesseling AC, Schaaf HS, Hanekom WD, N. Beyers, M. F. Cotton, et al. ( 2003) Danish bacille Calmette-Gue'rin vaccine-induced disease in human immunodeficiency virus-infected children. *Clin Infect Dis* 37: 1226-33.
- Lawn SD, Bekker LG, Miller RF (2005) Immune reconstitution disease associated with mycobacterial infections in HIV-infected individuals receiving antiretrovirals. *Lancet Infect Dis* 5(6): 361-373.
- Kiwanuka J, Graham SM, Coulter JB, Gondwe JS, Chilewani N, et al. (2001) Diagnosis of pulmonary tuberculosis in children in an HIV-endemic area, Malawi. *Ann Trop Paediatr* 21: 5-14.
- Breton G, Duval X, Estellat C, Poaletti X, Bonnet D, et al. (2004) Determinants of immune re- constitution inflammatory syndrome in HIV type 1-infected patients with tuberculosis after initiation of antiretroviral therapy. *Clin Infect Dis* 39: 1709-12.
- Hejazi N, Hassler W (1997) Multiple intracranial tuberculomas with atypical response to tuberculostatic chemotherapy: literature review and a case report. *Acta Neurochir (Wien)* 139(3): 194-202.
- Teoh R, Humphries MJ, O'Mahony G (1987) Symptomatic intracranial tuberculoma developing during treatment for tuberculosis: A report of ten cases and review of the literature. *Q J Med* 63: 449-460
- Marais BJ, Graham SM, Cotton MF, Beyers M (2007) Diagnostic and management challenges for childhood tuberculosis in the era of HIV. *J Infect Dis* 196 (Suppl 1): S76-85.