

Autoimmune and Infectious Diseases: Open Access

Case Report

Volume: 1.2

Open Access

Toxocariasis: A Rare Cause of Multiple Liver Nodules

Bellakhal S*, Mestri A, Jomni T, Gharbi E, Smida H, and Duggui MH

Internal Medicine Department, Internal Forces Security Hospital-La Marsa, Tunisia
Faculty of medicine of Tunis, University of Tunis-El Manar, Tunisia

*Corresponding author: Syrine Bellakhal, Internal Medicine Department, Internal Forces Security Hospital- Tahar Ben Achour Street 2078-La Marsa-Tunisia, E-mail: syrinebellakhal@yahoo.fr

Received date: 14 October 2015; Accepted date: 12 Nov 2015; Published date: 17 Nov 2015.

Citation: Bellakhal S, Mestri A, Jomni T, Gharbi E, Smida H, et al. (2015) Toxocariasis: A Rare Cause of Multiple Liver Nodules. *Autoimmun Infect Dis* 1(2) : doi <http://dx.doi.org/10.16966/2470-1025.107>

Copyright: © 2015 Bellakhal S, et al. This is an open-access article distributed under the terms of the Creative Commons Attribution License, which permits unrestricted use, distribution, and reproduction in any medium, provided the original author and source are credited.

Summary

Visceral larva migrans syndrome is a clinical manifestation of systemic organ involvement by toxocara species. Liver involvement is a rare finding in visceral larva migrans syndrome. We present a case of 42-year-old female with multiple nodular lesions of the liver mimicking malignant lesions. The final diagnosis was visceral larva migrans syndrome.

Keywords: Liver nodules; Toxocarisis; Geophagia

Case

A 42-year old Tunisian female was referred to our internal medicine department for abdominal pain and multiple nodular lesions of the liver on ultrasound abdominal examination.

On examination she was afebrile and not icteric, her BMI was 25 kg/m² and she had tenderness in the right upper quadrant of abdomen with no rebound or defense.

Liver function test were within the normal ranges, circulating levels of various tumors markers were under normal levels and peripheral eosinophilia count was 25000/mm³.

Computed tomography (CT) of the abdomen as shown in figure 1, showed small multiple low density areas located mainly in the periportal region. Chest CT scan revealed diffuse micro nodular opacities.

Past history of the patient was significant for PICA eating and especially for geophagia.

Specific serology of toxocariasis was positive and the patient was treated with Albendazole 400 mg a day during 15 days. Eosinophilia rate was 1600 /mm³ after one month of treatment and abdominal CT performed 6 months later showed complete disappearance of liver nodules (Figure 2).

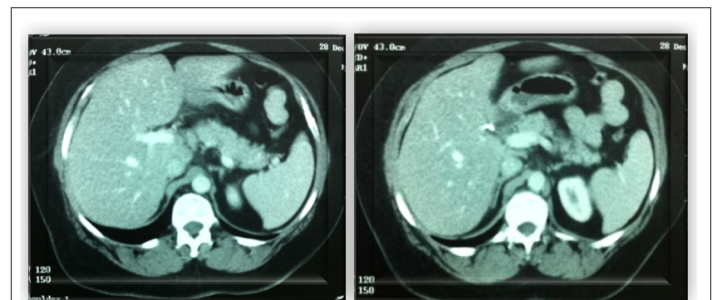


Figure 2: Follow-up computed tomography scan showing disappearance of hepatic lesions after six months of treatment.

Comments:

Toxocariasis of the liver presented as multiple liver lesions can often be mistaken for other conditions [1] Differential diagnoses include liver metastasis, hepato cellular carcinoma and granulomatosis of the liver [2]. In our case, peripheral eosinophilia, lung involvement and history of geophagia helped us to suspect the diagnosis of toxocariasis. In atypical presentations, liver needle biopsy and histological examination could be necessary [3].

References

1. Leone N, Baronio M, Todros L, David E, Brunello F, et al. (2006) Hepatic involvement in larva migrans of Toxocaracanis: report of a case with pathological and radiological findings. *Dig Liver Dis* 38: 511-514.
2. Lim JH (2008) Toxocariasis of the liver: visceral larva migrans. *Abdom Imaging* 33: 151-156.
3. Azuma K, Yashiro N, Kinoshita T, Yoshigi J, Ihara N (2002) Hepatic involvement of visceral larva migrans due to Toxocaracanis: a case report-CT and MR findings. *Radiat Med* 20: 89-92.

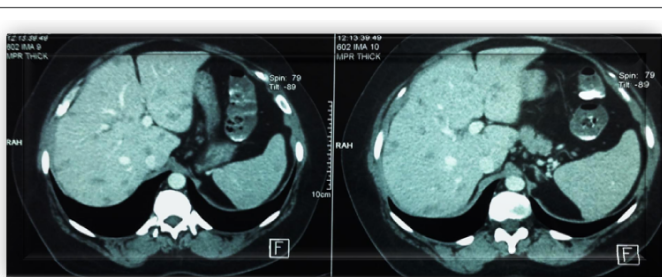


Figure 1: Abdominal computed tomography scan showing diffuse hepatic hypodense lesions.