

Surgical Manipulation of Dorsal Thoracolumbar Massive Presumed Teratoma in a Buffalo-Calf: Clinical Findings and Differential Considerations

Ahmed Ibrahim* and Magda M Ali

Department of Surgery, Anesthesiology, and Radiology, Veterinary Teaching Hospital, Faculty of Veterinary Medicine, Assiut University, Assiut, Egypt

*Corresponding author: Ahmed Ibrahim, Department of Surgery, Anesthesiology, and Radiology, Veterinary Teaching Hospital, Faculty of Veterinary Medicine, Assiut University, Assiut, Egypt, Fax: 088-208050; Tel: +201062204009; E-mail: elgrah38@gmail.com

Received: 07 May, 2018 | Accepted: 08 Jun, 2018 | Published: 15 Jun, 2018

Citation: Ibrahim A, Ali MM (2018) Surgical Manipulation of Dorsal Thoracolumbar Massive Presumed Teratoma in a Buffalo-Calf: Clinical Findings and Differential Considerations. *J Anim Sci Res* 2(2): dx.doi.org/10.16966/2576-6457.116

Copyright: © 2018 Ibrahim A, et al. This is an open-access article distributed under the terms of the Creative Commons Attribution License, which permits unrestricted use, distribution, and reproduction in any medium, provided the original author and source are credited.

Abstract

The present case described the clinical findings of a dorsal thoracolumbar presumed teratoma in a newly born calf and how you can differentiate it from other similar lesions that may be confused with it, especially the meningocele. The surgical approach for such cases, as well as precautions should be taken into consideration was described, also. The current congenital neoplasm has not reported in buffalo calves before.

Keywords: Congenital; Teratoma; Dorsal; Thoracolumbar; Surgical excision; Calf

Introduction

Congenital tumors are characterized by their occurrence early in life, in feti and newborns until 2 months of age. This type of tumors is rare in calves [1]. Teratomas are true neoplasms made up of a number of different tissues being not native to the area in which they occur. These tissues derived from more than one of the embryonic germ layers. So, teratomas can be distinguished from mixed tumors (like those of the salivary glands), embryomas and similar tumors (such as nephroblastomas and hepatoblastomas), and hamartomas (which are composed of a mixture of elements normally found in the site [2,3].

Congenital tumors have been recorded in different species of animals including water buffalo [4], cattle [1,5,6], horses [7], dog [8], and pig [9]. The initial treatment for all teratomas is surgical excision, regardless of the size of the tumor [3,10].

To the best of our knowledge, such massive dorsal thoracolumbar presumed teratoma has not been recorded in buffalo-calves before. The aim of the present case study was to provide the veterinarians by the clinical findings of the dorsal thoracolumbar presumed teratoma

and the differential considerations to avoid misdiagnosis with other similar lesions and the surgical procedure for its excision and precautions should be taken.

Case History

A full-term five-day-old buffalo-calf, weighted 57 kg body weight (BW) was referred to the veterinary teaching hospital, department of surgery, anesthesiology, and radiology, faculty of veterinary medicine, Assiut University, Assiut, Egypt. The calf was born with a massive tumor-like lesion on its back. However, the owner confirmed normal suckling, standing, laying, and walking behavior of the calf. Also, the calf had no nervous manifestations since its birth when we asked the owner.

Clinical examination and differential considerations

Clinical examination of the calf revealed a dorsal thoracolumbar massive, but fluctuating mass on the back of the calf, along with its spine (Figure 1). The mass was covered by normal skin and revealed no pain on manipulation. For the first time, it was suspected to be a thoracic meningocele because of its location as well as the fluctuation. Under aseptic circumstances, exploratory puncture did not yield any aspirate. Ultrasonographic examination was not available at this time.

The body vital parameters (rectal temperature, heart rate, and respiratory rate) of the calf were within the normal (37.8°C, 73beats/min, and 17breaths/min, respectively). On neurological examination, the calf did not show any neurological deficit.

The absence of neurological deficit, as well as a cerebrospinal fluid (CSF) on aspiration, excluded that the case may be a meningocele. Also, the absence of any cystic aspirate in the syringe excluded that this mass may be a cyst. In the same time, it was hard to suspect it to be a tumor because of its softness and fluctuation. Anyway, surgical intervention was decided for surgical excision of this mass.

Surgical intervention

The site of operation was prepared for aseptic surgery as usual (clipped, shaved, and disinfected with a povidone-iodine solution (Betadine, the Nile Co. for pharmaceutical and chemical industries, Egypt). The calf was premedicated by intramuscular (IM) 0.05mg/kg BW of 2% xylazine hydrochloride (Xyla-Ject, ADWIA Co., SAE, Egypt). Circular local infiltration anesthesia was achieved around the mass using 0.05% lidocaine hydrochloride (Dibucaine, Sigma-Tec



Figure 1: A congenital massive dorsal thoracolumbar teratoma in a buffalo-calf.

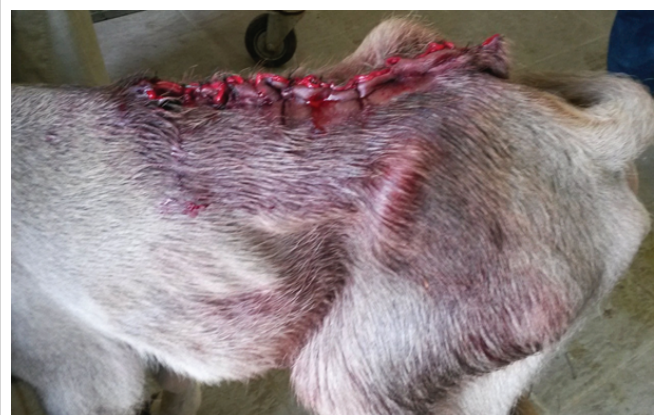

Figure 2: The buffalo-calf after surgical excision of the massive dorsal thoracolumbar teratoma.

Pharmaceutical Industry Co., Egypt). The calf was positioned on the lateral recumbency on the operation table. An elliptical incision was made around the mass through the skin and subcutaneous layers. A process of sharp and blunt dissection was started from the most upper border of the mass. The mass was highly vascularized. Hemostasis was achieved using a combination of direct pressure with sterile gauze sponges and bipolar electrocautery. However, ligations were applied to large blood vessels when needed, especially on dissection of the mass from the underlying thoracolumbar muscles using synthetic absorbable suture no 5-0. The mass was excised totally from the back of the calf. The site of operation was checked for any hemorrhages. The removal of the mass revealed intact underneath thoracolumbar muscles. The defect was closed on two layers; the subcutaneous layer using synthetic absorbable suture no 0 in a simple continuous fashion and the skin layer using silk no 1 in an interrupted horizontal lambert manner (Figure 2). Post-operatively, the calf was administered 2ml Norcilline L.A. (procaine penicillin G 150mg/ml and benzathine penicillin G 112.5mg/ml, Norbrook), IM, once daily for five consecutive days and 3ml Finadyne (flunixin, 50mg/ml, MSD, Animal Health), IM, once.

Growth pathological examination of the excised mass revealed a presumed teratoma. The tumor was cystic with solid areas. Our diagnosis was supported by the presence of multiple areas of hair in the tissue (Figure 3).

Discussion

Interestingly, no reports have been recorded dorsal thoracolumbar teratoma in buffalo calves. The current case study described the clinical findings of a massive dorsal thoracolumbar presumed teratoma in a full-term buffalo calf and the differential considerations from other similar lesions that may be misdiagnosed with it. More than that, it provided the surgical procedure for reliable surgical excision of such presumed teratoma and precautions should be taken during that.

Congenital tumors in calves, although rare, are of potential importance. Such lesion when found in a full-term calf, it may cause severe dystocia and threatens the dam's life [3,11,12]. In human beings, cesarean sections may be employed in such cases [13,14].

The etiology and pathogenesis of most congenital tumors are obscure. Little is known about the pathogenetic pathways of tumors in calves. Modern methods of analyzing chromosomal and gene aberrations may be helpful in clarifying the pathogenesis of congenital tumors [15]. Heredity, environment, carcinogenic drugs and poisons, infectious agents and immune disorders may be possible etiological

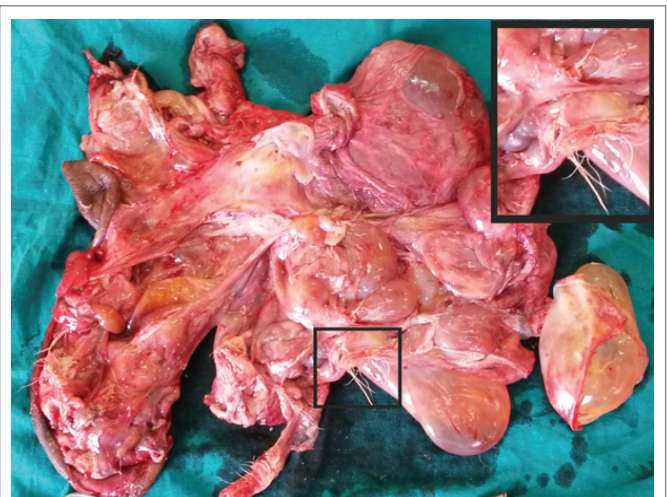


Figure 3: The teratoma after the surgical excision: note the solid, cystic, and hair areas.

factors for the development of neoplasms [5,16]. Mahour [3] put various theories for the origin of teratomas. These include the development of germ cells within the gonads (parthenogenetic origin) or in extragonadal sites (nonparthenogenetic origin) from wandering germ cells left behind during the migration of embryonic germ cells from the yolk sac to the gonad. Another one includes origin from other totipotent embryonic cells that escaped organizer influence during development.

Sometimes, teratoma is not quite clear and may be confused with other lesions especially spina bifida cystica. Teratoma was misdiagnosed with sacral abscess and pilonidal cystin a neonate child before a definite diagnosis was made. However, in obscure cases, ultrasonography, computerized tomography (CT) or myelography may be helpful [3].

Meningocystocele is a congenital condition associated with neural tube closing disorder. It is characterized by a herniated dural sac filled with the cerebrospinal fluid (CSF). The meningocele is covered with normal skin. It is most frequently found in the lumbosacral region [17,18]. In the current case, because of the absence of CSF on aspiration, the lesion was excluded to be a meningocele, in spite of having the typical features of the consistency and location of the meningocele.

The presumed teratoma in the present case was covered by normal skin. Macroscopically, it contained hair (tissue foreign to the anatomical site). Also, it showed solid and cystic areas. This was in accordance with the findings of Mahour [3]. Although the microscopical features of the teratomas have been well established in many literatures [3,4,19], the microscopical examination not conducted in the current case is a drawback. According to the results of the present study, surgical excision of the presumed teratoma was a reliable and satisfactory treatment without any intra-operative or post-operative complications [3].

Conclusion

Diagnosis of dorsal thoracic teratoma may be difficult and could be confused with other lesions especially the meningocele. Ultrasonography, computerized tomography (CT), or myelography could be helpful for definite diagnosis. Surgical excision is a reliable treatment for such cases.

Conflict of Interest

The authors declare that they have no conflict of interest.

References

- Misdorp W (2002) Congenital tumours and tumour-like lesions in domestic animals. 1. Cattle. A review. *Vet Q* 24: 1-11.
- Willis RA (1967) *Pathology of Tumours*, 4th edition. Appleton, London, 117-118.
- Mahour GH (1988) Sacrococcygeal teratoma. *CA: A Cancer journal for clinicians* 38 : 362-367.
- Pande M, Das GK, Singh R, Ramteke SS, Khan FA, et al. (2016) Ovarian teratoma in a water buffalo (*Bubalus bubalis*). *Buffalo Bulletin* 35: 557-562.
- Yeruham I, Perl S, and Orgad U (1999) Congenital skin neoplasia in cattle. *Vet Dermatol* 10: 149-156.
- Ozmen O (2005) Clinical case: Congenital lipomatosis in a Brown Swiss calf. *Revue Méd.Vét* 156: 191-193.
- Misdorp W (2003) Congenital tumours and tumour-like lesions in domestic animals. 3. Horses. A review. *Vet Q* 25: 61-71.
- Rota A, Tursi M, Zabarino S, Appino S (2013) Monophasic teratoma of the ovarian remnant in a bitch. *Reprod Domest Anim* 48: e26-e28.
- Misdorp W (2003) Congenital and hereditary tumours in domestic animals. 2. pigs. A review. *Vet Q* 25: 17-30.
- Harland S, Smith C, Mogg T, Horadagoda N, Dart A (2009) Surgical resection of a dysgerminoma in a mare. *Aust Vet J* 87: 110-112.
- Kumar DD, Muralikrishna BV, Ramakrishna V (1997) Dystocia due to foetal lipomatosis in a she buffalo. *Indian Vet J* 74: 687-688.
- Goldscmidt MJ, Hendrick MJ (2002) Tumors of the skin and soft tissues. In: Meuten DJ (Ed) *Tumors in Domestic Animals*. 4th Edition, John Wiley & Sons.
- Donnelly WJC (1975) Fibro chondrolipoma in a full-term bovine foetus delivered by caesarean section. *Vet Rec* 23: 150.
- Graf JL, Albanese CT (2003) Fetal sacrococcygeal teratoma. *World J Surg* 27: 84-86.
- Misdorp W (2002) Tumours in calves: comparative aspects. *J Comp Pathol* 127: 96-105.
- Albarella S, Ciotola F, D'Anza E, Coletta A, Zicarelli L, et al. (2017) Congenital Malformations in River Buffalo (*Bubalus bubalis*). *Animals (Basel)* 7: E9.
- Erşahin Y, Barçin E, Mutluer S (2001) Is meningocele really an isolated lesion? *Childs Nerv Syst* 17: 487-490.
- Arts MP, de Jong TH (2004) Thoracic meningocele, meningomyelocele or myelocystocele? Diagnostic difficulties, consequent implications and treatment. *Pediatr Neurosurg* 40: 75-79.
- Wetherell D, Weerakoon M, Williams D, Beharry BK, Sliwinski A, et al. (2014) Mature and Immature Teratoma: A Review of Pathological Characteristics and Treatment Options. *Med Surg Urol* 3: 124.